

Title: In Vitro Visual and Visible Light Transillumination Methods for Detection of Natural Non-cavitated Approximal Caries

Authors: N. Abogazalah^{a,b}, G.J. Eckert^c, M. Ando^{a*}

^a Department of Cariology, Operative Dentistry and Dental Public Health, Indiana University School of Dentistry, Indianapolis, IN, USA; ^b Department of Restorative Dental Sciences, King Khalid University College of Dentistry, Abha, Saudi Arabia; ^c Department of Biostatistics, Indiana University School of Medicine, Indianapolis, IN, USA.

***Corresponding Author:**

Dr. Masatoshi Ando

Department of Cariology, Operative Dentistry and Dental Public Health,
Indiana University School of Dentistry.

415 Lansing Street, Indianapolis, IN 46202 USA.

Tel: +1-317-274-8822

Fax: +1-317-274-5425

E-mail: mando@iu.edu

Acknowledgement

The authors thank Drs. Anderson Hara and Ana Gossweiler, Indiana University School of Dentistry (IUSD), to participate in this study as examiners. We thank Dr. James C Williams, Department of Anatomy and Cell Biology, Indiana University School of Medicine for the assistance with Skyscan microfocus computed tomography. This study

was conducted in Indiana University School of Dentistry, USA. This work was supported by Indiana University School of Dentistry, Department of Cariology, Operative Dentistry and Dental Public Health, 2016; and by Dental Master's Thesis Award Program from Delta Dental Foundation (Okemos, MI, 2016). The funders had no role in study design, data collection and analysis, decision to publish, or preparation of the manuscript. The roles of authors were: conceived and designed the experiment: N. Abogazalah, G.J. Eckert; and M. Ando; Performed examinations: N. Abogazalah and M. Ando; Perform statistical analyses: G.J. Eckert; and Wrote the paper: N. Abogazalah, G.J. Eckert; and M. Ando.

Abstract

Objectives: The objective was to evaluate a visible-light-transillumination (using Digital Imaging Fiber-Optic Transillumination machine: DIFOTI) method using occlusal view (DIFOTI-occl), axial view (buccal and lingual: DIFOTI-axial), and combination of all views (DIFOTI-all) for detecting non-cavitated approximal caries and to compare its performance to visual-examination (International Caries Detection and Assessment System: ICDAS).

Materials and Methods: Thirty extracted human-premolars were selected (sound to lesions into the outer one-third of the dentine) based on micro-computed tomography (μ -CT). Teeth were mounted in a custom-made device to simulate approximal contact. DIFOTI (Electro-Optical Sciences Inc, Irvington, NY, USA) images were obtained from the occlusal, buccal and lingual views. DIFOTI image and ICDAS examinations were performed and repeated by three trained/calibrated examiners. Sensitivity, specificity, area under Receiver-Operating-Characteristics curve (A_z), inter- and intra-class correlation coefficients (ICCs), and correlation were determined.

Results: Sensitivity/specificity were for DIFOTI-occl: 0.42/0.75, DIFOTI-axial: 0.86/0.93 DIFOTI-all: 0.91/0.69 and for ICDAS: 0.89/0.83. A_z for DIFOTI-occl was significantly lower than that of DIFOTI-axial ($p < 0.001$), DIFOTI-all ($p = 0.002$) and ICDAS ($p = 0.005$). Spearman correlation coefficients with μ -CT for DIFOTI-occl ($r = 0.39$) showed weak association, while DIFOTI-axial ($r = 0.80$), DIFOTI-all ($r = 0.91$) and ICDAS ($r = 0.90$) showed moderate association. ICCs for intra-examiner repeatability/inter-examiner agreement were for DIFOTI-occl (0.64/0.58), DIFOTI-axial (0.92/0.89), DIFOTI-all (0.85/0.83), and ICDAS (0.79/0.72).

Conclusions: The results of the current *in vitro* study suggest that, for detection of non-cavitated approximal caries lesions DIFOTI performs better using axial than occlusal view.

Clinical Relevance: Approximal non-cavitated caries detection is challenging. DIFOTI can observe images from occlusal-, buccal- and lingual-views. DIFOTI and visual (ICDAS) examinations of buccal- and lingual-, and all-views are more suitable than those of occlusal-view for a detection of non-cavitated approximal caries.

Key words:

Approximal Caries, Caries Detection, Visible Light Transillumination, International Caries Detection and Assessment System (ICDAS), Non-cavitated caries lesion, Imaging geometry, Digital Imaging Transillumination, DIFOTI.

1. Introduction

Dental caries remains a worldwide major health problem for children and adults [1]. Teeth surfaces are active sites of demineralization and remineralization that occurs over time. The net balance between the pathologic and protective factors will determine the rate of lesion progression to a state that can be clinically detected [2]. Early caries detection, which is a challenging task, is important in order to arrest or remineralize non-cavitated caries lesions before irreversible destruction of the tooth structure occurs [3].

Visual caries examination is the most frequently used method for caries detection in daily dental practice, because it is an expedient technique with no additional cost to the dentist and the patient. An effort has been made to develop and validate visual caries detection systems such as the International Caries Detection and Assessment System (ICDAS) [4]. ICDAS records dental caries severity using an ordinal scale from 0 to 6 in an attempt to correlate the clinical appearance of the teeth to their histological status [4-6].

Approximal caries lesions can be observed visually from the occlusal view, especially caries lesions that reach to the dentin-enamel junction (DEJ) or beyond [7]. However, early caries lesions, such as non-cavitated enamel lesions, may not be detected with unaided eyes. With technology-based caries detection techniques, such as visible light transillumination, e.g. Digital Imaging Fiber Optic Transillumination (DIFOTI), and near-infrared transillumination techniques, e.g. DIAGNOcam/CariVu, the detection of non-cavitated lesions could be improved as compared to visual examination with unaided eyes.

The principle of the visible light transillumination method is that areas of disrupted enamel crystals that occur in demineralized tooth tissues appear as dark shadows when transilluminated. This is due to changes in the light scattering and absorption of light

photons [8]. An example of visible light transillumination that comes in digital format is the DIFOTI machine. It uses a visible light source (wavelength between 450 nm to 700 nm) and a charge coupled device (CCD) camera for digital acquisition of images. DIFOTI can provide a real time image for occlusal or axial (buccal and lingual) surfaces. The DIFOTI occlusal mouthpiece is used to shine the light parallel to the CCD camera to obtain occlusal images, while for axial images, the approximal mouthpiece is used to shine the light perpendicular to the CCD camera [9]. DIFOTI is the only commercially available visible light transillumination detection device that can obtain images from occlusal and axial views using two different mouthpieces. Current commercially available near-infrared transillumination devices use only the occlusal view to detect approximal caries [10].

To authors' best knowledge, there is no available information to demonstrate which view is more suitable to detect approximal caries using light transillumination methods based on a well-established gold standard such as histology or microfocus computed tomography (μ -CT). Therefore, the objective of this study was to evaluate and compare the performance among DIFOTI of occlusal view (DIFOTI-occl), buccal and lingual (DIFOTI-axial), a combination of all views (DIFOTI-all) and visual examination using International Caries Detection and Assessment System (ICDAS) regarding the detection of non-cavitated approximal caries. The hypotheses of this study were that validity and reliability of DIFOTI-all will be higher than DIFOTI-occl, DIFOTI-axial and ICDAS; and DIFOTI-axial can detect more approximal non-cavitated caries than DIFOTI-occl.

2. Materials and methods

2.1 Teeth selection and model assembling

Sound as well as carious premolars that have approximal non-cavitated caries lesions surrounded by sound enamel were selected from a pool of extracted teeth. The presence of caries was determined by visual tooth surface changes [4]. The extracted human teeth were collected from dental practitioners in the State of Indiana and transported in 0.1% thymol solution. The collection of human teeth for use in dental laboratory research studies has been approved by the Indiana University Institutional Review Board. All specimens were kept in 0.1% thymol solution at 4° C until use. Teeth were cleaned using Robinson's brush with water. Thirty human extracted premolars were selected based on microfocus computed tomography (μ -CT). The μ -CT images were acquired using (Skyscan 1172, Kontich, Belgium) at 80 kV, 134 μ e, 8.9 μ m pixel size resolution. An Al + Cu filter was used. The specimens were rotated at 180° with rotation step of 0.7° and frame average of 4. Two-dimensional image reconstruction was done using NRecon version 1.6.6 software (Bruker microCT, Kontich, Belgium). The reconstructed images were stored in 16-bit TIFF files. Visual interpretation of the axial view of the μ -CT images was performed using image display software (CT-Analyser, Bruker microCT, Kontich, Belgium). The images were evaluated by two experienced examiners (NA and MA) according to the criteria previously prescribed [11] using the scale of E₀ to D₂ (Table1). The image with the deepest lesion extension was considered for score determination. In case of disagreement, the examination was performed again until consensus agreement was achieved. Carious teeth with lesion extension into the inner two-thirds of dentin (D₂) were excluded. Also, cracked teeth and teeth with obvious fluorosis were excluded. The final distribution of the thirty study teeth was as follows: sound surface (n=12), lesion in the outer half of the enamel (n=6), lesion in the inner half of the enamel but not extending beyond the DEJ

(n=6), and lesions in the outer one third of the dentin (n=6). The apical one-third of the root was reduced, leaving the coronal two-thirds, using diamond discs (Lapcraft's L'il Trimmer™, Powell, Ohio, USA). The teeth were mounted on Lego bricks with the test surface adjacent to a sound tooth. Triad® visible light cure resin (DENTSPLY International, Inc., York, USA) was applied around the root and the cervical part of the teeth at the level of the cemento-enamel junction to resemble the thickness and anatomy of the gingiva. Dental floss was used to confirm the presence of the proximal contact. The assembled models were kept in a container with wet gauze to maintain humidity.

2.2. DIFOTI image acquisition

An examiner (NA) experienced with the DIFOTI method obtained the images under standard conditions using a commercially available DIFOTI machine (Electro-Optical Sciences Inc, Irvington, NY, USA). The examiner did not participate in DIFOTI and ICDAS examinations. DIFOTI images were obtained for 30 specimens that were intended to be used for the main evaluation and an additional 12 specimens to be used for training and calibration. The DIFOTI instrument was used to transilluminate the teeth to acquire the images and display them on the monitor. The images were obtained after air-drying in a dark room using two types of mouthpieces. The occlusal mouthpiece was used to transilluminate the tooth with a visible white light in a direction parallel to the CCD camera to obtain occlusal image views (DIFOTI-occl) (Figure1). The approximal mouthpiece was used to transilluminate the tooth in a direction perpendicular to the CCD sensor to obtain axial (buccal and lingual) image views (DIFOTI-axial). A dedicated DIFOTI program

(Difoti version 2, Electro-Optical Sciences Inc., Irvington, NY, USA) was used to save and display the images.

2.3. Training and calibration

Three examiners (MA, AG, AH) were trained and calibrated more than 2 weeks after μ -CT examination on DIFOTI and ICDAS prior to the main examination. The training course included theoretical elements and hands-on training on previously obtained DIFOTI images and specimens for ICDAS of extracted premolars. Twelve sets of teeth (not included in the main examination) with confirmed lesion depths based on μ -CT images were used for calibration. The distribution was as follows: sound surface (n=3), lesion in the outer half of the enamel (n=3), lesion in the inner half of the enamel but not extending beyond the DEJ (n=3), and lesions in the outer one third of the dentin (n=3). For the calibration, the primary and repeated examinations were performed during separate sessions. NA examiner randomly ordered the samples between examiners and before each examination for each method using the random function of Microsoft Excel software (Microsoft® Excel® version 14.6.0, Microsoft Corporation, Redmond, WA, USA).

2.3.1. ICDAS Calibration

The samples were placed on a tabletop just above knee level of the examiners. The examiners were instructed to sit in an upright position and to have no direct access to the approximal surfaces. The ICDAS examination was performed under a dental light unit, using dental explorer and air-water syringe. Each specimen was removed from a container with 100 % humidity, examined, air dried up to 5 seconds and examined again. The

examiners used a mouth mirror to examine from the buccal and the lingual sides. The test approximal surface of each specimen was examined and since only non-cavitated lesions were included, the highest score from 0 to 4 was recorded according to ICDAS (Table 2) [4].

2.3.2. DIFOTI Calibration

Each examiner performed the evaluation in a dark room during a separate session. The images were displayed randomly on a digital screen via dedicated DIFOTI program (Electro-Optical Sciences Inc., Irvington, NY, USA) by the trainer (NA). The occlusal image was viewed and scored first for presence of approximal caries, followed by buccal and lingual image views. Each approximal surface was scored for presence of shadowing as a caries lesion according to previously described criteria as shown in Table 3 [12,13].

2.3.3. Repeated Calibration

Each examiner performed ICDAS and DIFOTI calibration again at least two days after the initial calibration and in the same manner as previously described in “2.3.1. ICDAS Calibration” and “2.3.2. DIFOTI Calibration”

2.4. Statistical Analysis and Results for Calibration

Intra-examiner repeatability and inter-examiner agreement of all methods were assessed using intraclass correlation coefficients (ICCs).

The intra-examiner repeatability ICCs after calibration were as follows: DIFOTI-occl (0.53), DIFOTI-buccal (0.92), DIFOTI-lingual (0.85) and ICDAS (0.58). The inter-

examiner agreement ICCs were as follows: DIFOTI-occl (0.53), DIFOTI-buccal (0.92), DIFOTI-lingual (0.83) and ICDAS (0.58).

ICCs were not satisfactory for ICDAS or DIFOTI-occl. Therefore, a second training and calibration exercise was performed as previously described. The intra-examiner repeatability ICCs for the second calibration were as follows: DIFOTI-occl (0.87), DIFOTI-buccal (0.87), DIFOTI-lingual (0.83) and ICDAS (0.49), The inter-examiner agreement ICCs were as follows: DIFOTI-occl (0.87), DIFOTI-buccal (0.86), DIFOTI-lingual (0.83) and ICDAS (0.48).

2.5. Main examination

Using the mounted specimens described in “2.1 Teeth selection and model assembling” and DIFOTI images acquired in “2.2. DIFOTI image acquisition” (30 specimens), the main and repeat examinations were performed in the same manner as described in “2.3. Training and calibration” section. The repeat examination was performed one week after the main examination.

2.6. Statistical Analysis for Main Examination

DIFOTI images were assessed using three views - occlusal, buccal, and lingual. The maximum score among the three views (occlusal, buccal, and lingual) was used for the analyses labeled as DIFOTI-all. The maximum score of the buccal and lingual views was used for the analyses labeled as DIFOTI-axial; only the occlusal view was used for DIFOTI-occl. Intra-examiner repeatability and inter-examiner agreement were assessed

using intraclass correlation coefficients (ICCs). Comparisons between DIFOTI-occl, DIFOTI-axial, DIFOTI-all and ICDAS for sensitivity, specificity, and area under the Receiver Operating Characteristics (ROC) curves (A_z) were performed using bootstrap analyses. The sensitivity was determined further based on three μ -CT thresholds: lesion in the outer half of the enamel (E_1) lesion in the inner half of the enamel (E_2); and lesion in the outer one-third of the dentin (D_1). The correlations among the measurements and the correlations of the measurements with the μ -CT were also calculated using bootstrap methods.

Sample size justification: data from previous studies indicated a correlation of approximately 0.7 between methods. With a sample size of 12 sound teeth and 6 teeth for each of E_1 , E_2 , and D_1 , the study was designed to have 80% power to detect a difference in the area under the ROC curve of 0.23 (0.67 vs. 0.90), assuming a two-sided test with a 5% significance level.

3. Results

The intra-examiner repeatability, inter-examiner agreement, overall sensitivity, specificity, sensitivity at different thresholds, area under the ROC curve (A_z) and correlation with μ -CT are presented in Table 4. Figure 2 illustrates ROC curves to provide a visual comparison between the methods at sensitivity-specificity tradeoffs.

Overall sensitivity was significantly lower for DIFOTI-occl than for DIFOTI-axial ($p=0.002$), DIFOTI-all ($p<0.001$), and ICDAS ($p=0.001$). Overall sensitivity was not significantly different between DIFOTI-occl, DIFOTI-axial, DIFOTI-all and ICDAS ($p=0.827$). The specificity was not significantly different between the views ($p=0.17$).

For μ -CT=E₁, sensitivity was significantly lower for DIFOTI-occl than for DIFOTI-axial (p=0.010), DIFOTI-all (p=0.001) and ICDAS (p<0.001). For μ -CT=E₂, DIFOTI-occl was significantly lower than DIFOTI-all. No other significant differences in sensitivity for μ -CT= E₂ were found among the methods (p>0.06). For μ -CT=D₁, there were no significant differences in sensitivity values among the methods (p>0.16).

A_z was significantly lower for DIFOTI-occl than for DIFOTI-axial, DIFOTI-all (p<0.001) and ICDAS (p=0.001). DIFOTI-axial, DIFOTI-all and ICDAS were moderately associated with μ -CT but DIFOTI-occl was weakly associated with μ -CT.

4. Discussion

The performance of DIFOTI-axial and DIFOTI-all in this current study was in agreement with two previous *in vitro* studies regarding sensitivity and specificity, as well as the inter-examiner agreement and intra-examiner repeatability [14,9]. However, previous studies did not clearly mention whether the DIFOTI method was used to detect lesions from the occlusal or buccal and lingual views or a combination of all views. Our current study showed higher sensitivity and specificity values for axial view than occlusal view for detection of approximal non-cavitated lesions. A possible explanation is that wavelengths in the visible range (wavelength: 400 nm to 700 nm) are limited by strong light scattering by the tooth tissues, making it difficult to image through 1 to 2 mm thickness of tooth structure [15]. Non-cavitated approximal caries lesion shape is based on the distribution of dental plaque between the contact point and gingival margin. This leaves a thickness of sound enamel extending from the marginal ridge occlusally to the contact point and may range from 1 to 3 mm for premolars [16]. In the occlusal view, the visibility

of the early approximal lesion can be obscured by the presence of a sound marginal ridge, as the light needs to travel through a large amount of sound enamel. On the other hand, in the approximal view, the non-cavitated approximal caries lesion can be visualized directly due to surface caries changes. The results of this study illustrate that axial views are more valid and reliable than occlusal-views for non-cavitated approximal caries detection and the use of combined occlusal and axial views may aid in detecting more lesions but with increasing risk of false positive detection.

Near infrared light transillumination (NILT) device has been developed for caries detection to overcome the limitation of stronger light scattering in DIFOTI. It was found that tooth enamel is almost transparent when transilluminated with light in near infrared (NIR) wavelength range [17]. A commercially available version of NILT at 780 nm can only detect approximal lesions from the occlusal view. The performance of this device was evaluated in an *in vivo* study for detection of dentin involved lesions and showed performance comparable to radiography [10]. Another *in vivo* study found that NILT was able to detect more enamel lesions than radiography with higher repeatability and agreement values among examiners [18]. Furthermore, the performance of NILT was also evaluated in an *in vitro* study that evaluated validity and reliability of the device [19].

When compared to DIFOTI-axial and DIFOTI-all, NILT reported lower sensitivity (0.68) and relatively similar specificity (0.93). However, NILT reported higher sensitivity and specificity than DIFOTI-occl. Moreover, performance of a prototype device that uses near-infrared light at 1,310 nm was evaluated for detection of approximal caries lesions with radiography as a gold standard [20]. They used occlusal, buccal and lingual views to evaluate approximal sites. Using buccal and lingual views resulted in detecting thirty

approximal lesions out of thirty three lesions while the occlusal view detected twenty-seven lesions [20]. This is in agreement with our results as it can be explained as the emitted light in NILT needed to travel through a large amount of surrounding enamel in order to reach the occlusal surface.

The performance of ICDAS was in agreement with previous *in vitro* studies that used histology as a gold standard [21,22]. Although repeatability and agreement during calibration were not high, repeatability and agreement during the main examinations on test specimens were high. This may be because of the lower sample size included in the calibration process or it can be attributed to the examiners' experience. It has been shown that the correct use of ICDAS and the examiner's experience may improve the precision of visual examination [23,4].

Extrapolation of the results of this current *in vitro* study should be considered very carefully. The main concern that may impact clinical implication is the difficulty in simulating clinical approximal contacts. Although all examined approximal sites were in contact with adjacent teeth, the *in vitro* assembling of the specimens may have produced smaller than "normal" contact points, leaving significant portions of the approximal surfaces visually accessible. *In vitro* studies, including this current study, that evaluated ICDAS performance for early approximal caries detection [22,21] showed significantly higher sensitivity values than typically reported in *in vivo* studies [24-26]. Further concern is that the DIFOTI image acquisition and ICDAS examinations were carried out under well-controlled laboratory conditions. Presence of good access and absence of saliva, tongue, gingiva and stains may improve the performance of any caries detection method under *in vitro* environment. Further limitation of the current study is the relatively low

sample size. However, being able to identify caries lesions and their extension based on non-destructive gold standard prior to the examination allowed for an acceptable power (80%) for the sample size calculation.

In this current study, DIFOTI demonstrated that lesions involving the inner half of the enamel were more detectable than lesions in the outer half. This is in agreement with Ando's [13] observations regarding occlusal and smooth surface caries detection *in vivo* using DIFOTI. A possible explanation is that increased demineralization may lead to increased light scattering and absorption [27]. This indicates the potential of light transillumination methods to quantify caries lesion [27].

The main disadvantage of DIFOTI is that it cannot differentiate between caries lesions and stains or developmental defects such as fluorosis. Therefore, additional visual examination is recommended to improve the detection of dental caries. Another concern regarding DIFOTI is that it cannot define the lesion depth extension and dental pulp because of the strong light scattering of the dentin. Consequently, it is difficult to estimate the lesion depth as it only detects surface changes. Therefore, bitewing radiographs may aid to estimate lesion depth extension. Further study is needed to identify possible quantitative or qualitative indicators that can be used to determine or estimate dentin lesion.

5. Conclusion

Within the limitations of this *in vitro* study, DIFOTI-axial was able to perform better than DIFOTI-occl regarding detection on non-cavitated approximal caries. Also, no difference was found in the performance of ICDAS, DIFOTI-all and DIFOTI-axial for non-

cavitated approximal caries detection. Development of future light transillumination devices may consider developing axial view images for approximal caries detection.

Compliance with Ethical Standards

Conflict of Interest: The authors declare that they have no conflict of interest.

Funding: The work was supported by the Dental Master's Thesis Award Program from Delta Dental Foundation.

Ethical approval: This article does not contain any studies with human participants or animals performed by any of the authors.

Informed consent: For this type of study, formal consent is not required.

References

1. Kassebaum NJ, Smith AGC, Bernabe E, Fleming TD, Reynolds AE, Vos T, Murray CJL, Marcenes W, Collaborators GBDODH (2017) Global, Regional, and National Prevalence, Incidence, and Disability-Adjusted Life Years for Oral Conditions for 195 Countries, 1990-2015: A Systematic Analysis for the Global Burden of Diseases, Injuries, and Risk Factors. *J Dent Res* 96 (4):380-387.
doi:10.1177/0022034517693566
2. Pitts NB, Zero DT, Marsh PD, Ekstrand K, Weintraub JA, Ramos-Gomez F, Tagami J, Twetman S, Tsakos G, Ismail A (2017) Dental caries. *Nat Rev Dis Primers* 3:17030.
doi:10.1038/nrdp.2017.30
3. Zero DT, Fontana M, Martinez-Mier EA, Ferreira-Zandona A, Ando M, Gonzalez-Cabezas C, Bayne S (2009) The biology, prevention, diagnosis and treatment of dental caries: scientific advances in the United States. *J Am Dent Assoc* 140 Suppl 1:25S-34S
4. Ismail AI, Sohn W, Tellez M, Amaya A, Sen A, Hasson H, Pitts NB (2007) The International Caries Detection and Assessment System (ICDAS): an integrated system for measuring dental caries. *Community Dent Oral Epidemiol* 35 (3):170-178. doi:10.1111/j.1600-0528.2007.00347.x
5. Ekstrand KR, Kuzmina I, Bjorndal L, Thylstrup A (1995) Relationship between external and histologic features of progressive stages of caries in the occlusal fossa. *Caries research* 29 (4):243-250
6. Ismail A (2004) Diagnostic levels in dental public health planning. *Caries research* 38 (3):199-203. doi:10.1159/000077755
7. Bin-Shuwaish M, Yaman P, Dennison J, Neiva G (2008) The correlation of DIFOTI to clinical and radiographic images in Class II carious lesions. *J Am Dent Assoc* 139 (10):1374-1381
8. Friedman J, Marcus MI (1970) Transillumination of the oral cavity with use of fiber optics. *Journal of the American Dental Association* 80 (4):801-809
9. Schneiderman A, Elbaum M, Shultz T, Keem S, Greenebaum M, Driller J (1997) Assessment of dental caries with Digital Imaging Fiber-Optic Transillumination (DIFOTI): in vitro study. *Caries Res* 31 (2):103-110
10. Kuhnisch J, Sochtig F, Pitchika V, Laubender R, Neuhaus KW, Lussi A, Hickel R (2016) In vivo validation of near-infrared light transillumination for interproximal dentin caries detection. *Clin Oral Investig* 20 (4):821-829. doi:10.1007/s00784-015-1559-4
11. Ekstrand KR, Ricketts DN, Kidd EA (1997) Reproducibility and accuracy of three methods for assessment of demineralization depth of the occlusal surface: an in vitro examination. *Caries Res* 31 (3):224-231
12. Wenzel A, Borg E, Hintze H, Grondahl HG (1995) Accuracy of caries diagnosis in digital images from charge-coupled device and storage phosphor systems: an in vitro study. *Dento maxillo facial radiology* 24 (4):250-254.
doi:10.1038/dmfr.24.4.9161170
13. Ando M Performance of Digital Imaging Fiber-optic Transillumination (DIFOTI) for Detection of Non-cavitated Primary Caries. Preliminary Report. In: Stookey G, Kambara M (eds) 83rd International Association for Dental Research Symposium :

Early Detection of Dental Caries, Baltimore, Maryland, March, 11 2005. Therametric Technologies Inc., Indianapolis, Indiana, pp 41-52

14. Astvaldsdottir A, Ahlund K, Holbrook WP, de Verdier B, Tranaeus S (2012) Approximal Caries Detection by DIFOTI: In Vitro Comparison of Diagnostic Accuracy/Efficacy with Film and Digital Radiography. *Int J Dent* 2012:326401. doi:10.1155/2012/326401
15. Darling CL, Fried D (2008) Real-time near IR (1310 nm) imaging of CO2 laser ablation of enamel. *Opt Express* 16 (4):2685-2693
16. Takei HH (1980) The interdental space. *Dent Clin North Am* 24 (2):169-176
17. Fried D, Featherstone JD, Darling CL, Jones RS, Ngaotheppitak P, Buhler CM (2005) Early caries imaging and monitoring with near-infrared light. *Dent Clin North Am* 49 (4):771-793, vi. doi:10.1016/j.cden.2005.05.008
18. Lara-Capi C, Cagetti MG, Lingstrom P, Lai G, Cocco F, Simark-Mattsson C, Campus G (2017) Digital transillumination in caries detection versus radiographic and clinical methods: an in-vivo study. *Dentomaxillofac Radiol* 46 (4):20160417. doi:10.1259/dmfr.20160417
19. Abogazalah N, Eckert GJ, Ando M (2017) In vitro performance of near infrared light transillumination at 780-nm and digital radiography for detection of non-cavitated approximal caries. *J Dent* 63:44-50. doi:10.1016/j.jdent.2017.05.018
20. Staninec M, Lee C, Darling CL, Fried D (2010) In vivo near-IR imaging of approximal dental decay at 1,310 nm. *Lasers Surg Med* 42 (4):292-298. doi:10.1002/lsm.20913
21. Braga MM, Morais CC, Nakama RC, Leamari VM, Siqueira WL, Mendes FM (2009) In vitro performance of methods of approximal caries detection in primary molars. *Oral Surg Oral Med Oral Pathol Oral Radiol Endod* 108 (4):e35-41. doi:10.1016/j.tripleo.2009.05.017
22. Mitropoulos P, Rahiotis C, Stamatakis H, Kakaboura A (2010) Diagnostic performance of the visual caries classification system ICDAS II versus radiography and micro-computed tomography for proximal caries detection: an in vitro study. *J Dent* 38 (11):859-867. doi:10.1016/j.jdent.2010.07.005
23. Shoaib L, Deery C, Ricketts DN, Nugent ZJ (2009) Validity and reproducibility of ICDAS II in primary teeth. *Caries Res* 43 (6):442-448. doi:10.1159/000258551
24. Gimenez T, Piovesan C, Braga MM, Raggio DP, Deery C, Ricketts DN, Ekstrand KR, Mendes FM (2015) Visual Inspection for Caries Detection: A Systematic Review and Meta-analysis. *J Dent Res* 94 (7):895-904. doi:10.1177/0022034515586763
25. Novaes TF, Matos R, Raggio DP, Imparato JC, Braga MM, Mendes FM (2010) Influence of the discomfort reported by children on the performance of approximal caries detection methods. *Caries Res* 44 (5):465-471. doi:10.1159/000320266
26. Novaes TF, Matos R, Braga MM, Imparato JC, Raggio DP, Mendes FM (2009) Performance of a pen-type laser fluorescence device and conventional methods in detecting approximal caries lesions in primary teeth--in vivo study. *Caries Res* 43 (1):36-42. doi:10.1159/000189705
27. Jjt B Light Scattering and Related Methods in Caries Diagnosis. In: GK S (ed) *The First Annual Indiana Conference Indiana University School of Dentistry, Indiana University School of Dentistry, Indianapolis, IN, USA, 1996.*

Figure 1. Digital Imaging Fiber-Optic Transillumination (DIFOTI) images acquisition.

The blue circles indicate the examined sites.







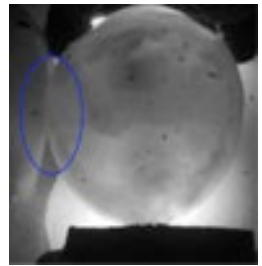


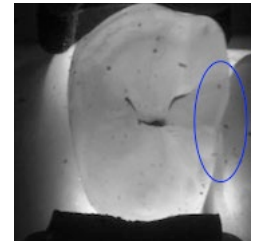
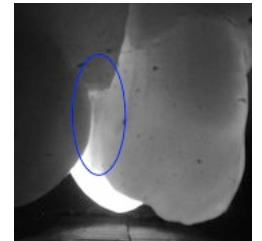
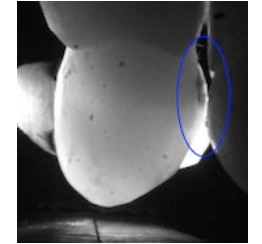
	Occlusal	Axial	
	DIFOTI Occlusal View	DIFOTI Buccal View	DIFOTI Lingual View
			
			
Sound approximal surface			
Carious approximal surface			

Figure 2. Receiver Operating Characteristics (ROC) curves for all methods based on observations by 3 examiners.