




Correction to: Inflammatory breast cancer defined: proposed common diagnostic criteria to guide treatment and research

R. Jagsi¹ · G. Mason^{2,3} · B. A. Overmoyer⁴ · W. A. Woodward⁵ · S. Badve⁶ · R. J. Schneider⁷ · J. E. Lang⁸ · M. Alpaugh⁹ · K. P. Williams¹⁰ · D. Vaught¹¹ · A. Smith¹¹ · K. Smith¹¹ · K. D. Miller⁶  on behalf of Susan G. Komen-IBCRF IBC Collaborative in partnership with the Milburn Foundation

Published online: 8 February 2022
© Springer Science+Business Media, LLC, part of Springer Nature 2022

Correction to: Breast Cancer Research and Treatment
<https://doi.org/10.1007/s10549-021-06434-x>

In the original publication of the article, the Figure 1 was published incorrectly.

The corrected Fig. 1 is given in this correction.

The original article has been corrected.

The original article can be found online at <https://doi.org/10.1007/s10549-021-06434-x>.

✉ K. D. Miller
kathmill@iu.edu

- ¹ University of Michigan, Ann Arbor, MI, USA
- ² Inflammatory Breast Cancer Research Foundation, West Lafayette, IN, USA
- ³ Susan G. Komen Advocates in Science, Dallas, TX, USA
- ⁴ Dana Farber Cancer Institute, Boston, MA, USA
- ⁵ University of Texas MD Anderson Cancer Center, Houston, TX, USA
- ⁶ Indiana University Melvin and Bren Simon Comprehensive Cancer Center, 535 Barnhill Drive, RT 473, Indianapolis, IN 46202, USA
- ⁷ New York University School of Medicine, New York, NY, USA
- ⁸ Cleveland Clinic, Cleveland, OH, USA
- ⁹ Rowan University, Glassboro, NJ, USA
- ¹⁰ North Carolina Central University, Durham, NC, USA
- ¹¹ Susan G. Komen, Dallas, TX, USA




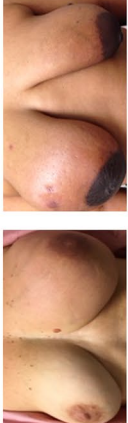

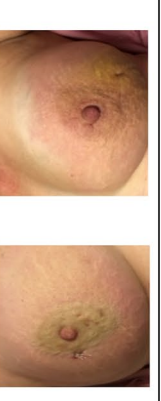
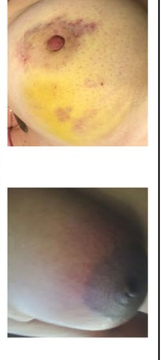




Characteristic	Score			Priority Factor (multiplier)
	3	2	1	
Timing of signs/symptoms	≤ 3 months	3-6 months	> 6 months	3
Skin changes	Any peau d'orange 	Skin edema/thickening over > 1/3 of the breast 	Focal skin edema/thickening < 1/3 of the breast 	3
Swelling or engorgement of the breast	Any clinically apparent enlargement; new asymmetry 	<i>Intentionally blank; patients receive either a score of 3 or 1 for this characteristic</i>	Breast edema identified on imaging but not clinically detectable 	3
Erythema or other skin discoloration: pink, red, darkened, bruising/purplish or serpiginous in character	Complete or near complete involvement of breast 	Not complete but greater than minimal involvement of the breast 	Minimal involvement or ambiguous color change 	2
Nipple abnormalities	New nipple inversions 	New nipple flattening or other asymmetry 	Crusting of the nipple/areola; no other changes 	2

Fig. 1 Clinical characteristics of inflammatory breast cancer

Publisher's Note Springer Nature remains neutral with regard to jurisdictional claims in published maps and institutional affiliations.