

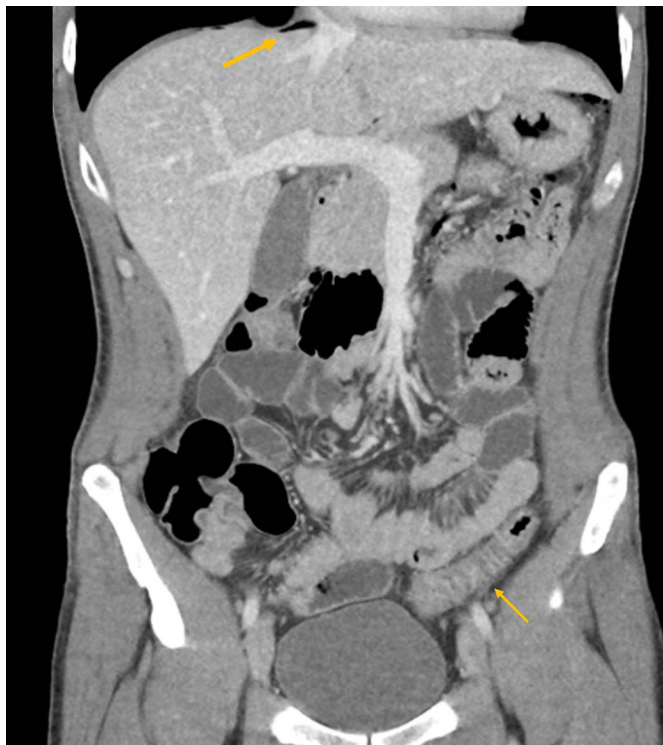IMAGE | COLON

# Sigmoid Colon Perforation Caused by an Unapparent Foreign Body

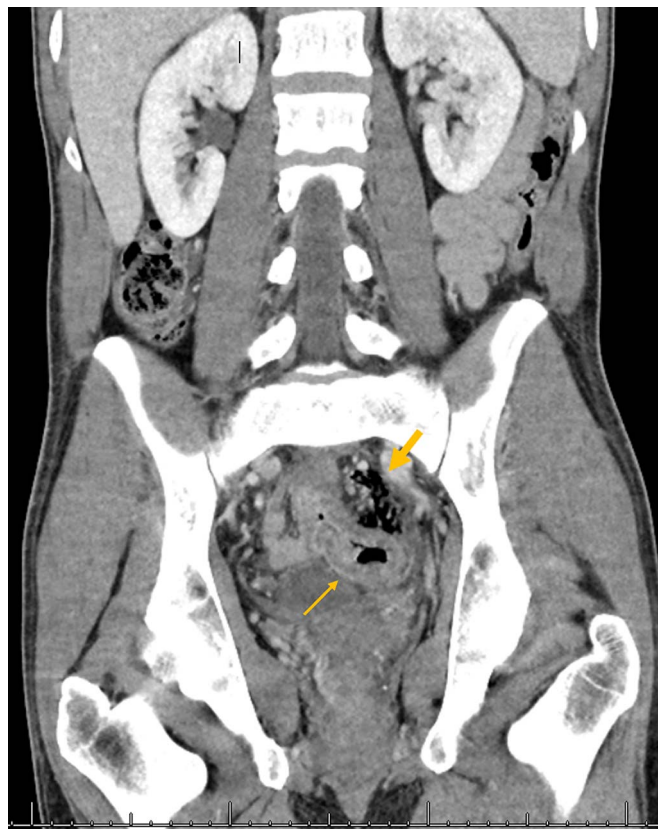
Antonios Wehbeh, MD<sup>1</sup>, and Christen Dilly, MD, MEHP<sup>1,2</sup><sup>1</sup>Division of Gastroenterology and Hepatology, Indiana University School of Medicine, Indianapolis, IN<sup>2</sup>Roudebush VA Medical Center, Indianapolis, IN

## CASE REPORT

A 39-year-old male veteran presented with 2 weeks of progressively worsening lower abdominal pain. He denied having fever or diarrhea before admission. On initial evaluation, his vital signs were normal. He was tender to palpation over the left lower quadrant and suprapubic areas but without any peritoneal signs. Laboratory test results were remarkable for a white blood cell count of 15,200/mm<sup>3</sup>, hemoglobin of 17 g/dL, and C-reactive protein of 13.5 mg/L. Fecal calprotectin level was elevated at 278 µg/g. A contrast-enhanced computed tomography (CT) scan revealed a diffusely edematous rectosigmoid colon and rectum and



**Figure 1.** A coronal image from the computed tomography scan of the abdomen and pelvis performed on initial admission showing free air (top arrow) and thickened rectosigmoid (bottom arrow).



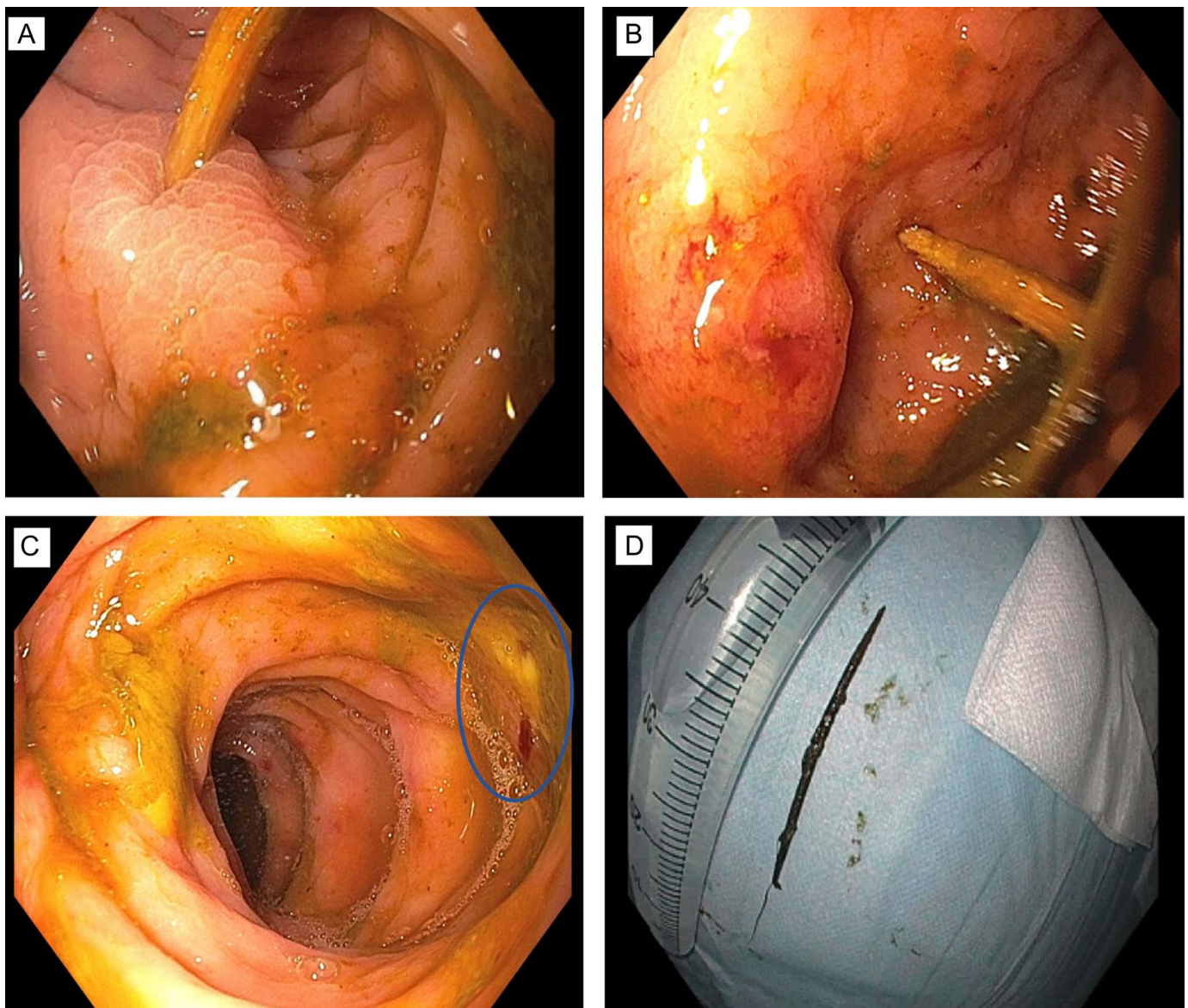
**Figure 2.** A coronal image from the computed tomography scan during the second admission showing persistently thickened rectosigmoid (bottom arrow) and adjacent to it there is extraluminal free air (top arrow).

small amounts of intra-abdominal free air (Figure 1). His pain improved after bowel rest and intravenous antibiotics, and he tolerated a low-residue diet. A presumptive diagnosis of Crohn's disease was made. Based on the patient's preference, he was discharged with oral antibiotics and plans for an outpatient colonoscopy.

The patient returned 4 weeks later with worsened abdominal pain, fever, and small amounts of red blood per rectum. Examination showed significant lower abdominal tenderness with voluntary guarding and mild rebound tenderness. Workup was negative for infectious etiology. A CT scan showed numerous foci of free air, most of which were adjacent to the persistently thickened rectosigmoid colon (Figure 2). A

flexible sigmoidoscopy showed a wooden toothpick lodged in both walls of the sigmoid colon, with otherwise normal mucosa (Figure 3). The toothpick was removed using a Raptor grasping device (US Endoscopy), and no overt perforation was seen. The patient significantly improved afterward, and he continued to feel well 2 months after discharge with no recurrence of symptoms.

Symptomatic ingestion of wooden toothpicks is a relatively rare clinical event.<sup>1</sup> Similar to most of those who ingest toothpicks, our patient did so accidentally and did not recall the event.<sup>2</sup> It most commonly occurs when eating food items that are held together by a toothpick, such as club sandwiches, frequently together with alcoholic beverages.<sup>2</sup>



**Figure 3.** Endoscopic images showing (A) one edge of the toothpick lodged in the colonic wall with surrounding reactive inflammation, (B) that same area (arrow) after manipulating the toothpick with a grasping forceps and freeing up the first edge, (C) ulcerated appearance of the opposite side of the colonic wall (circled) after completely removing the toothpick with no overt perforation, and (D) the removed toothpick placed next to a 50 mL syringe for size comparison.

The morbidity associated with clinically apparent toothpick ingestion is considerably high, with up to 79% chance of perforation and mortality rate between 9.6% and 18%.<sup>2,3</sup> Management options include surgical exploration for frank perforation, peritonitis, or abscess. In stable patients without overt complications, it is reasonable to attempt endoscopic removal.<sup>4,5</sup> We were successful in this case in removing the toothpick despite the presence of free air on CT, likely because of the chronicity and small size of the perforation.

## DISCLOSURES

Author contributions: A. Wehbeh wrote the manuscript. C. Dilly revised the manuscript for intellectual content and approved the final manuscript, and is the article guarantor.

Financial disclosure: None to report.

Informed consent was obtained for this case report.

Received April 25, 2020; Accepted May 8, 2020

## REFERENCES

1. Lai CMS, Lui TH. Small bowel perforation by toothpick. *BMJ Case Rep.* 2018;2018:bcr2018225258.
2. Steinbach C, Stockmann M, Jara M, et al. Accidentally ingested toothpicks causing severe gastrointestinal injury: A practical guideline for diagnosis and therapy based on 136 case reports. *World J Surg.* 2014; 38(2):371–7.
3. Zouros E, Oikonomou D, Theoharis G, et al. Perforation of the cecum by a toothpick: Report of a case and review of the literature. *J Emerg Med.* 2014; 47(6):e133–7.
4. Shields HM, Scheid FJ, Pierce TT, et al. Case 4-2019: An 18-year-old man with abdominal pain and hematochezia. *N Engl J Med.* 2019;380(5):473–85.
5. Dermesropian F, Dewit O, Pasoglou V. Perforation from ingested wooden toothpick: A colon diverticulitis mimicker: Key learning point: Foreign bodies should be considered in the differential when imaging displays bowel inflammation. *J Belg Soc Radiol.* 2019; 103(1):51.

---

**Copyright:** © 2020 The Author(s). Published by Wolters Kluwer Health, Inc. on behalf of The American College of Gastroenterology. This is an open-access article distributed under the terms of the Creative Commons Attribution-Non Commercial-No Derivatives License 4.0 (CCBY-NC-ND), where it is permissible to download and share the work provided it is properly cited. The work cannot be changed in any way or used commercially without permission from the journal.