

Psoriasiform Hailey-Hailey Disease Presenting as Erythematous Psoriasiform Plaques Throughout the Body: A Case Report

Jonathan Ni; Kathleen E Gilbert, MD; Ivie F Manalo, MD; Jashin J Wu, MD

Perm J 2018;22:17-016

E-pub: 11/29/2017

<https://doi.org/10.7812/TPP/17-016>

ABSTRACT

Introduction: Hailey-Hailey disease is an adult-onset skin condition characterized by lesions in the intertriginous regions of the body. The lesions can be pruritic, painful, and associated with physical and social impairment.

Case Presentation: We present a case of psoriasiform Hailey-Hailey disease in a 60-year-old white woman who exhibited erythematous psoriasiform plaques in many areas of her body. The patient's condition was successfully treated with a twice-daily regimen of doxycycline, mometasone, and clindamycin.

Discussion: It is important to recognize this variant of Hailey-Hailey disease so it can be diagnosed and treated promptly. Hailey-Hailey disease can be treated with topical corticosteroids and antibiotics and usually is associated with a positive prognosis.

INTRODUCTION

The first documented case of Hailey-Hailey disease, also known as familial benign chronic pemphigus, was published in 1939.¹ Hailey-Hailey disease is an autosomal-dominant disorder that is caused by mutations in the *ATP2C1* gene, which encodes a calcium pump.² Hailey-Hailey disease produces a variety of lesions on the skin, particularly in intertriginous areas, and usually onsets during adulthood. The disease commonly first appears on the neck and does not seem to affect the mouth and eyes. The lesions are sensitive to sweating, heat, friction, ultraviolet radiation, and cutaneous infections and worsen under these conditions. These lesions often trigger eczema and secondary bacterial (*Staphylococcus*, *Streptococcus*), viral, or fungal (dermatophytes, *Candida*) infections.^{3,4} Many patients experience pain and itching, with pain being the more debilitating and interfering with physical exertion. The disease limits some patients socially; for many, a noticeable odor arises from affected regions. Physical insults attributed to clothing with collars also can produce lesions in the neck area. The common appearance of white fingernail bands can aid in diagnosis. These bands vary in severity from pronounced to barely noticeable.³

CASE PRESENTATION

Presenting Concerns

A 60-year-old white woman presented to the Dermatology Department with a burning and itchy rash. Her history was significant for Hailey-Hailey disease since the age of 25. Stress and acidic foods exacerbate her condition. She previously was treated

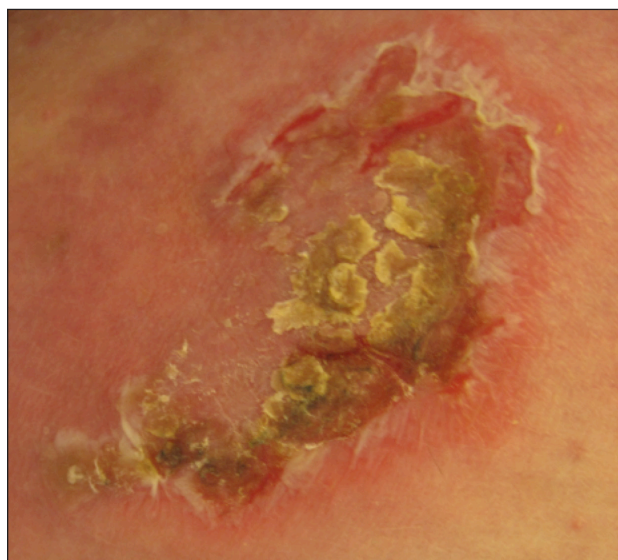


Figure 1. Erythematous psoriasiform plaques with yellow scale associated with Hailey-Hailey disease.

with mometasone, cephalexin, and intralesional triamcinolone. She also tried cyclosporine several years before but sustained an allergic reaction that resulted in a full-body rash. She had not received treatment in the 2 years preceding this presentation.

Upon physical examination, the patient had erythematous psoriasiform plaques with yellow scale on her upper abdomen, right upper arm, left upper thigh, and lower back regions (Figure 1). She did not have any lesions in her axilla or groin, or under her breasts. Histopathology was not available.

Therapeutic Intervention and Treatment

The patient was prescribed a schedule of doxycycline 100 mg, mometasone 0.1% topical cream, and clindamycin 1% topical lotion, all twice daily for 3 months.

Follow-up and Outcomes

The patient tolerated the treatment well and achieved excellent results, with most of the plaques clearing up. However, several new lesions appeared on her groin area, most likely

Jonathan Ni is a Medical Student at Boston University School of Medicine in MA. E-mail: jni@bu.edu. Kathleen E Gilbert, MD, is a Resident in the Department of Dermatology at Indiana University in Indianapolis. E-mail: katgilbe@iupui.edu. Ivie F Manalo, MD, is a Resident in the Department of Dermatology at Emory University in Atlanta, GA. E-mail: ivie.manalo@gmail.com. Jashin J Wu, MD, is a Dermatologist at the Los Angeles Medical Center in CA. E-mail: jashinwu@gmail.com.

attributable to outdoor heat exposure. Upon follow-up, the patient experienced continued success with the treatment, with lesions limited to only occasional flares.

DISCUSSION

This patient had psoriasiform Hailey-Hailey disease, and this variant has not been described in the literature to our knowledge. A possible explanation for the atypical trunk involvement in this patient may be Koebnerization. The diagnosis of Hailey-Hailey disease is suggested by its characteristic clinical manifestation of macerated erosions limited to the intertriginous areas and the absence of satellite lesions. The diagnosis is confirmed by histopathologic examination and direct immunofluorescence staining of a skin biopsy. Histopathologic examination demonstrates widespread acantholysis resulting in suprabasal clefts and acantholytic vesicles and bullae. Negative direct immunofluorescence for intercellular immunoglobulin G differentiates Hailey-Hailey disease from pemphigus vulgaris.⁴

CONCLUSION

For most patients with Hailey-Hailey disease, long-term prognosis is good, but they may experience many remissions and relapses throughout the course of the disease.³ Treatment for Hailey-Hailey disease centers on controlling exacerbating factors, secondary infections, and cutaneous inflammation.⁴ Effective treatment involves topical corticosteroids in conjunction with topical or oral antibiotics.³ ❖

Disclosure Statement

The author(s) have no conflicts of interest to disclose.

Acknowledgment

Brenda Moss Feinberg, ELS, provided editorial assistance.

How to Cite this Article

Ni J, Gilbert KE, Manalo IF, Wu JJ. Psoriasiform Hailey-Hailey disease presenting as erythematous psoriasiform plaques throughout the body: A case report. *Perm J* 2018;22:17-016. DOI: <https://doi.org/10.7812/TPP/17-016>

References

1. Hailey H, Hailey H. Familial benign chronic pemphigus. *Arch Dermatol Syphilol* 1939 Apr;39(4):679-85. DOI: <https://doi.org/10.1001/archderm.1939.01480220064005>.
2. Hu Z, Bonifas JM, Beech J, et al. Mutations in ATP2C1, encoding a calcium pump, cause Hailey-Hailey disease. *Nat Genet* 2000 Jan;24(1):61-5. DOI: <https://doi.org/10.1038/71701>.
3. Burge SM. Hailey-Hailey disease: The clinical features, response to treatment and prognosis. *Br J Dermatol* 1992 Mar;126(3):275-82. DOI: <https://doi.org/10.1111/j.1365-2133.1992.tb00658.x>.
4. Weedon D. Disorders of epidermal maturation and keratinization. In: *Weedon's skin pathology*. 3rd ed. London, UK: Elsevier Ltd; 2010. p 219-54.