

Recurrence of Cutaneous Coccidioidomycosis Six Years after Valley Fever: a Case Presentation and Literature Review

Rana Shahab¹, Nasir K Amra², Rola Rabah², Justin Saunar³, Joan Soriano³, Jaffar A. Al-Tawfiq^{1,4*}

¹ Specialty Internal Medicine, Johns Hopkins Aramco Healthcare, Dhahran, Saudi Arabia,

² Pathology, Johns Hopkins Aramco Healthcare, Dhahran, Saudi Arabia ³ Microbiology, Johns Hopkins Aramco Healthcare, Dhahran, Saudi Arabia and ⁴ Indiana University School of Medicine, Indiana, USA.

***Corresponding author:**

Dr. Jaffar A. Al-Tawfiq

P.O. Box 76, Room A-428-2, Building 61, Dhahran Health Center,

Johns Hopkins Aramco Healthcare, Dhahran 31311, Saudi Arabia.

Email address: jaffar.tawfiq@jhah.com; jaltawfi@yahoo.com

Tel: +966-13-877-3524

Fax: +966-13-877-3790

Abstract:

Coccidioidomycosis is usually acquired by inhalation of spores of *Coccidioides immitis* and *C. posadasii*. The disease ranges from a self-limited acute pneumonia (Valley Fever) to a disseminated disease. We present a 44 year-old healthy male who had patchy hair loss of several months duration resembling discoid lupus. He developed a firm non-scaly red plaque on the right forehead. Initial biopsy showed spongiotic dermatitis, and he was treated with systemic steroids. He then developed forehead and periorbital cellulitis and was treated with systemic antibiotics. A second biopsy showed fungal hyphae and he was treated with itraconazole 200 mg bid for 4 months beyond clinical resolution. A year later, he presented with intermittent swelling of the right forehead lesion and worsening of the scalp lesions. A forehead biopsy showed interface dermatitis and negative PAS stain for fungi. Scalp biopsy was highly suggestive of discoid lupus and he was started on plaquenil. Many months later, a third biopsy showed fungal infection, and the culture grew *C. immitis*. He was treated with itraconazole. Retrospectively, the patient gave a history of Valley fever six years back when he was in Arizona.

Introduction:

Coccidioidomycosis is an infection usually acquired by inhalation of spores of a dimorphic fungus of the genus *Coccidioides* (*Coccidioides immitis* and *C. posadasii*) [1]. The disease ranges from a self-limited acute pneumonia (Valley Fever) to dissemination in immunosuppressed patients. The most common form of the disease is primary pulmonary coccidioidomycosis and is usually asymptomatic in 60% of patients [2,3]. Dermatologic manifestations may occur in 50% of cases during Valley Fever [4]. Immunity to exogenous reinfection occurs in most patients with primary disease [5]. Here, we present a case of cutaneous coccidioidomycosis reoccurring six years after the initial disease.

Case Presentation:

On February 7, 2012 a 44 year old male was seen at an outside clinic for a two-month history of hair loss and he was treated with doxycycline for presumed scalp folliculitis, resembling discoid lupus. Two of the patient's siblings had lupus erythematosus. Then, he presented to us with a firm non-scaly red plaque on the right forehead. On examination, there were two atrophic patches of hair loss with hyperpigmented center suggestive of scarring alopecia, discoid lupus, or orlichen planopilaris. He was treated with clobetasol propionate 0.05% lotion once a day.

One week later, he presented with a firm plaque, 3x3 cm, on the right forehead with an associated mild swelling of the surrounding area with no scales. The working diagnoses were calcinosis cutis or discoid lupus. Antinuclear antibody (ANA) was negative. A 3-mm skin biopsy was taken and he was started on a tapering dose of oral prednisone. The right forehead biopsy showed spongiotic dermatitis with chronic perivascular and periadnexal inflammation

with numerous eosinophils, suggestive of arthropod bite, drug reaction or urticarial reaction (Figure 1).

Ten days later, he presented with a swelling of the right side of the face associated with purulent discharge of one-day duration. He had no fever or chills. Examination showed a mass with fluctuation on the forehead. Prednisone was discontinued and he was started on amoxicillin-clavulanic acid. The following day, the swelling got worse and he was unable to open his right eye. He was admitted as a case of eosinophilic cellulitis. Vancomycin was started in addition to pain medications. WBC was 9,500 with 7% eosinophilia and IgE 7420. Next day, the swelling markedly improved and the forehead lesion was crusting and erythematous. Culture of forehead lesion grew coagulase negative Staphylococcus. He did well and was discharged on clindamycin.

On follow up one week after discharge, there was a 2-cm infiltrated plaque on the right forehead with overlying crust. Two biopsies were taken for hematoxylin and eosin stain and fungal, mycobacteria and bacterial cultures. The patient was treated with itraconazole 200 mg bid and clindamycin was continued as the infectious disease physician felt that the lesion resembled coccidioidomycosis. Histopathology showed fungal granulomatous inflammation (figure 2) and the tissue grew a mold. However, no further characterization was done by the microbiology laboratory. The patient was kept on itraconazole for a total of 4 months until clinically the forehead lesion resolved completely.

In April 2013, he presented with pruritic scalp lesions, hair loss, and a mobile cystic mass on the right forehead. Biopsies showed interface dermatitis with a superficial, perivascular interstitial, and perifollicular lymphohistiocytic infiltrate extending to the deep margins suggestive of lupus

erythematosus. GMS stain was negative for fungal organism. ANA was negative and the patient was started on plaquenil 200 mg bid and tacrolimus ointment to scalp lesions. The forehead lesion worsened and a repeat biopsy showed granulomatous dermatitis with fungal elements (figure 3) and the culture grew *C. immitis* (figure 4). The patient was started on voriconazole 200 mg bid initially then it was changed to itraconazole after a couple of weeks for compliance issues. In July 2014, Coccidioides antibodies level was 1:8 and then the patient recalled having a diagnosis of Valley Fever in Arizona in 2006 for which he was treated. *C. immitis* titer was monitored and remained at 1:2 after completing 12 months of therapy. He was seen on a regular follow up and the forehead lesion healed.

DISCUSSION

Coccidioidomycosis is usually acquired through inhalation of the spores of *C. immitis* or *C. posadasii*. *C. immitis* is geographically found in central and southern California including the San Joaquin Valley whereas *C. posadasii* is found in Arizona, New Mexico, Texas, Nevada and Utah [6]. The most frequent manifestation of coccidioidomycosis is being asymptomatic or as a mild upper respiratory infection. Other patients may develop an acute respiratory infection one to four weeks after exposure [2,3]. Extrapulmonary dissemination may occur in 22% of patients with racial difference where African American develop disseminated bony disease and Filipinos develop cutaneous or central nervous system disease [2], and predominance among immunocompromized patients [7]. Skin involvement presents with papules, nodules, ulcers, warty lesions or acne like anywhere on the body but most common on the face. The current case did not raise the diagnosis of coccidioidomycosis due to the non-availability of a previous history and thus the diagnosis was not considered as was stated previously [8]. Later on, the history was obtained as a recollection of an initial diagnosis of coccidioidomycosis six years previously.

One of the mechanisms of recurrent disease is related to reactivation of the primary infection in immunocompromized patients [9]. In the present case, there was no evidence of immunosuppression prior to the onset of the coccidioidal recurrence and the ten-day course of prednisone was unlikely to cause severe immunosuppression. Thus, the recurrence of coccidioidomycosis six years after primary coccidioidal pneumonia is distinctly unusual. Cutaneous coccidioidomycosis might be misdiagnosed as discoid lupus or atopic dermatitis [10]. Cutaneous manifestations of coccidioidomycosis could be an immunologic reaction during an acute primary pulmonary infection, may present as an organism-specific manifestation as a result of hematogenous spread and rarely as a direct skin inoculation [11,12]. In a study of 34 patients, the mean time to relapse after completion of therapy was 7.3 months (range, 1-21 months) [13]. Following antifungal therapy for primary pulmonary infection, relapses were reported up to four years after treatment [2,14]. However, early treatment of coccidioidal pneumonia with an oral antifungal such as fluconazole alters the natural history of coccidioidal infection. Thus, the relapse in those cases was likely related to the fact that azoles are not fungicidals and do not eradicate infections. This patient had relapse after a six-year period and unfortunately the details of his initial illness and therapy are not known. Treatment depends on the immune status and the extent of the disease. Azole antifungals are given for 3-6 months and therapy is continued for an additional 6 months after clinical response [12,15–17]. However, therapy is often unable to prevent relapse [15]. The recommended duration of therapy for cutaneous disease is at least 6–12 months [16,17].

In conclusion, we believe that our patient's reactivation of cutaneous coccidioidomycosis might be secondary to insufficient treatment of the first episode. The recurrence of coccidioidomycosis six years after primary coccidioidal pneumonia is distinctly unusual.

Conflicts: On behalf of all authors, the corresponding author states that there is no conflict of interest

Ethical Approval: The case report was approved by the Institutional Review Board (IRB) of Johns Hopkins Aramco Healthcare

ACCEPTED MANUSCRIPT

References:

- [1] Welsh O, Vera-Cabrera L, Rendon A, Gonzalez G, Bonifaz A. Coccidioidomycosis. *Clin Dermatol* 2012;30:573–91. doi:10.1016/j.clindermatol.2012.01.003.
- [2] Crum NF, Lederman ER, Stafford CM, Parrish JS, Wallace MR. Coccidioidomycosis: a descriptive survey of a reemerging disease. Clinical characteristics and current controversies. *Medicine (Baltimore)* 2004;83:149–75.
- [3] Parish JM, Blair JE. Coccidioidomycosis. *Mayo Clin Proc* 2008;83:343–9. doi:10.4065/83.3.343.
- [4] Garcia Garcia SC, Salas Alanis JC, Flores MG, Gonzalez Gonzalez SE, Vera Cabrera L, Ocampo Candiani J. Coccidioidomycosis and the skin: a comprehensive review. *An Bras Dermatol* 2015;90:610–9. doi:10.1590/abd1806-4841.20153805.
- [5] Hector RF, Laniado-Laborin R. Coccidioidomycosis—A Fungal Disease of the Americas. *PLoS Med* 2005;2:e2. doi:10.1371/journal.pmed.0020002.
- [6] Brown J, Benedict K, Park BJ, Thompson GR, III. Coccidioidomycosis: epidemiology. *Clin Epidemiol* 2013;5:185–97. doi:10.2147/CLEP.S34434.
- [7] Adam RD, Elliott SP, Taljanovic MS. The spectrum and presentation of disseminated coccidioidomycosis. *Am J Med* 2009;122:770–7. doi:10.1016/j.amjmed.2008.12.024.
- [8] Stevens DA. Coccidioidomycosis. *N Engl J Med* 1995;332:1077–82. doi:10.1056/NEJM199504203321607.
- [9] Salkin D. Clinical examples of reinfection in coccidioidomycosis. *Am Rev Respir Dis*

- 1967;95:603–11. doi:10.1164/arrd.1967.95.4.603.
- [10] Ocampo-Garza J, Castrejón-Pérez AD, Gonzalez-Saldivar G, Ocampo-Candiani J. Cutaneous coccidioidomycosis: a great mimicker. *BMJ Case Rep* 2015;2015:bcr2015211680. doi:10.1136/bcr-2015-211680.
- [11] Rivard SC, Satter E. Primary Cutaneous Coccidioidomycosis Presenting as a Recurrent Preauricular Cyst. *Skinmed* 2016;14:142–4.
- [12] BLAIR JE. State-of-the-Art Treatment of Coccidioidomycosis: Skin and Soft-Tissue Infections. *Ann N Y Acad Sci* 2007;1111:411–21. doi:10.1196/annals.1406.010.
- [13] Oldfield EC, Bone WD, Martin CR, Gray GC, Olson P, Schillaci RF. Prediction of relapse after treatment of coccidioidomycosis. *Clin Infect Dis* 1997;25:1205–10.
- [14] Ampel NM, Giblin A, Mourani JP, Galgiani JN. Factors and outcomes associated with the decision to treat primary pulmonary coccidioidomycosis. *Clin Infect Dis* 2009;48:172–8. doi:10.1086/595687.
- [15] Graybill JR, Stevens DA, Galgiani JN, Dismukes WE, Cloud GA. Itraconazole treatment of coccidioidomycosis. NAIAD Mycoses Study Group. *Am J Med* 1990;89:282–90.
- [16] Galgiani JN, Ampel NM, Blair JE, Catanzaro A, Geertsma F, Hoover SE, et al. 2016 Infectious Diseases Society of America (IDSA) Clinical Practice Guideline for the Treatment of Coccidioidomycosis. *Clin Infect Dis* 2016;63:e112-46. doi:10.1093/cid/ciw360.
- [17] Galgiani JN, Ampel NM, Blair JE, Catanzaro A, Geertsma F, Hoover SE, et al. Executive Summary: 2016 Infectious Diseases Society of America (IDSA) Clinical Practice

Guideline for the Treatment of Coccidioidomycosis. Clin Infect Dis 2016;63:717–22.

doi:10.1093/cid/ciw538.

ACCEPTED MANUSCRIPT

Figures Legends:

Figure 1: First biopsy demonstrating superficial spongiotic dermatitis with eosinophils (hematoxylin and eosin, x280 magnification)

Figure 2: Second biopsy with fungal granulomatous inflammation with arrow pointing at Coccidioidomycosis endospore (hematoxylin and eosin, x880 magnification)

Figure 3: Cluster of fungal Coccidioidomycosis endospores at arrow (Grocott's methenamine silver, x1100 magnification)

Figure 4: After 36 days of incubation, a lactophenol blue stain shows a typical hyaline single-celled rectangular to barrel shaped alternate arthroconidia (A) separated from each other by a disjunct cell (B).

Figure 1: First biopsy demonstrating superficial spongiotic dermatitis with eosinophils (hematoxylin and eosin, x885 magnification)

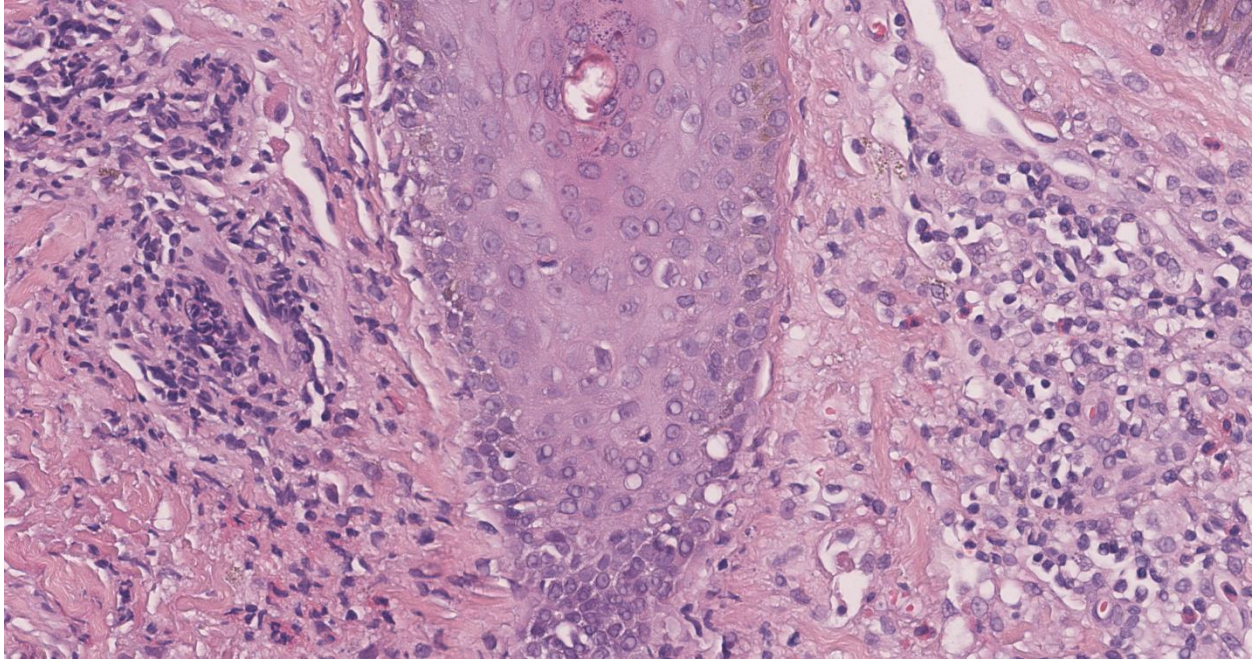


Figure 2: Second biopsy with fungal granulomatous inflammation with arrow pointing at Coccidioidomycosis endospore (hematoxylin and eosin, x880 magnification)

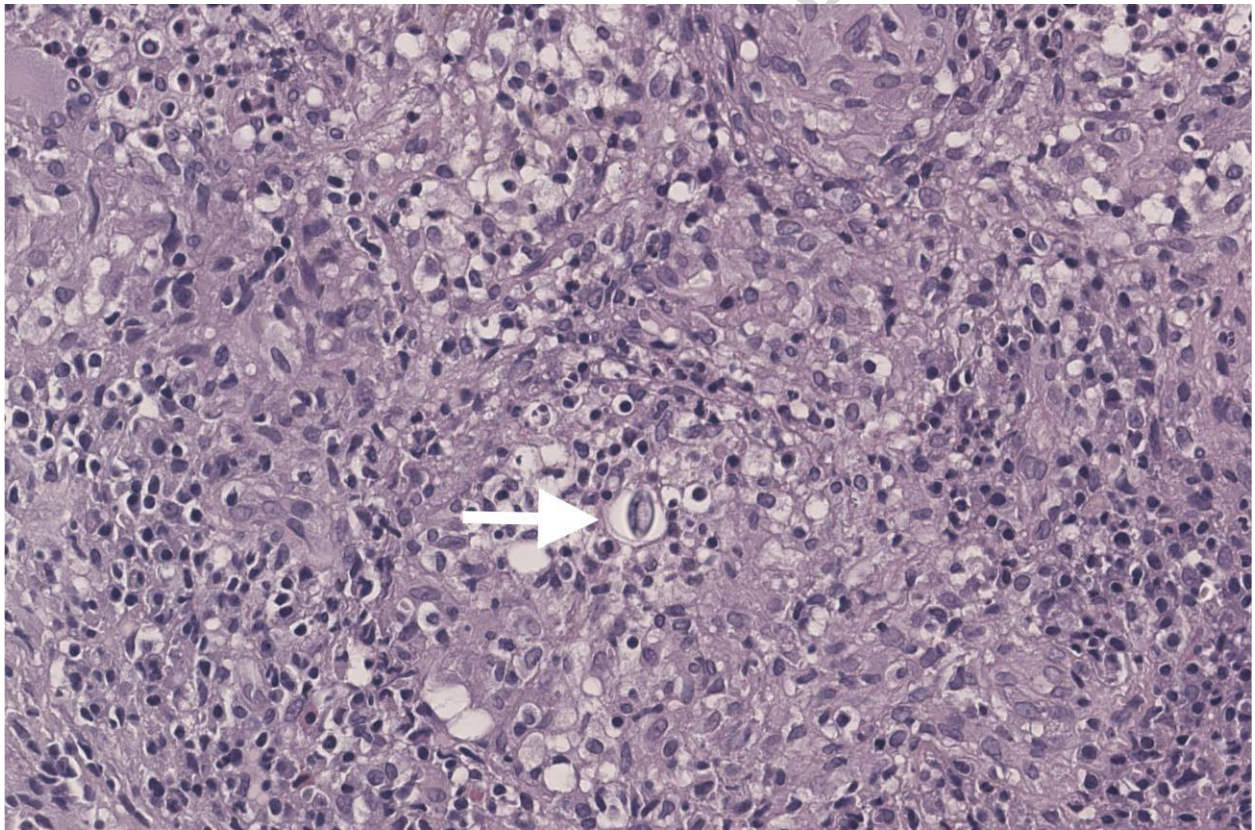


Figure 3: Cluster of fungal Coccidioidomycosis endospores at arrow (Grocott's methenamine silver, x1100 magnification)

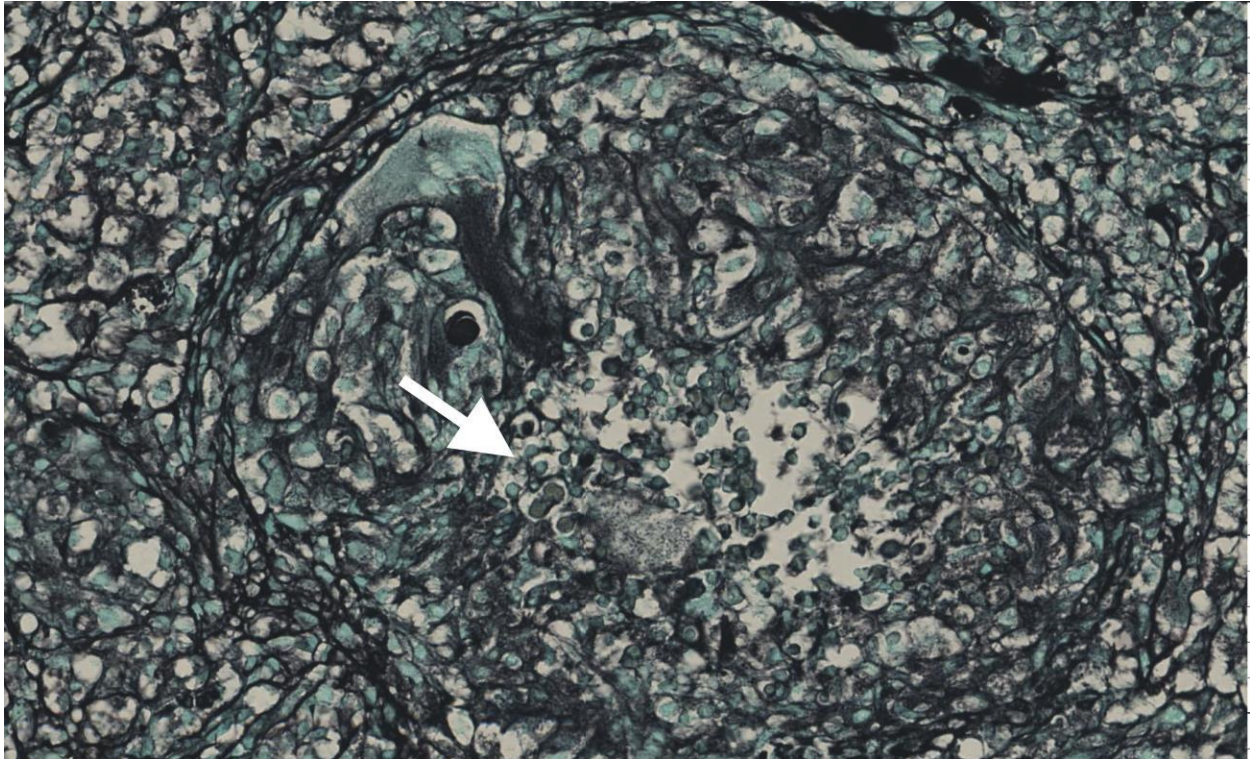


Figure 4: After 36 days of incubation, a lactophenol blue stain showing a typical hyaline single celled rectangular to barrel shaped alternate arthroconidia (A) separated from each other by a disjunctor cell (B).

