

UC Davis

Dermatology Online Journal

Title

Pyoderma gangrenosum: a presenting sign of myelodysplastic syndrome in undiagnosed Fanconi anemia

Permalink

<https://escholarship.org/uc/item/9xj8b544>

Journal

Dermatology Online Journal, 25(1)

Authors

Kandula, Prasanthi
Shah, Kishan M
Wolverton, Jay E
[et al.](#)

Publication Date

2019

License

[CC BY-NC-ND 4.0](#)

Peer reviewed

Pyoderma gangrenosum: a presenting sign of myelodysplastic syndrome in undiagnosed Fanconi anemia

Prasanthi Kandula¹ MD, Kishan M Shah¹ BA, Jay E Wolverton¹ MD, Cuong Le² DO, Stephen E Wolverton¹ MD

Affiliations: ¹Department of Dermatology, Indiana University School of Medicine, Indianapolis, Indiana, USA, ²Department of Dermatology, Palisades Medical Center, North Bergen, New Jersey, USA

Corresponding Author: Kishan M Shah BA, Department of Dermatology, Indiana University School of Medicine, 545 Barnhill Drive – EH 139, Indianapolis, IN 46202, Email: kmsah@indiana.edu

Abstract

A 26-year-old man with a history of congenital bilateral microtia, unilateral renal agenesis, left aural atresia, and right external auditory canal occlusion admitted for right rib cartilage graft harvest and left ear re-construction. Following surgery, an ulceration with violaceous borders and a yellow fibrinous base unresponsive to broad-spectrum antibiotics developed at the harvest site. The wound was expanding and not responsive to systemic broad-spectrum antibiotics. Biopsy revealed a dense dermal infiltrate of neutrophils with negative tissue cultures consistent with pyoderma gangrenosum (PG). He was treated with systemic, intralesional, and topical steroids, as well as doxycycline. Three weeks after the diagnosis of PG, he was found to have persistent anemia and leukopenia. Bone marrow aspiration analysis was consistent with hypocellular myelodysplastic syndrome and genetic testing was consistent with Fanconi anemia. There is a well-known association of PG with hematological disorders. Fanconi anemia is a rare genetic hematologic disorder with congenital defects leading to bone marrow failure and malignancy in long-standing disease. In our patient, we consider his development of PG a paraneoplastic sign associated with the onset of his hypocellular myelodysplastic syndrome.

Keywords: pyoderma gangrenosum, Fanconi anemia, myelodysplastic syndrome

Introduction

Pyoderma gangrenosum (PG) is a neutrophilic dermatosis that has a well-known association with

several medical comorbidities. PG is associated with hematological disorders, including monoclonal gammopathies, acute and chronic myelogenous leukemias, hairy cell leukemia, and myelodysplasia [1]. We report a case of PG as the presenting sign of myelodysplastic syndrome (MDS) in a patient with undiagnosed Fanconi anemia.

Case Synopsis

A 26-year-old man with a history of congenital bilateral microtia, unilateral renal agenesis, left aural atresia, and right external auditory canal occlusion was admitted for rib cartilage graft harvest and left ear re-construction. A week after the surgery, examination of the rib harvest site on the right lateral chest revealed a 10×19 centimeter, ulcerated plaque

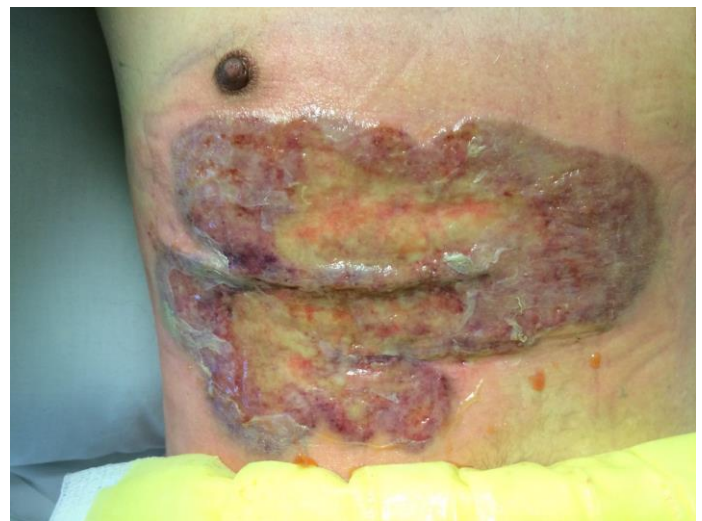

Figure 1: Ulcerated plaque on the right lateral chest with violaceous, undermined borders, and a yellow fibrinous base after right rib cartilage graft harvest.

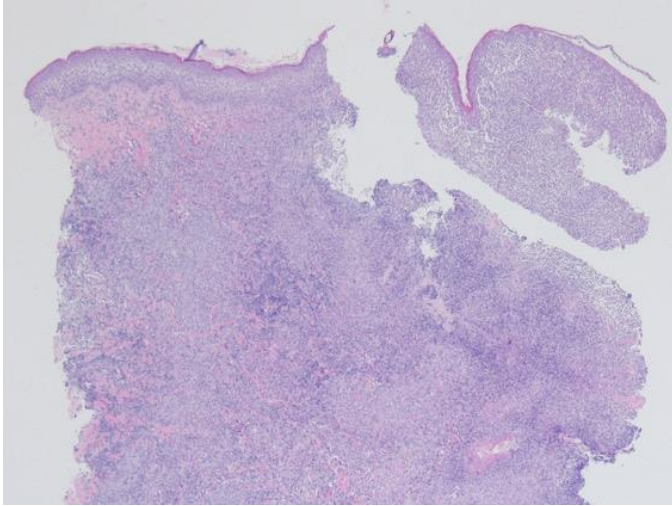


Figure 2: Histopathology shows a dense dermal infiltrate involving the dermis, H&E, 2x.

with violaceous, undermined borders, and a yellow fibrinous base (**Figure 1**). The wound rapidly expanded and was not responsive to systemic broad-spectrum antibiotics. Biopsy revealed a dense dermal infiltrate of neutrophils extending into the underlying subcutaneous tissue (**Figures 2, 3**). Periodic acid Schiff, Grocott-Gomori methenamine silver, acid-fast bacilli, and Gram stains were all negative. Complete blood count with differential and complete metabolic profile were within normal limits during his admission to the hospital. His PG was diagnosed on clinical-pathological correlation.

Three weeks after the diagnosis of PG, repeat laboratory studies demonstrated anemia with a hemoglobin of 11.7 g/dl, leukopenia with a white blood cell count of 800/mm³, and an absolute neutrophil count of 100/mm³. His red blood cells demonstrated polychromasia, basophilic stippling, and increased nucleated red blood cells. His complete metabolic profile revealed an elevated alanine transaminase of 162 units/L and aspartate transaminase level of 43 units/L. He was referred to the hematology department where subsequent bone marrow aspiration was consistent with hypocellular MDS and demonstrated 7q31 chromosomal loss. Cytogenetic analysis testing confirmed a diagnosis of Fanconi anemia.

The patient was treated with topical clobetasol and oral doxycycline during his initial hospital course and was discharged on a prednisone taper. At his follow-

up appointments, his ulceration significantly decreased in size and was asymptomatic (**Figure 4**). Intralesional corticosteroid injections were performed at his follow-up appointments every 4-6 weeks. After beginning chemotherapy for his MDS, he was admitted to the hospital three months after his initial diagnosis because of febrile neutropenia and a flare of his PG was noted at that time. The patient ultimately passed away from multisystem organ failure following a pulmonary infection.

Case Discussion

In our patient, we consider the development of his PG a paraneoplastic sign associated with the onset of his hypocellular MDS in the setting of his previously undiagnosed Fanconi anemia. The frequency of underlying malignancy associated with PG is approximately 5% [1]. Of the various hematologic malignancies with which PG is associated, acute myelogenous leukemia MDS, refractory anemia, and paraproteinemia are most common [2]. An atypical or bullous PG is a more superficial variant of PG characterized by hemorrhagic bullae on the upper extremities. It is often associated with such hematologic malignancies [3]. Our patient's PG shares features of the atypical and superficial granulomatous variants: the atypical variant appeared related to his underlying myelodysplasia, but the truncal location, development after surgery, and rapid improvement with topical corticosteroids

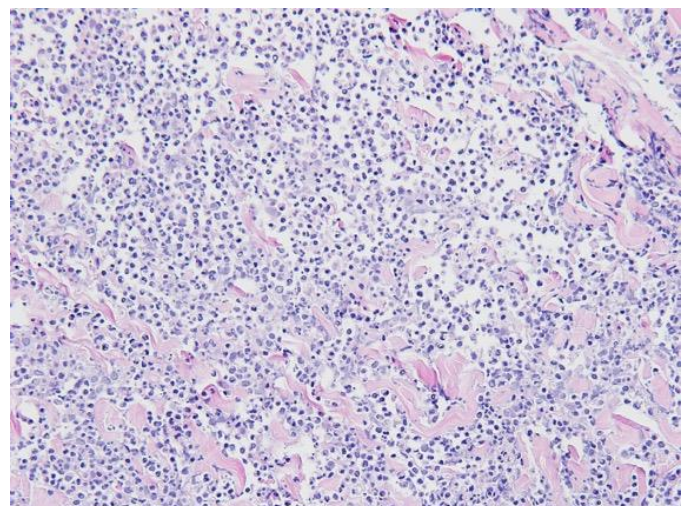


Figure 3: Histopathology reveals a dense, sheet-like infiltrate of neutrophils, H&E, 40x.

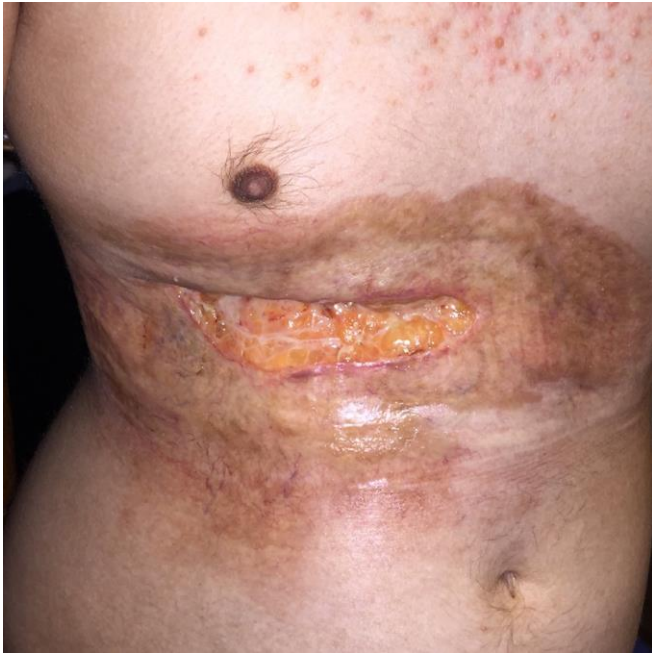

Figure 4: Improvement of the ulceration after treatment with topical, intralesional, and systemic corticosteroids, as well as doxycycline.

and low dose prednisone are characteristics of early superficial granulomatous PG [3, 4].

Fanconi anemia is a rare autosomal recessive genetic hematologic condition that results in mutations leading to defects in proteins responsible for DNA repair. Congenital defects include short stature, abnormal skin pigmentation, skeletal malformations of the upper and lower limbs, microcephaly, and ophthalmic and genitourinary anomalies. Fanconi anemia can predispose patients to hematologic conditions such as aplastic anemia MDS, and acute myeloid leukemia in long-standing disease [5].

An association between PG and Fanconi anemia has been previously documented in only one other patient, to our knowledge. Serrano J., et al., reported an 8-year-old girl with Fanconi anemia who developed a 15x10 centimeter ulceration that was clinical-pathologically consistent with pyoderma gangrenosum (**Table 1**), [6]. Like our case, her PG was large, occurred in the setting of trauma, and rapidly responded to systemic corticosteroids. Our case is unique in that although pathergy may have played a role in development of his PG, the temporal relationship between his PG and the onset of his MDS suggest PG as a heralding sign of MDS in the setting of previously undiagnosed Fanconi anemia. There have been several reported cases of MDS and PG [7-10], though the pathogenesis of the association is unknown.

Treatment modalities for PG include induced immunosuppression, commonly with glucocorticoid therapy in the form of topical, intralesional, or systemic corticosteroids depending on the severity. Other immunosuppressive agents including cyclosporine, oral tetracycline-class antibiotics, methotrexate, thalidomide, and anti-TNF inhibitors have successfully treated PG [2]. Surgical treatment is controversial owing to the phenomenon of pathergy, though several case reports have suggested the utility of split skin grafting with concomitant immunosuppressive therapy for recalcitrant disease, which is generally done after the active inflammatory PG has become quiescent with treatment [11].

Table 1. Single report of linkage between pyoderma gangrenosum and Fanconi anemia [6].

	Kandula P et al., current case	Serrano J et al. [6]
Epidemiology	26-year-old male with undiagnosed Fanconi anemia	8-year-old female with established diagnosis of Fanconi's Anemia
Clinical	10x19 cm ulcerated plaque with violaceous, undermined borders and yellow fibrinous base following surgery	10x15 cm painful, indurated bluish plaque with narrow halo of erythema and several ulcerated areas following minor trauma
Histopathology	Dense, sheet like infiltrate of neutrophils involving the dermis	Dense infiltrate of acute inflammatory cells at margin of lesions with chronic inflammatory infiltrate in central region
Treatment	Topical clobetasol, oral doxycycline, intralesional triamcinolone, prednisone taper	Prednisone taper

Conclusion

In summary, we present an interesting case in which PG represented the presenting sign of myelodysplastic syndrome in the setting of Fanconi

anemia. PG, especially the atypical subtype, should raise suspicion for underlying malignancy as it may represent a paraneoplastic sign.

References

1. Ashchyan HJ, Butler DC, Nelson CA, Noe MH, Tsiaras WG, Lockwood SJ, James WD, Micheletti RG, Rosenbach M, Mostaghimi A. The Association of Age With Clinical Presentation and Comorbidities of Pyoderma Gangrenosum. *JAMA Dermatol.* 2018;154(4):409-13. [PMID: 29450453].
2. Powell FC, Su WP, Perry HO. Pyoderma gangrenosum: classification and management. *J Am Acad Dermatol.* 1996;34(3):395-409; quiz 10-2. [PMID: 8609250].
3. Bennett ML, Jackson JM, Jorizzo JL, Fleischer AB, Jr., White WL, Callen JP. Pyoderma gangrenosum. A comparison of typical and atypical forms with an emphasis on time to remission. Case review of 86 patients from 2 institutions. *Medicine (Baltimore).* 2000;79(1):37-46. [PMID: 10670408].
4. Lichter MD, Welykyj SE, Gradini R, Solomon LM. Superficial granulomatous pyoderma. *Int J Dermatol.* 1991;30(6):418-21. [PMID: 1894406].
5. Alter BP. Cancer in Fanconi anemia, 1927-2001. *Cancer.* 2003;97(2):425-40. [PMID: 12518367].
6. Serrano J, Rojas R, Sanchez J, Falcon M, Roman J, Castillejo JA, Navarro JA, Torres A. Pyoderma gangrenosum associated with Fanconi's anemia. *Dermatology.* 1998;196(3):370-1. [PMID: 9621159].
7. Ha JW, Hahm JE, Kim KS, Kim SS, Kim CW. A Case of Pyoderma Gangrenosum with Myelodysplastic Syndrome. *Ann Dermatol.* 2018;30(3):392-3. [PMID: 29853768].
8. Yamanaka K, Kuniyuki S, Maekawa N, Yoshida Y, Teshima H. Pyoderma gangrenosum with myelodysplastic syndrome treated with analogous bone marrow transplantation. *Acta Derm Venereol.* 2009;89(1):105-6. [PMID: 19197560].
9. Litvak D, Kirsner RS, Pakdaman NN, Federman DG. Pyoderma gangrenosum and myelodysplastic syndrome. *South Med J.* 2000;93(9):923-5. [PMID: 11005358].
10. Koca E, Duman AE, Cetiner D, Buyukasik Y, Haznedaroglu IC, Uner A, Demirhan B, Kerimoglu U, Barista I, Calguneri M, Ozcebe OI. Successful treatment of myelodysplastic syndrome-induced pyoderma gangrenosum. *Neth J Med.* 2006;64(11):422-4. [PMID: 17179573].
11. Lamet S, Bracke A, Geluykens E, Vlieghe E, Seymons K, Gadisseur AP, Vrelust I, Van Marck V, Somville J, Lambert J. Medical and surgical management of paraneoplastic pyoderma gangrenosum--a case report and review of the literature. *Acta Clin Belg.* 2010;65(1):37-40. [PMID: 20373596].