



Contents lists available at ScienceDirect

Urology Case Reports

journal homepage: www.elsevier.com/locate/eucr

Oncology

Primary testicular teratoid Wilms tumor in a 40-year-old male with retroperitoneal lymph node involvement: A case report

Eylon J. Arbel^{a,*}, Brian F. Dinerman^b, John Rutkowski^b, Andrés M. Acosta^c, Jeffrey Spencer^b^a University at Buffalo Jacobs School of Medicine and Biomedical Sciences, Buffalo, NY, USA^b University at Buffalo Jacobs School of Medicine and Biomedical Sciences, Department of Urology, Buffalo, NY, USA^c Indiana University School of Medicine, Department of Pathology, Indianapolis, IN, USA

ARTICLE INFO

Keywords:

Wilms tumor
Teratoma
Primary testicular malignancy
Germ cell tumor
Nephroblastoma

ABSTRACT

We report a 40-year-old male presenting with right testicular pain. Following right orchiectomy demonstrating pT1bSONOM0 teratoma with extensive necrosis, the patient opted for surveillance. With new retroperitoneal lymphadenopathy, the patient underwent a robotic-assisted laparoscopic retroperitoneal lymph node. After final pathology demonstrated extensive necrosis, the initial orchiectomy specimen was re-reviewed which revealed 60/40 ratio of non-seminomatous teratoma to nephroblastoma.

Adult presentation of testicular nephroblastoma is exceedingly rare and such reports contribute to the understanding of adult teratoid Wilms tumor pathogenesis. This case emphasizes the need for comprehensive diagnostic approaches and further research into the pathophysiology of extrarenal teratoid Wilms tumors.

1. Introduction

Wilms tumor, also known as nephroblastoma, is predominantly a pediatric renal malignancy commonly associated with mutations in WT1 and WT2 genes, among others.¹ It typically presents as an asymptomatic abdominal mass in children, however, constitutional symptoms such as malaise, hypertension, and hematuria are occasionally observed. While treatment advances have significantly improved survival rates in children, adult presentations are exceedingly rare, estimated at less than 0.2 cases per million per year in the United States.¹

Adult Wilms tumors, especially those originating extrarenally, such as from testicular teratomas, are exceptionally uncommon. Compared to classic Wilms tumor pathology, the molecular mechanisms responsible for extrarenal testicular Wilms tumor are currently unknown. These cases often pose diagnostic and therapeutic challenges due to their rarity and the absence of established treatment guidelines and categorizations for adults. There are very few reports of Wilms tumor arising from a primary testicular germ cell tumor such as the case we present here.¹⁻⁴ Adult patients usually present with more advanced disease and may experience more severe chemotherapy toxicities compared to pediatric cases. This makes the management of adult Wilms tumor a complex and multidisciplinary endeavor, requiring careful consideration of the unique aspects of each case.

2. Case report

We report the management of a 40-year-old male who initially presented with right-sided testicular swelling and pain for several months, claiming this was due to a suspected crush injury approximately one year prior. Ultrasound demonstrated a 3.4cm right testicular mass with blood flow concerning for malignancy and a large reactive hydrocele. Alpha-fetoprotein (AFP), human chorionic gonadotropin (hCG), and lactate dehydrogenase (LDH) were all within normal limits pre-operatively. The patient was also recently diagnosed with multiple sclerosis.

The patient underwent an uncomplicated right radical orchiectomy. Pathological analysis revealed malignant teratoma with extensive necrosis. CT imaging of the chest demonstrated no disease, however the CT of the abdomen and pelvis demonstrated significant lymphadenopathy in the retroperitoneum. There were multiple lymph nodes measuring 2cm in diameter in periaortic and inter-aortocaval regions (Fig. 1). Subsequent PET-CT scan confirmed multiple enlarged lymph nodes in those regions and tumor markers remained normal at the time. Now with stage 2A disease with teratoma predominance, the patient was subsequently scheduled for robotic-assisted laparoscopic retroperitoneal lymph node dissection (RPLND) with a full template non-nerve sparing technique and excision of the right spermatic cord.

* Corresponding author. University at Buffalo, Jacobs School of Medicine and Biomedical Sciences, 955 Main St., Buffalo, NY, 14203, USA.

E-mail address: eylonarb@buffalo.edu (E.J. Arbel).

<https://doi.org/10.1016/j.eucr.2024.102701>

Received 2 March 2024; Accepted 4 March 2024

Available online 5 March 2024

2214-4420/© 2024 The Authors. Published by Elsevier Inc. This is an open access article under the CC BY-NC license (<http://creativecommons.org/licenses/by-nc/4.0/>).

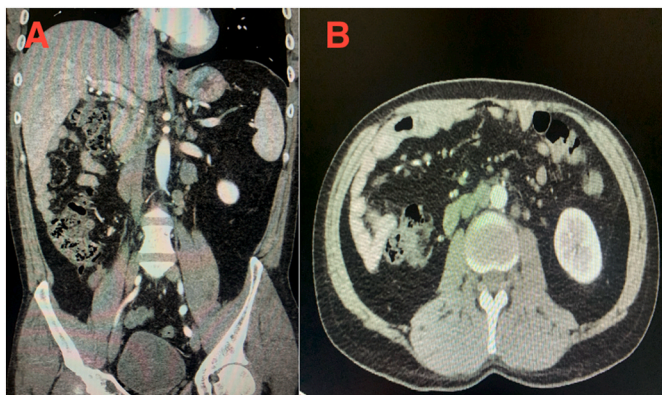


Fig. 1. A; Coronal CT scan demonstrating inter-aortocaval lymphadenopathy (up to 2cm in diameter). B; Axial CT scan demonstrating para-aortic lymphadenopathy (up to 2cm in diameter).

Following the stated procedure, 16 para-aortic, 13 inter-aortal, and two para-caval lymph nodes as well as the right spermatic cord were sent for pathologic analysis. Three peri-aortic and five inter-aortal lymph nodes demonstrated necrosis. All excised lymph nodes were negative for metastatic tumors. Patient exhibited an uncomplicated post-operative course. He was discharged on post-operative day four.

Given the unusual pathology from the RPLND, the initial radical orchiectomy specimen was re-reviewed at a second institution. Immunohistochemistry for this distinct nodule demonstrated expression of PAX8, WT1, and keratin AE1/AE3, consistent with nephroblastoma histology. The final pathological diagnosis was classified as a 60/40 ratio of non-seminomatous teratoma to nephroblastoma (Fig. 2 and 3). The re-review of the retroperitoneal lymph nodes confirmed necrosis with no active tumor.

3. Discussion

This case of a Wilms teratoid primary testicular tumor with retroperitoneal lymph node involvement in a 40-year-old male is a noteworthy addition to the limited number of adult Wilms tumor cases. Adult Wilms tumors, especially primary extrarenal presentations, are exceptionally rare and thus present many diagnostic and therapeutic challenges.

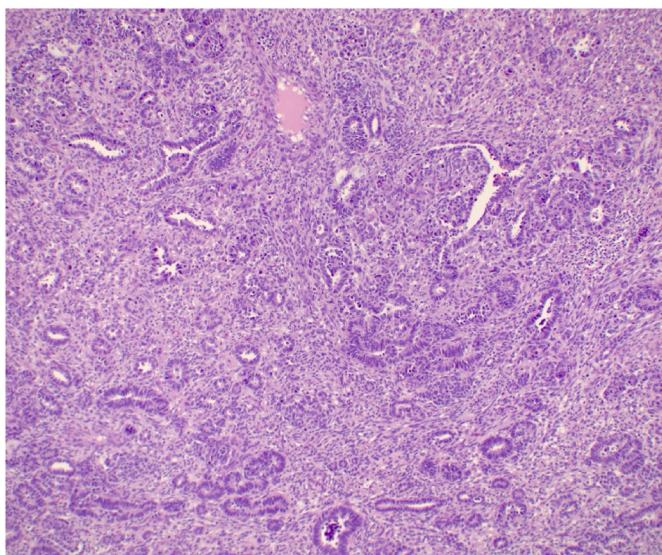


Fig. 2. Immunohistochemical staining of orchiectomy specimen consistent with nephroblastoma histology.

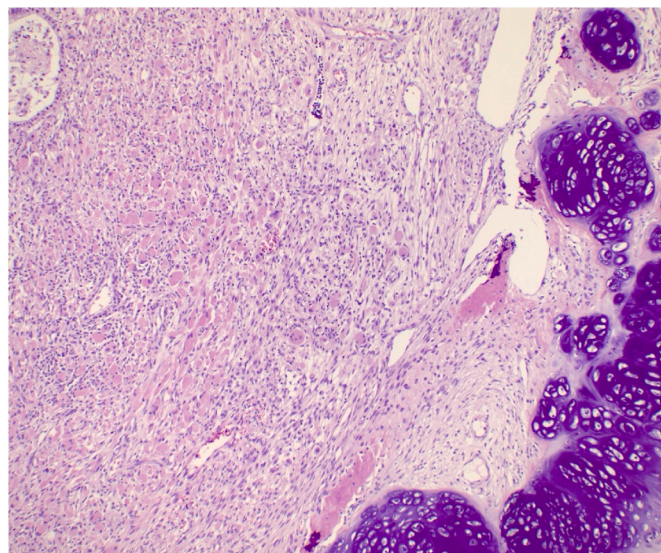


Fig. 3. Immunohistochemical staining of orchiectomy specimen consistent with malignant non-seminomatous teratoma histology.

Similar cases have highlighted the importance of considering Wilms tumor in the differential diagnosis of adult testicular masses, despite its rarity. The unique aspects of this case in addition to the available literature contribute valuable insights into the pathogenesis, diagnosis, and management of adult Wilms tumors, underscoring the need for heightened awareness and careful evaluation in such atypical presentations.

Classic nephroblastoma is derived from abnormally persistent localizations of embryonal intermediate mesoderm typically present in normal kidneys. However, extrarenal nephroblastoma cases, typically seen in younger patients, most likely originate from ectopic nephrogenic blastemal cells deposited in the craniocaudal migration pathway of primitive metanephros cells. Even less common teratoid extrarenal Wilms tumors most likely represent the extremal heterologous element differentiation and not a separate category of malignancy.⁵ These associations show promise for advances to be made in defining the pathophysiology of teratoid extrarenal Wilms tumors as seen in our presented case.

Of the limited reported cases similar to the one seen here, Landin et al. detail a very similar presentation of testicular teratoma with nephroblastoma in a 37-year-old male.² Contrastingly, the patient underwent a left orchiectomy and had an uncomplicated post-operative course without retroperitoneal lymph node involvement. The case presented by Landin et al. in conjunction with our case represent the importance of utilizing the appropriate resources to establish a correct diagnosis in atypical malignant presentations.

4. Conclusion

There is a diminutive volume of available information and reported cases on the exceedingly rare occurrence of teratoid Wilms tumors in adults, especially those that arise extrarenally. The involvement of retroperitoneal lymph nodes in this case represents an even smaller subset of these malignancies and posed a unique therapeutic challenge. The rarity of these malignancies and lack of clear guidelines for management emphasize the importance of having a broad differential in atypical presentations and utilizing immunohistochemical analyses to narrow it down. There is a large gap in knowledge regarding the pathophysiology of extrarenal teratoid Wilms tumors which should be addressed in future histopathological and genetic studies.

Funding

This research did not receive any specific grant from funding agencies in the public, commercial, or not-for-profit sectors.

CRediT authorship contribution statement

Eylon J. Arbel: Visualization, Writing – original draft, Writing – review & editing. **Brian F. Dinerman:** Investigation, Methodology, Supervision, Visualization, Writing – review & editing. **John Rutkowski:** Investigation, Supervision, Writing – review & editing. **Andrés M. Acosta:** Formal analysis, Investigation, Visualization. **Jeffrey Spencer:** Supervision, Writing – review & editing.

Declaration of competing interest

The authors report no conflicts of interest or associated disclosures.

References

1. Taros T, et al. Report of a rare testicular teratoid Wilms Tumor in an adult patient. *Urol Case Rep.* 2022;40, 101894.
2. Landin C, et al. Testicular teratoma with nephroblastoma in an adult - case report and literature review. *Contemp Oncol (Pozn).* 2023;27(1):60–63.
3. Keskin S, et al. The first case of primary testicular germ cell tumor containing nephroblastoma as the only one non-germ cell component. *Jpn J Clin Oncol.* 2011;41(8):1037–1040.
4. Alatassi H, et al. Nephroblastoma arising from primary testicular germ cell tumor: a case report and literature review. *Case Rep Pathol.* 2016;2016, 7318672.
5. D'Hooghe E, Mifsud W, Vujanic GM. "Teratoid" Wilms tumor: the extreme end of heterologous element differentiation, not a separate entity. *Am J Surg Pathol.* 2019;43(11):1583–1590.