



Importance of Vertical Dimension in Facial Esthetics

N. SUPONPUN DDS and JOHN A. LEVON DDS, MS
Indiana University School of Dentistry, Indianapolis, Indiana, USA

ABSTRACT

The objective is to discuss the importance in the determination of the vertical dimension of occlusion in prosthodontic treatment.

Case I: A 43 year old Caucasian female presented with chief complaints of both poor function and esthetics. The medical history revealed a history of cirrhosis, Hepatitis B and depression. In 2011, she presented edentulous with some lower impacted teeth. Three sets of complete dentures were fabricated and delivered. These dentures caused her various problems including complaint of thick and overextended borders, unacceptable esthetics and ear pain. Due to lack of posterior inter-occlusal space, vertical dimension was increased so much that the resulting dentures were unsatisfying esthetically and wearing them resulted in auricular discomfort.

Case II: A 75 year old Caucasian male presented with chief complaints of a broken denture, joint discomfort and esthetic concern. The medical history revealed a history of angina pectoris, hypertension and depression. He continuously complained about his joint pain and had numerous episodes of a broken prosthesis since 2011. Repairs were done several times but they did not eliminate his problem. In 2013, he was diagnosed with a loss of vertical dimension. When his vertical was reestablished at its proper position, his joint discomfort was resolved and his esthetics was greatly improved.

Conclusion: Determination of the proper vertical dimension of occlusion is a crucial factor in the overall success of a restorative case. For correct diagnosis and treatment, the restorative dentist should use past dental history, facial profile, past photographs, provisional prosthesis and mounted diagnostic casts.

BACKGROUND

Nearly 80 years ago, Niswonger⁵ first introduced the concept of interocclusal clearance or freeway space. In 1934 he suggested using the tactile muscular sense of the patient's lips to determine the amount of freeway space; however, some dentists found this was difficult to record in a consistent manner.

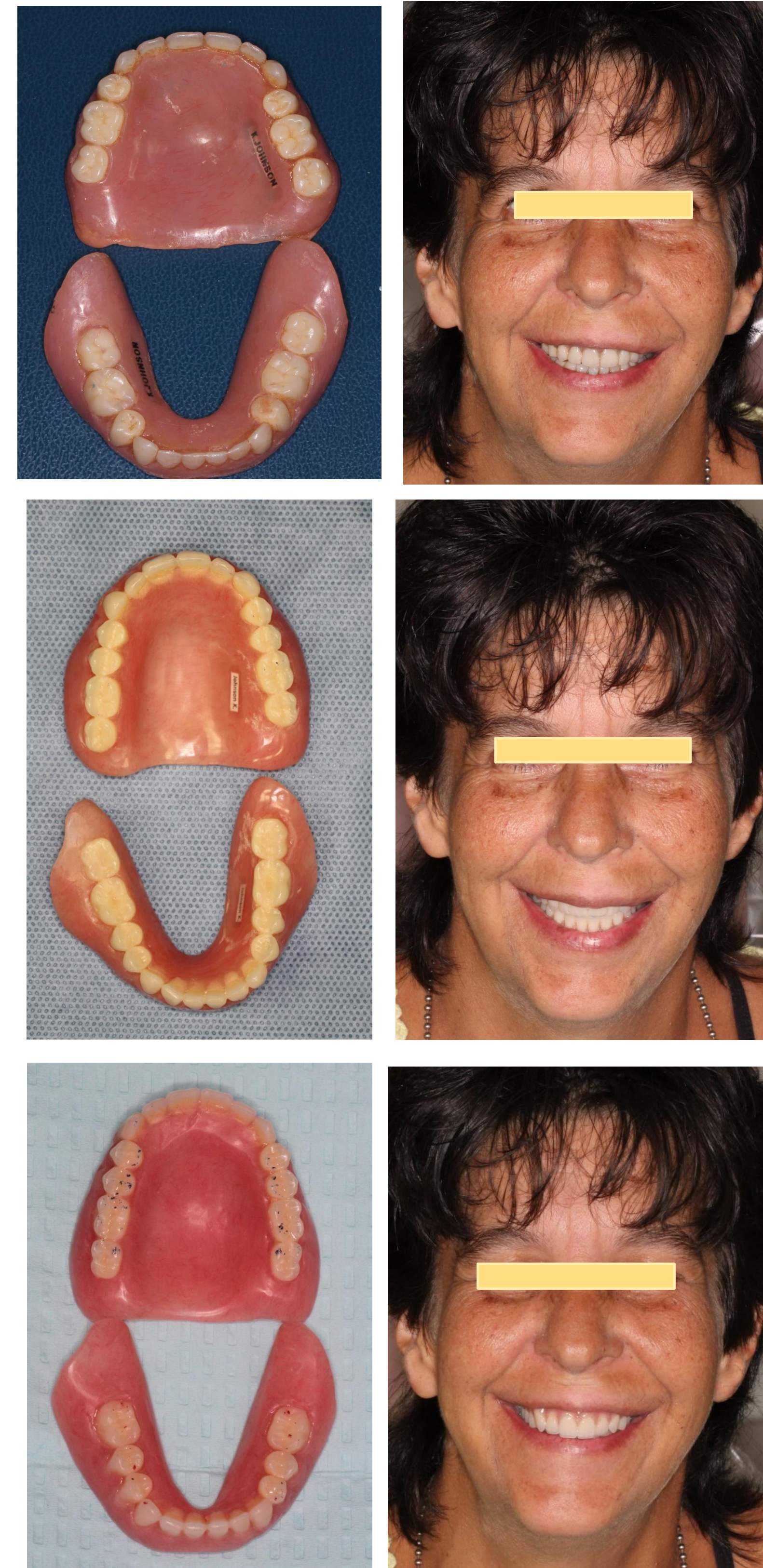
Twenty years later, Silverman⁶ and Pound⁷ recommended the use of the closet speaking space. They looked for the distance between upper and lower anterior teeth to be around 0.5 to 1.0 mm when sibilant sounds were pronounced. In 1965, the open rest position was introduced by Doughlas⁸. Here, we want the position of lower first premolar to be located at the corner of the mouth. Another technique, utilizes the *labial "M" sound*⁹ since "M" can be said without the use of teeth. Still others have suggested the use of "biting force" or facial appearance in the determination of proper vertical dimension⁹.

Other techniques have been suggested such as cephalometric¹⁰ and neuromuscular¹¹; however, they are rarely clinically utilized due to their complexity and unreliability.

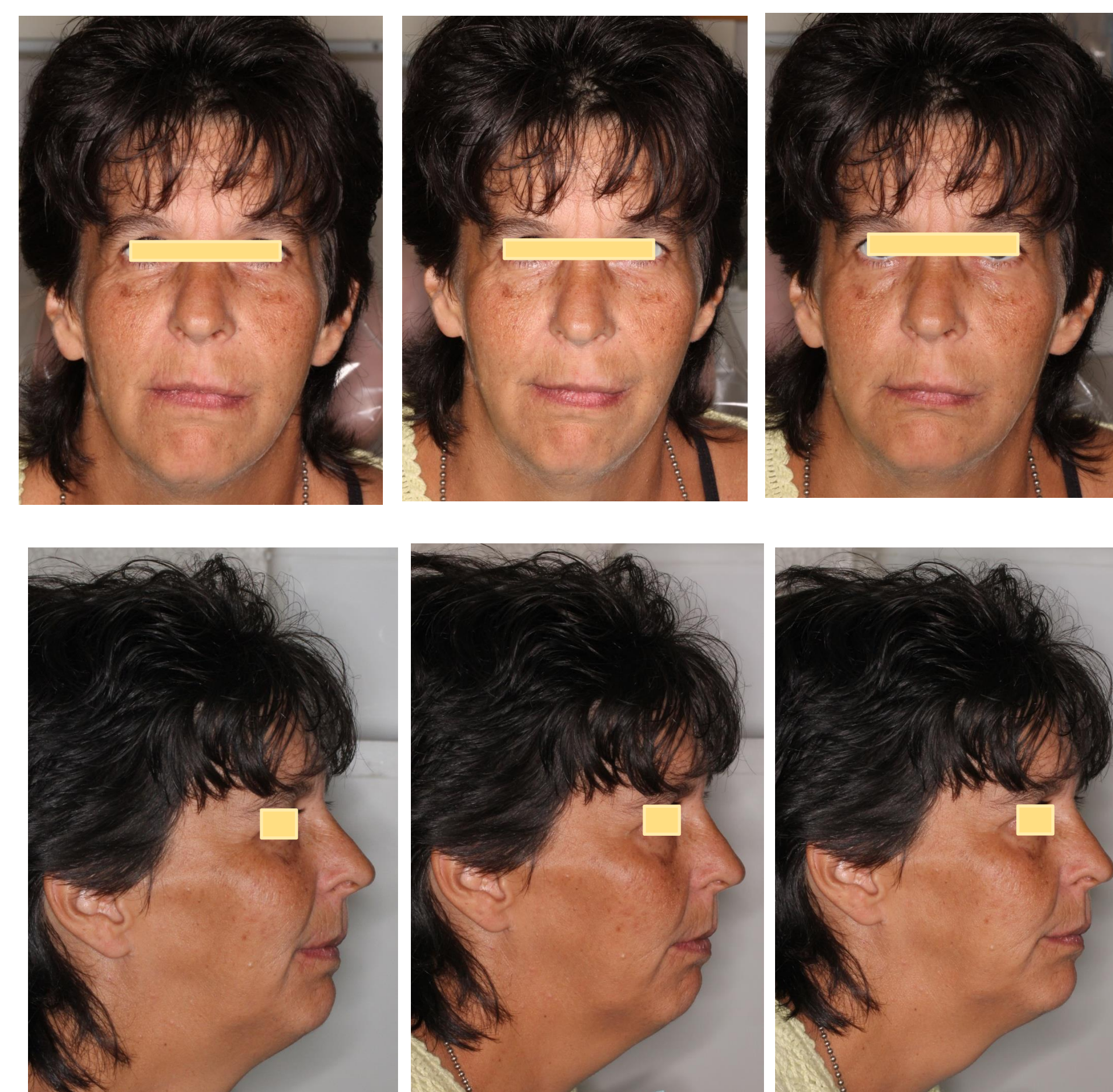No single technique has been proven to be the best for achieving a suitable vertical dimension. Often times, the use of several techniques in combination proves to work at for the best. Patient acceptance varies on a case by case basis.

Case Report I

Comparison of Various Vertical Dimensions

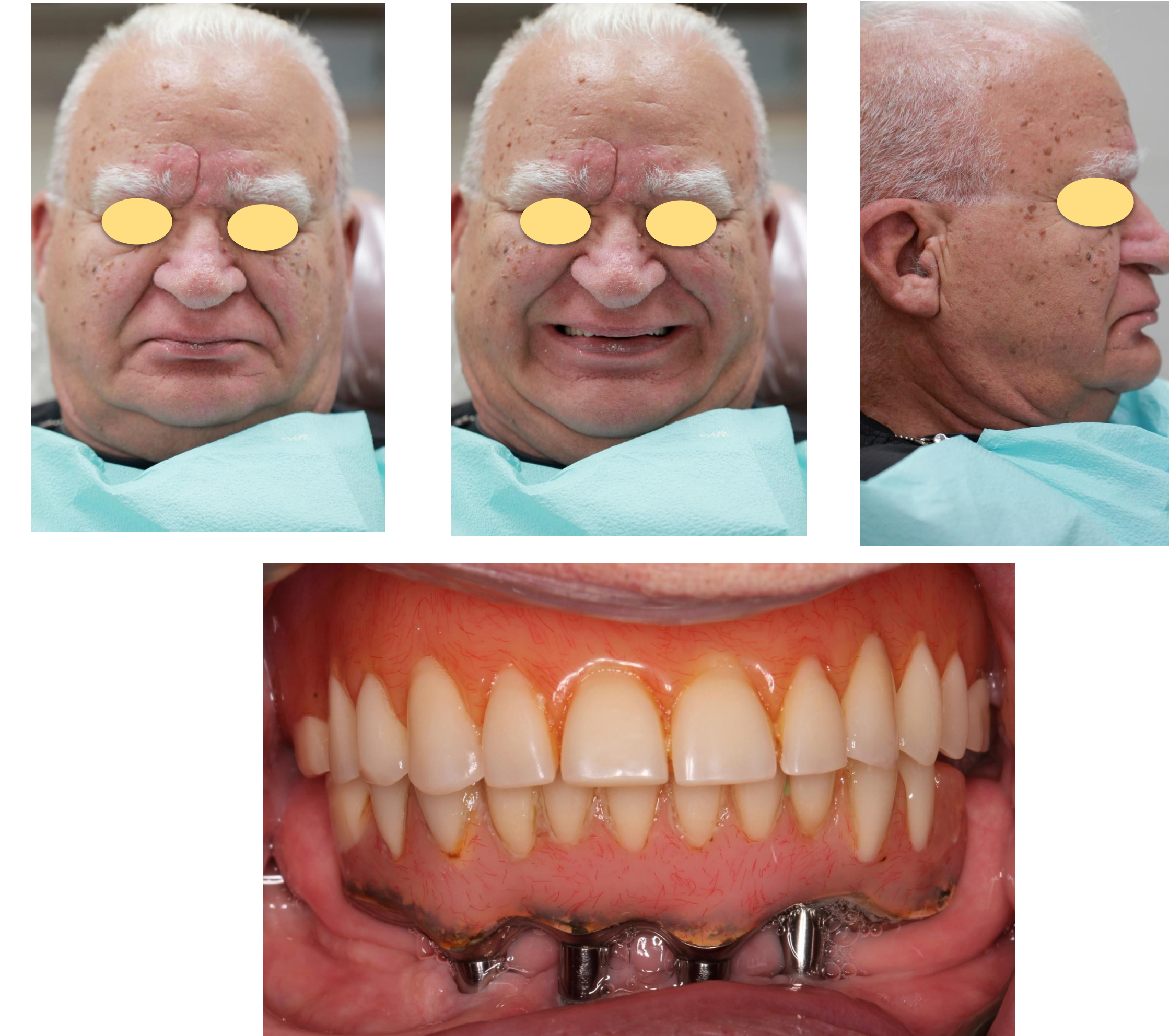


Comparison of Extraoral Profiles

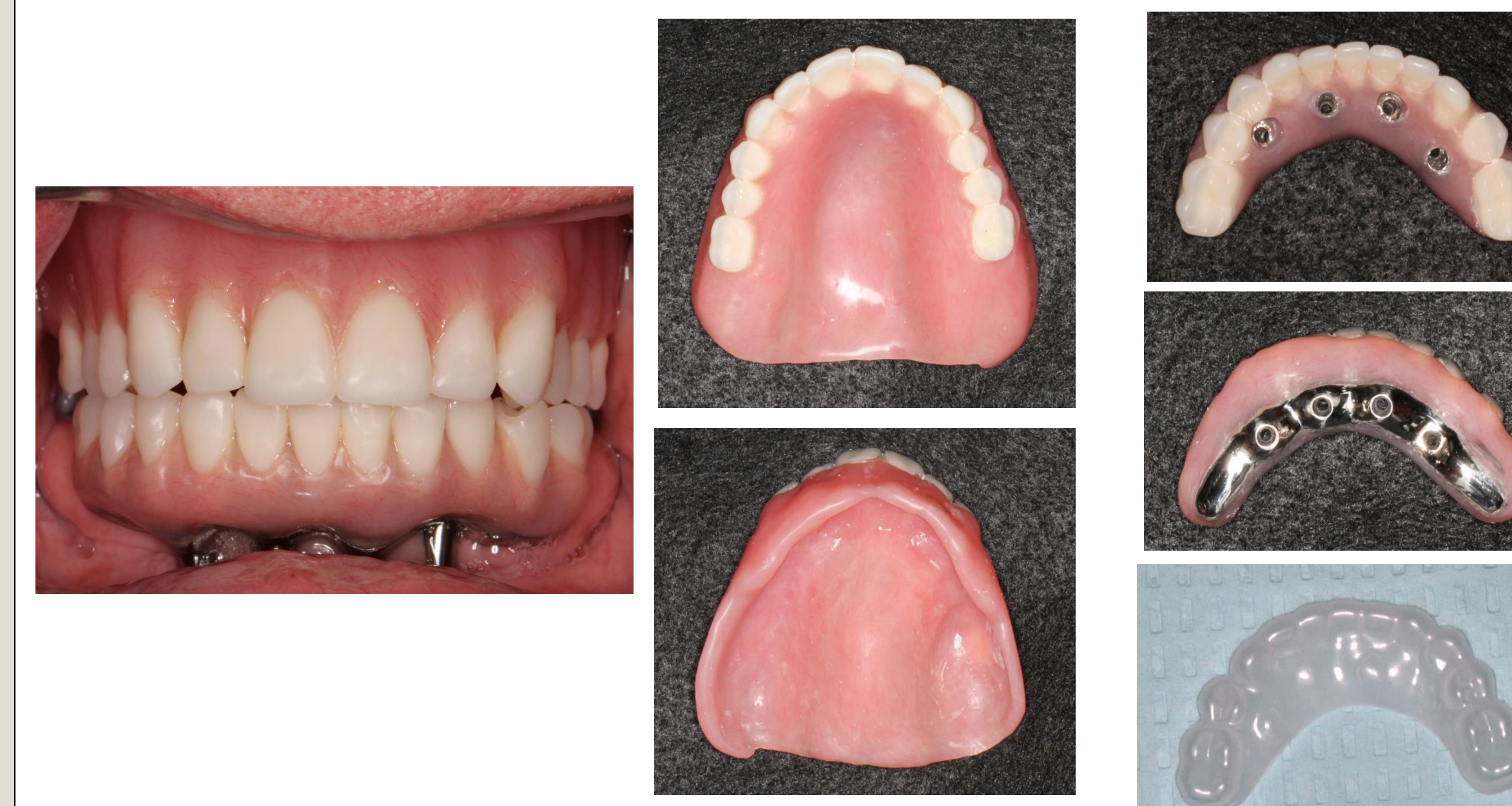


Case Report II

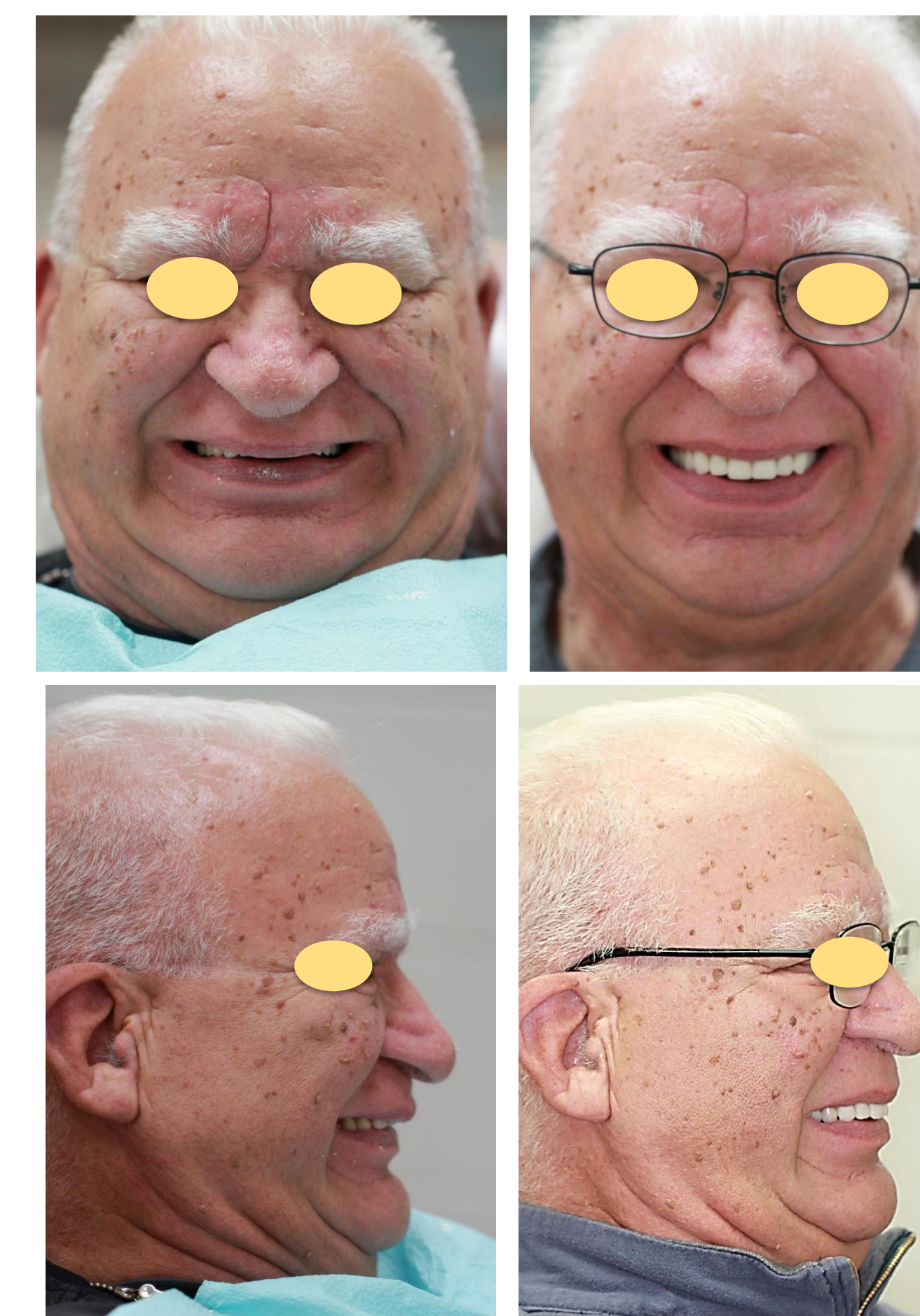
Preoperative Photographs



Postoperative Photographs



Comparison of Various Vertical Dimensions



CONCLUSION

- A few warning signs of an improper vertical dimension of occlusion include: repeated broken prosthesis, auricular pain, soreness/fatigue of masticatory muscles or angular cheilitis.
- Often times dentist must utilize a combination of techniques when determining a suitable vertical dimension of occlusion.
- The presence of some anatomical limitation such as short upper lips or muscular hypo or hyper activity may complicate the determination of vertical dimension.
- Many times, one or more provisional prosthesis must be used before determination of a suitable vertical dimension of occlusion.

REFERENCES

1. Gross MD. Occlusion in implant dentistry. A review of the literature of prosthetic determinants and current concepts. *Aust Dent J* 2008;53(1):60-68
2. Discacciati JA, Lemos de Souza E, Vasconcellos WA, Barros Vde M. Increased vertical dimension of occlusion : signs, symptoms, diagnosis, treatment and options. *J Contemp Dent Pract* 2013;14(1):123-128
3. Chander NG, Venkat R. An appraisal on increasing the occlusal vertical dimension in full occlusal rehabilitation and its outcome. *J Indian Prost* 2011;11(2):77-81
4. Mays KA. Reestablishing occlusal vertical dimension using a diagnostic treatment prosthesis in the edentulous patient: A clinical study. *J Prost* 2003;12(1):30-36
5. Niswonger ME. The rest position of the mandible and the centric relation. *JADA* 1934;15:72-1582
6. Silverman MM. The speaking method in measuring vertical dimension. *JPD*.1952;3(2):193-199
7. Pound E. The mandibular movements of speech and their seven related values. *JPD* 1966;16(5):835-843
8. Douglas JR and Mariato FR. "Open rest" a new concept in the selection of the vertical dimension of occlusion. *JPD* 1965;15(5):850-856
9. Turrell AJ; Clinical assessment of vertical dimension. *JPD* 1972;28(3):238-246
10. Atwood DA. A Cephalometric study of the clinical rest position of the mandible. *JPD* 1956;16(4):504-518
11. Lytle RB. Vertical relation of occlusion by the patient's neuromuscular perception. *JPD* 1964;14(1):12-21

ACKNOWLEDGEMENT

I would like to thank Dr. Levon and Dr. Margiotti for always providing genuine and useful suggestion while including compassionate encouragement both in the clinic and lab.