HHS Public Access

Author manuscript

Anaerobe. Author manuscript; available in PMC 2022 December 01.

Published in final edited form as:

Anaerobe. 2022 June ; 75: 102520. doi:10.1016/j.anaerobe.2022.102520.

Persistent bacteremia and psoas abscess caused by a lethal toxin-deficient *Paeniclostridium sordellii*

Cara D. Varley[a,f,*], **Lisa M. Rogers**[b], **Beverly REA. Dixon**[b], **Sarah C. Bernard**[c], **D. Borden Lacy**[c,d], **Emilio Sulpizio**[e], **David M. Aronoff**[b,c], **John M. Townes**[a]

[a]Department of Medicine, Division of Infectious Diseases, Oregon Health & Science University, Portland, OR, 97239, USA

[b]Division of Infectious Diseases, Department of Medicine, Vanderbilt University Medical Center, Nashville, TN, 37232, USA

[c]Department of Pathology, Microbiology and Immunology, Vanderbilt University School of Medicine, Nashville, TN, 37232, USA

[d]The Veterans Affairs Tennessee Valley Healthcare System, Nashville, TN, 37232, USA

[e]Department of Medicine, Oregon Health & Science University, Portland, OR, 97239, USA

[f]School of Public Health, Oregon Health & Science University-Portland State University, Portland, OR, 97239, USA

Abstract

We present a case of persistent bacteremia and psoas abscess from *Paeniclostridium sordellii* without severe symptoms or the classically associated toxic shock syndrome. Further laboratory evaluation demonstrated that the *Paeniclostridium sordellii* isolate lacked the lethal toxin gene and there was no cytotoxicity to exposed Vero cells.

Keywords

Clostridium sordellii ; *Paeniclostridium sordellii* ; Bacteremia; Gram-positive bacilli; *Clostridium species* ; Bacterial toxin

[*]Corresponding author. OHSU Division of Infectious Diseases, 3181 SW Sam Jackson Park Road L457, Portland, OR 97239-3098, USA. varleyc@ohsu.edu (C.D. Varley).

Contribution of authors

Cara D Varley: wrote the manuscript, literature review, oversaw manuscript edits, proof reading.

Lisa M Rogers, Beverly REA Dixon, Sarah C Bernard, D Borden Lacy: Vero cell Assay, PCR for lethal toxin gene, assistance in writing manuscript, proof reading.

Emilio Sulpizio: assistance in writing description of the case portion of the manuscript.

David M Aronoff: design of experiments, data analysis, assistance in writing manuscript, proof reading.

John M Townes: assistance in writing manuscript, proof reading, supervised the project.

Declaration of competing interest

The authors declare that they have no known competing financial interests or personal relationships that could have appeared to influence the work reported in this paper.

1. Introduction

Paeniclostridium sordellii causes rare but severe infections with high mortality associated with a distinct toxic shock syndrome. We describe a case of persistent bacteremia and psoas abscess from *Paeniclostridium sordellii*.

2. Description of the case

A 63-year-old man with intravenous drug, alcohol use disorders, untreated hepatitis C with cirrhosis presented to hospital in 2019 with right shoulder pain and back spasms without inciting injury. He reported one week of fever, chills, and cough, but denied abdominal pain, dysuria, hematuria, headache, sore throat, chest pain or dyspnea. He was afebrile and normotensive with a tachycardia that resolved after intravenous (IV) fluid administration.

Initial complete blood count demonstrated a leukocytosis (15×10^3 cells/mm^3, 85% neutrophils), thrombocytopenia (51×10^3 cells/mm^3) and normal hemoglobin (16.8g/dL). Aspartate aminotransferase, total bilirubin, and alkaline phosphatase were elevated (139U/L, 4.2mg/dL, 238U/L respectively), but the metabolic panel was otherwise normal. Urine toxicology screen was positive for methamphetamine and opiates. Serologic tests for Hepatitis B and HIV were negative. Westergren sedimentation rate was normal (19mm/hr). Abdominal ultrasound showed cirrhosis and an indeterminate 2.4cm hypoechoic focus in the right hepatic lobe without ascites, biliary ductal dilation or gallbladder abnormality. Chest radiograph revealed a vague right lower lobe infiltrate. Shoulder radiograph was normal. Serum procalcitonin was elevated (2.15ng/mL) and nasal pharyngeal swab specimen was negative for respiratory viruses, *Bordetella pertussis*, *Chlamydia pneumoniae* and *Mycoplasma pneumoniae* by multiplex polymerase chain reaction (PCR). A thoraco-lumbar spine magnetic resonance imaging with contrast showed multi-level spondylosis and degenerative disc disease without epidural abscess, discitis, or osteomyelitis

He was admitted with a diagnosis of community acquired pneumonia and prescribed levofloxacin. Approximately 12 hours later, blood cultures obtained before antibiotic administration yielded Gram-positive bacilli in anaerobic bottles. Vancomycin was added. He continued to have back pain, although without fever, hypotension, respiratory complaints, or neurologic abnormalities. On hospital day (HD) 4, the Gram-positive bacilli were identified as *Clostridium perfringens* and *Paeniclostridium sordellii* (formerly *Clostridium sordellii*), follow-up blood cultures yielded Gram-variable bacilli. Piperacillin/tazobactam was added, then changed to ampicillin/sulbactam when the Gram-variable bacilli were also identified as *C. perfringens* and *P. sordellii*. No valve vegetations were seen on transthoracic echocardiogram. A computerized tomography (CT) of abdomen and pelvis with IV contrast revealed an extensive multi-loculated, rim-enhancing fluid collection with foci of gas in the right psoas muscle, a contiguous pleural effusion, and two hypo-enhancing lesions in the liver (Figs. 1 and 2). Catheter drainage of the abscess was unsuccessful. Blood cultures on HD11 again yielded *P. sordellii*, but not *C. perfringens*. He was transferred to Oregon Health & Science University for surgical management.

During admission, he remained afebrile and showed no overt signs of sepsis. He had moderate back and chest pain. Multiphase CT of liver confirmed hepatocellular carcinoma with two LI-RADS5 lesions. Ampicillin-sulbactam was changed to penicillin G and metronidazole when blood cultures again yielded *P. sordellii* on HD12. The psoas abscess and associated pleural effusion were adequately drained with cultures positive for *Clostridium* species, not *C. perfringens*. Further isolate identification was not possible due to poor growth in the laboratory. Following source control, he cleared his blood cultures on HD17 and was discharged to complete a 6-week course of continuous penicillin G without recurrence of infection. Because our patient had 16 days of *P. sordellii* bacteremia without signs of sepsis, we suspected a non-toxigenic strain of *P. sordellii* and pursued evaluation for toxin production.

3. Laboratory methods

3.1. Bacterial strains and growth conditions

P. sordellii ATCC9714 was obtained from the American Type Culture Collection (ATCC; Manassas, VA). The clinical strain ORE2019 was isolated from blood. Both strains were grown in Reinforced Clostridial Media (RCM) (BD Biosciences, San Jose, CA) for 48 hr at 37 °C in an anaerobic chamber (Coy Laboratories, Grass Lake, MI).

3.2. PCR

Genomic DNA (gDNA) was extracted from *P. sordellii* cultures using the protocol for bacterial cells (protocol#3) in the Easy-DNA Kit (Invitrogen, Carlsbad, CA). Subsequently, 500ng of gDNA, GoTaq Green Master Mix (Promega, Madison, WI) and the appropriate primers were used to conduct PCR for *tcsL*, which encodes for the lethal toxin (TcsL). Specifically, the Taq-based primer/probe sequences were: tcsL_F1 TGCCTCAAGATGACTTGGTATT (sense), tcsL_R1 CATCAGTTAAGGTATGGCCTGA (antisense), and ACCACCTTCAGCTCTCCAGATTTCAC (FAM; antisense probe), which were designed using the Integrated DNA Technologies PrimerQuest Tool (IDT; Coralville, IA) based on the genome sequence of *P. sordellii* strain AIP82 cytotoxin L (*tcsL*) gene sequence (GenBank KF726114.1). PCR was performed on a MJ Mini Thermal Cycler (Bio-Rad, Hercules, CA) with the following protocol: 94 °C for 10 minutes (initial denaturation); then 35 cycles of 95 °C for 30 seconds, 55 °C for 30 seconds, and 72 °C for 90 seconds; ending with a final extension at 72 °C for 5 minutes. A TaqMan Gene Expression Assay for *16S_rRNA* gene (Ba04230899_s1; Invitrogen) was used as an internal control. All PCR amplicons were visualized using electrophoresis on 2% agarose gel and amplicon size was estimated using 1kb DNA ladder (Thermo Scientific, Waltham, MA). The expected amplicon length for *tcsL is* 114bp, while amplicon size for *16S_rRNA* is 136bp. Nuclease-free water was used for the 'no template' control (NTC).

3.3. Vero cell assay

African green monkey Vero cells (obtained from ATCC) were grown in DMEM with 10% fetal bovine serum, plated in a 96-well plate at a density of 15,000 cells per well, and left to culture for 24 hours at which point they reached 100% confluency. Supernatants from 48-hour cultures of either vegetative *P. sordellii* strain ATCC9714 or strain ORE2019 were

collected, sterile filtered, and stored at −80 °C until they were serially diluted and placed onto 100% confluent Vero cells for experimentation. Recombinant TcsL was purified as previously described and used as a positive control at 50pM [1]. *P. sordellii* supernatants or purified TcsL were left on the Vero cells for 24 hours, at which point images were taken to look for cell rounding.

4. Discussion

P. sordellii is a gram-positive, spore-forming, obligate anaerobe found in the intestines of many animals and soil [2]. Intestinal (0.5%) and vaginal (0.5–10% of healthy women) colonization has been reported in humans [2,3]. Infections are rare but severe with a high mortality, often occurring following childbirth or medical abortion, trauma, cadaveric grafts or in people who inject drugs. A rapid and high case fatality from 44% to 100% is reported in the literature [2,4]. Necrotizing infections develop at the site of inoculation with subsequent toxic shock syndrome (TSS). TSS from *P. sordellii* is distinct with initial symptoms of nausea, vomiting and weakness with brisk development of a pronounced leukocytosis or leukemoid reaction, refractory hypotension, tachycardia, hemoconcentration, absence of fever and profound capillary leak [5,6]. In a case series of nine *P. sordellii* infections in people who use black tar heroin, mortality was statistically significantly associated with higher median hemoglobin levels (21.6% vs. 14.0%) and leukocytosis (54.3 vs. 23.2×10^3 cells/mm3), in addition to lower body temperature (35.6 vs 36.4 °C) [4]. Additional work by Aldape et al. identified leukocytosis as strongly associated with fatal outcomes [2].

P. sordellii can produce up to seven exotoxins with two large glycosylating toxins, hemorrhagic toxin (TcsH) and lethal toxin (TcsL), thought to be responsible for the organism's virulence and cell proliferation resulting in the observed leukemoid reaction [2,5,7,8]. These toxins are homologous to *Clostridioides difficile* toxins A and B, modifying Rho and Ras GTPase signaling, which alters apoptosis, cell cycle control and actin leading to loss of structural integrity [2,5,9]. Cytotoxic activity is thought to be amplified by low pH with up to a 5-fold increase in acidic environments, which correlates with common infectious sites such as the vagina or necrotic wounds [2,10,11]. Presence of TcsL is thought to be related to clinical severity and TSS, however limited published data are available on infections with confirmed non-toxigenic strains of *P. sordellii*. Two case reports, one patient with a polymicrobial bacteremia secondary to cholangitis and another with endometritis, who survived and did not develop TSS have been published. Further analysis of the isolates from both patients demonstrated lack of the *tcsL* gene, and they were not lethal when injected into rodents [7,12].

Using the published genome sequence of *P. sordellii* strain AIP82 cytotoxin L, we sought to determine if the clinical isolate of *P. sordellii* ORE2019 lacked the *tcsL* gene, compared to the ATCC9714 strain known to express *tcsL*. We discovered that the ORE2019 strain does in fact lack the *tcsL* gene as indicated by the absence of the 114bp amplicon (Fig. 3A) but maintains the presence of the *16S rRNA* gene at the expected amplicon size of 136bp (Fig. 3B). The ATCC9714 reference strain shows the presence of the *tcsL* gene as well as the *16S rRNA* gene, while the 'no template' control shows lack of both amplicon bands.

Using a Vero cell-rounding assay to test for TcsL-mediated cytotoxicity [7], we did not observe cell rounding with bacterial culture supernatants obtained from the ORE2019 strain, indicating a lack of cytotoxicity. Cell rounding was observed with supernatants obtained from the control ATCC9714 strain as well as purified recombinant TcsL (Fig. 4A–D).

In summary, we present a case of persistent bacteremia and psoas abscess with a lethal toxin-deficient strain of *P. sordellii*. This patient did not develop TSS and clinically did well despite over two weeks of positive blood cultures. This case provides further evidence that TcsL is a critical virulence factor associated with severity of illness due to *P. sordellii* infection.

Funding

No funding was received for this work.

References

[1]. Craven R.a.D.B.L., Clostridium sordellii lethal-toxin autoprocessing and membrane localization activities drive GTPase glucosylation and profiles in endothelial cells, mSphere 1 (2016) 1.

[2]. Aldape MJ, Bryant AE, and Stevens DL, Clostridium sordellii infection: epidemiology, clinical findings, and current perspectives on diagnosis and treatment, Clin. Infect. Dis. 43(11): p. 1436–1446.

[3]. Chong E, et al. , Vaginal and rectal Clostridium sordellii and Clostridium perfringens presence among women in the United States, Obstet. Gynecol 127 (2) (2016) 360–368. [PubMed: 26942366]

[4]. Kimura AC, et al. , Outbreak of necrotizing fasciitis due to Clostridium sordellii among black-tar heroin users, Clin. Infect. Dis. 38(9): p. e87–91. [PubMed: 15127359]

[5]. Aronoff DM and Ballard JD, Clostridium sordellii toxic shock syndrome, Lancet Infect. Dis. 9(12): p. 725–726. [PubMed: 19926032]

[6]. Guzzetta M, Williamson A, Duong S, Clostridium sordellii as an uncommon cause of fatal toxic shock syndrome in a postpartum 33-year-old asian woman, and the need for antepartum screening for this clostridia species in the general female population, Lab. Med 47 (3) (2016) 251–254. [PubMed: 27371657]

[7]. Walk ST, et al. , Non-toxigenic Clostridium sordellii: clinical and microbiological features of a case of cholangitis-associated bacteremia, Anaerobe. 17(5): p. 252–256. [PubMed: 21726656]

[8]. Aldape MJ, et al. , The leukemoid reaction in Clostridium sordellii infection: neuraminidase induction of promyelocytic cell proliferation, J. Infect. Dis 195 (12) (2007) 1838–1845. [PubMed: 17492600]

[9]. Popoff MR, Clostridium difficile and Clostridium sordellii toxins, proinflammatory versus anti-inflammatory response, Toxicon : official journal of the International Society on Toxinology 149 (2018) 54–64. [PubMed: 29146177]

[10]. Qa'Dan M, Spyres LM, Ballard JD, pH-enhanced cytopathic effects of Clostridium sordellii lethal toxin, Infect. Immun 69 (9) (2001) 5487–5493. [PubMed: 11500421]

[11]. Ramirez N, Abel-Santos E, Requirements for germination of Clostridium sordellii spores in vitro, J. Bacteriol 192 (2) (2010) 418–425. [PubMed: 19915025]

[12]. Hao Y, et al. , Lethal toxin is a critical determinant of rapid mortality in rodent models of Clostridium sordellii endometritis, Anaerobe. 16(2): p. 155–160. [PubMed: 19527792]

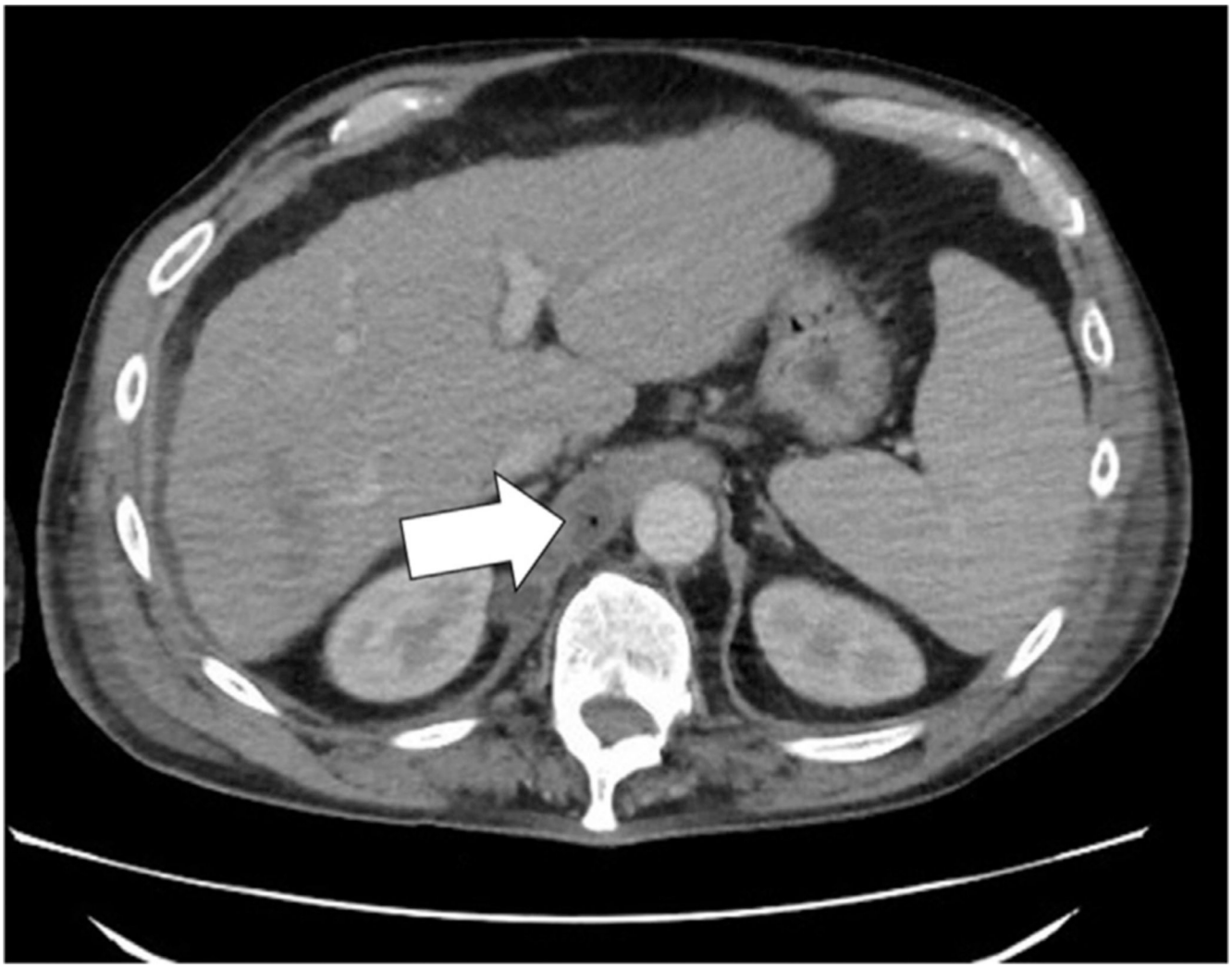

Fig. 1.

Computerized tomography of the chest, abdomen and pelvis with intravenous contrast: Rim-enhancing air and fluid collection consistent with an abscess. The collection tracks superiorly and extends behind the right crus of the diaphragm.

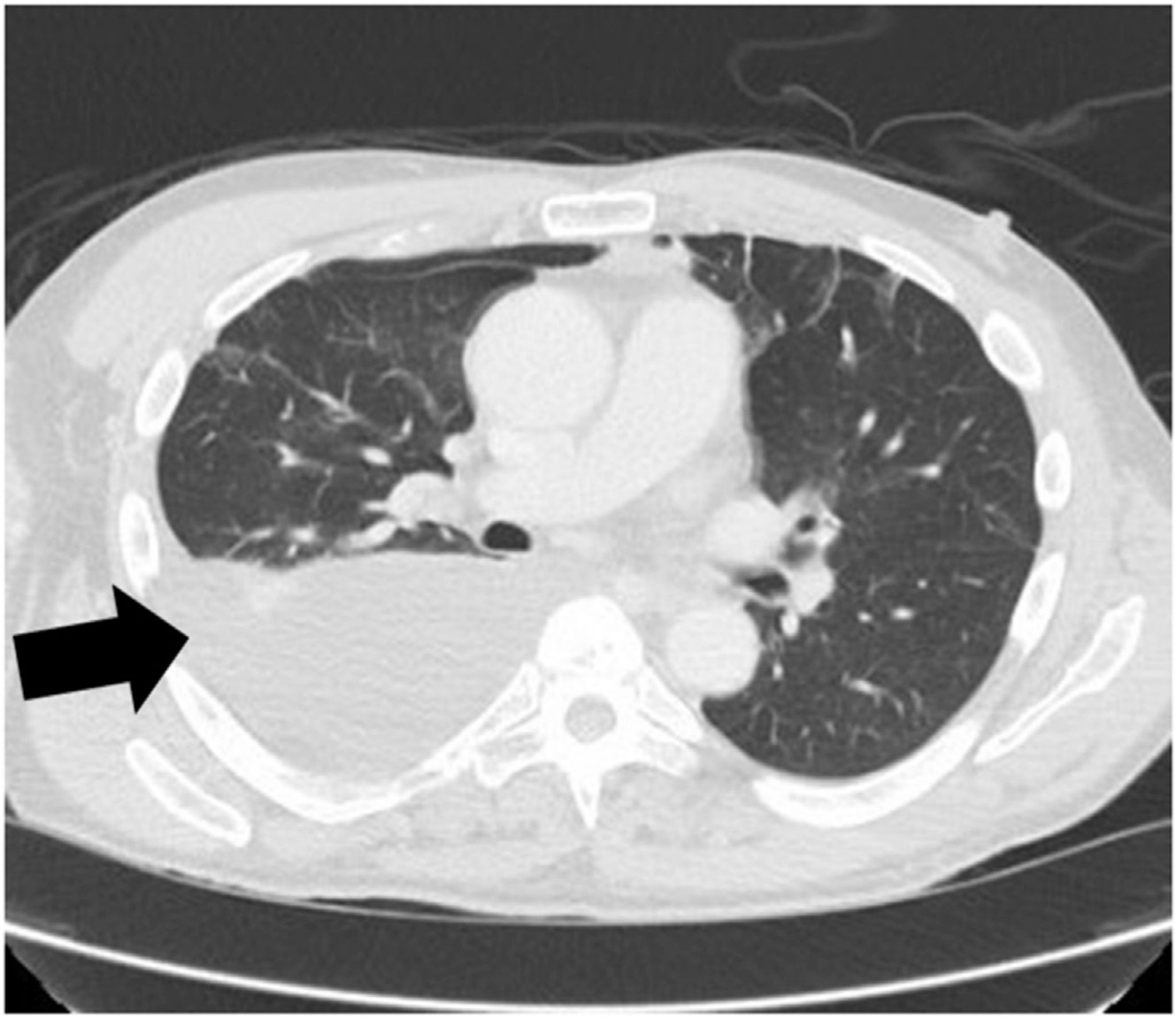

Fig. 2.

Computerized tomography of the chest, abdomen and pelvis with intravenous contrast: Large right pleural effusion without loculation or pleural thickening.

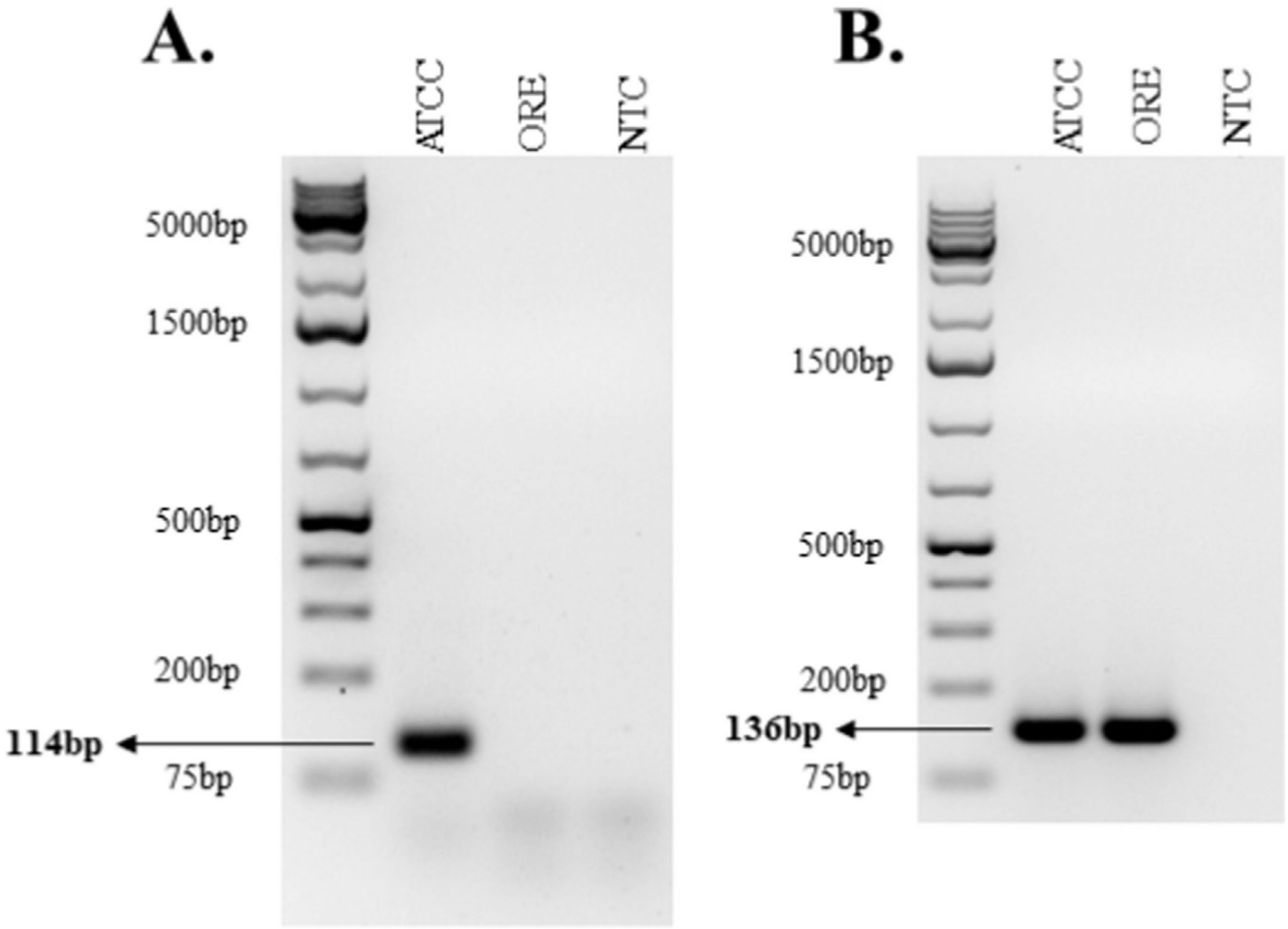

Fig. 3. *P. sordellii* clinical strain ORE2019 lacks the *tcsL* gene.

Genomic DNA (500 ng) was used for PCR amplification of the *tcsL* gene (A) or *16S_rRNA* (B), visualized here on 2% agarose. The ATCC9714 *P. sordellii* strain shows presence of both the 114 bp amplicon for *tcsL* and the 136 bp amplicon for *16S_rRNA*, while the ORE2019 *P. sordellii* strain only shows the *16S_rRNA* amplicon. ATCC = ATCC9714 strain; ORE = ORE2019 strain; NTC = no template control.

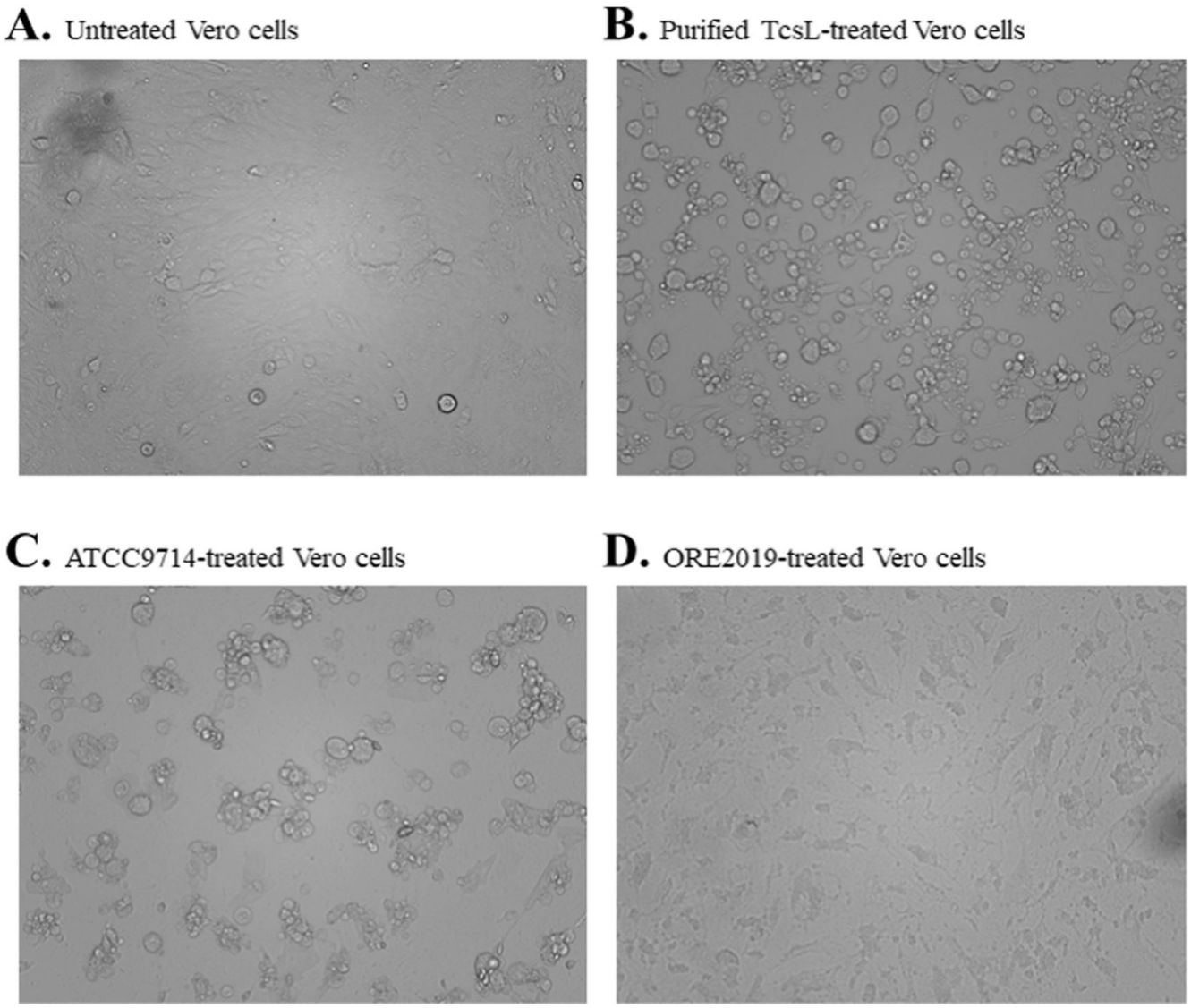

Fig. 4. *P. sordellii* clinical strain ORE2019 is unable to round Vero cells.

African green monkey (Vero) cells were used in a cell-rounding assay to test for TcsL-mediated cytotoxicity using serially-diluted culture supernatants from 48 hr vegetative *P. sordellii* cultures. Untreated Vero cells show no cell rounding (A), while Vero cells treated with 50 pM recombinant purified TcsL do show cell rounding, a marker of cytotoxicity (B). Vero cells treated with ATCC9714 culture supernatant resulted in cell rounding (C), while ORE2019 supernatant did not result in cell rounding (D). Mag = 10x.