HHS Public Access

Author manuscript

Curr Osteoporos Rep. Author manuscript; available in PMC 2021 June 01.

Published in final edited form as:

Curr Osteoporos Rep. 2020 June ; 18(3): 242–246. doi:10.1007/s11914-020-00580-9.

Kidney Disease and Bone – Changing the way we look at skeletal health.

Matthew R. Allen[1,2,3,4], **Elizabeth A. Swallow**[1], **Corinne E. Metzger**[1]

[1]Department of Anatomy and Cell Biology, Indiana University School of Medicine, Indianapolis IN, United States

[2]Department of Medicine – Division of Nephrology, Indiana University School of Medicine, Indianapolis IN, United States.

[3]Department of Biomedical Engineering, Indiana University Purdue University of Indianapolis, Indianapolis, IN, United States.

[4]Roudebush Veterans Administration Medical Center, Indianapolis, IN, United States.

Abstract

Purpose of review: Kidney disease imparts profound skeletal changes, and unlike many other skeletal diseases, cortical bone is predominantly impacted. Significant advances in medical imaging have led to our ability to now obtain high resolution three-dimensional views of cortical bone. This paper overviews recent work focused on cortical bone imaging, specifically cortical porosity, in kidney disease.

Recent findings: Although a number of clinical papers have used high-resolution imaging to assess cortical bone porosity, the most impactful work involves longitudinal study designs that have assessed cortical porosity changes over time. These latter studies demonstrate dramatic increases in cortical porosity in untreated individuals and a lack of clear efficacy in reversing porosity with treatment (although data are limited).

Summary: Those papers providing longitudinal assessment, both clinical and pre-clinical reveal powerful data about cortical porosity and provide a foundation upon which future studies can build.

Keywords

Imaging; cortical porosity; CKD-MBD; HR-pQCT; cortical bone

Send Correspondence to: Matthew R. Allen, PhD, Dept. of Anatomy and Cell Biology, MS 5035, Indiana University School of Medicine, 635 Barnhill Dr., Indianapolis, IN 46202, matallen@iu.edu.

Compliance with Ethical Standards:

MRA, EAS and CEM declare no conflict of interest. This article does not contain any original studies with human or animal subjects performed by any of the authors.

Introduction

The gold-standard approach for clinical assessment of skeletal health is densitometry – historically in the form of dual-energy x-ray absorptiometry (DXA). DXA has a number of advantages as a tool for skeletal assessment including the wide-spread availability of the technology, large normative databases, ease/speed for the patients, and generally strong predictive nature for fracture (on a population basis). One limitation of DXA is that it represents a projection integration of the bone, thus it does not capture the three-dimensional geometry that has come to be appreciated as playing a role in the bones' mechanical competence and risk of fracture. The two-dimensional nature of DXA also prohibits clear differentiation of changes to cortical and trabecular bone.

Kidney injury/disease leads to rapid and prominent effects on the skeleton. There are numerous pathophysiological pathways through which disrupted kidney function can manifest effects on the bone. When kidney function decline is severe enough to change mineral metabolism, kidney dysfunction results in alterations in the homeostatic regulations of bone cells. If this involves hyperparathyroidism, the effects on bone become dramatic and, in some ways, unique from other situations of bone loss. Most notable is the dramatic loss of cortical bone, manifested primarily through an increase in cortical porosity. The importance of cortical bone and the potential implications of cortical bone loss in kidney disease patients has long been appreciated, highlighted in a perspective article 20 years ago by Michael Parfitt where he challenged the idea of using DXA imaging to assess bone in the setting of renal disease [1]. Yet at the time, the alternative to DXA was radiography and although such imaging is able to provide useful information about cortical bone, its use was limited.

Advancements in imaging have revolutionized diagnosis in nearly all field of medicine. Although DXA remains a standard clinical assessment, quantitative computed tomography (QCT), providing a volumetric assessment that can differentiate cortical and trabecular bone, has greatly advanced our understanding of compartment-specific changes to bone. The ability to even more accurately study cortical bone has come with the development of high-resolution peripheral QCT (HRpQCT), which allows peripheral skeletal sites (typically distal tibia and distal radius) to be scanned at a resolution of ~60 microns. This resolution permits the visualization and quantification of cortical porosity – the key structural manifestation that occurs in patients with disrupted kidney function (Figure 1A). Advancements in preclinical imaging have also occurred in the recent past similarly advancing the ability to assess cortical porosity in preclinical models. The goal of this review is to highlight recent studies in various settings of altered kidney function that have utilized high-resolution CT to study skeletal health with a particular focus on cortical bone porosity.

Imaging porosity in humans with kidney disease

The majority of studies examining cortical porosity in the setting of altered kidney function have utilized iliac biopsies. This approach, while logical and resourceful, is limited in that the assessments are typically from cross-sectional studies, often lack controls, is an invasive

procedure, and are not focused on porosity in a site with relevant fracture risk. None-the-less, the data clearly convey a consistent picture of notable porosity in the setting of kidney disease [2][3][4][5].

A small number of studies have utilized HR-pQCT in cross-sectional studies, overcoming some of the limitations of working with iliac crest biopsies. Several of these imaging studies unfortunately did not assess cortical porosity [6][7][8]. The most informational study regarding how porosity relates to other skeletal/cardiovascular outcomes comes from a study aimed at assessing whether cortical porosity is associated with fracture in CKD patients. To answer this question the authors imaged a cohort of hemodialysis patients with HR-pQCT scans at the distal radius and distal tibia [9]. Cortical porosity was significantly higher in patients with fractures and when comparisons were made by sex the authors found that females had higher porosity than males. Fractures, coronary artery calcification, and mortality were all associated with cortical porosity, although adjustment for age and gender eliminated these statistically significant associations. Within the Bielesz et al paper, their comparison between HR-pQCT data and traditional dual x-ray absorptiometry (DXA), showed that HR-pQCT did not add any additional value in identifying fragility fractures in CKD patients compared to BMD from DXA alone. Due to its cross-sectional nature, this study was unable to identify if cortical porosity led to a better prediction of fragility fracture risk compared to DXA alone. None-the-less this work is foundational in its in-depth assessment of cortical porosity from HR-pQCT scans and represents a model design of assessment for future work in cross-sectional studies.

The most powerful studies in the area of cortical porosity have performed longitudinal analysis of patients with kidney disease using HR-pQCT. In a 2013 landmark study, Nickolas and colleagues examined patients with chronic kidney disease (stages 2–5D) using HR-pQCT scans of the distal tibia and distal radius repeated over a period of 1–4 years (median time between scans was 1.5 years)[10]. Patients had variable disease etiologies, and various interventions during the period of study. Of the 53 individuals, only one progressed to dialysis during the study period while the others had kidney function that did not change significantly. Cortical porosity was significantly higher than baseline in both the radius (+4.2%) and tibia (+3.9%) with no significant change in trabecular BMD (Figure 1B). When comparing the effects of disease severity [defined on whether or not patients were on hemodialysis at any point in the study (43 No; 10 Yes)], hemodialysis independently predicted an ~7% yearly increases in radial cortical porosity. A similar trend was noted in the tibia. Also notable was that these cortical changes occurred despite modest/no change in trabecular bone, the compartment of bone that is known for its malleability and frequent alterations in osteoporosis. This highlights the dynamic nature of the cortical shell in kidney disease, specifically in cortical porosity, and these findings were noteworthy in that it showed the rapid rate of change within patients and the relationship of disease severity to cortical porosity.

A 2014 follow-up study by the same group examined the bone effects of kidney transplant using HR-pQCT[11]. Patients (n=31) were scanned at baseline and one-year post-transplantation. Transplantation reduced parathyroid hormone (PTH), as well as markers of bone remodeling (osteocalcin and CTX), by ~50% across all patients, although levels were

still above normal or in the upper-limits of post-transplant values. This work used a novel approach to examine cortical porosity due to the observation of the authors (and others) that standardization of cortical bone analyses is challenging due to its dependence on defining the endocortical surface which typically becomes “trabecularized” in bone loss diseases such as in kidney transplant patients.

The authors compared three different methods to define the cortical compartment with the goal of determining whether differences in cortical bone designation impacted the ability to capture changes in cortical bone phenotype in kidney transplant patients. They found that irrespective of bone site (distal radius or distal tibia) and methodology of cortical bone determination, patients one-year post transplant experienced increased cortical porosity. Additional microarchitecture parameters found that both cortical area and cortical thickness were reduced after transplant. The authors found associations between PTH and bone remodeling markers that could predict the severity of cortical porosity. Furthermore, biomarkers such as osteocalcin, BSAP, and CTX displayed a linear dose-response relationship to increasing cortical porosity. The most notable finding of this study is that is that at one-year post-transplant, there are no significant beneficial effects (lowering) on cortical porosity despite a 50% reduction in PTH levels. This suggests that for cortical porosity to reverse it may necessitate longer periods of time post kidney transplant or greater reductions of PTH levels. But in the worst case scenario, it would suggest cortical porosity may be irreversible in the setting of CKD.

Reality CT - Watching pores develop in a preclinical kidney disease model.

High-resolution imaging has been available to pre-clinical research for a longer period of time than in clinical studies. Over the years, numerous papers have defined the cortical bone phenotype of various models with altered kidney function by examining bone structure of excised bone. Several such studies have been published in the past 3 years, but none that have necessarily provided transformative insight. They collectively note that cortical porosity exists in various models and interventions can be used to stop or slow porosity from worsening. The most novel imaging approach in pre-clinical studies has been the utilization of *in vivo* CT to examine dynamic changes to cortical bone over time within the same animal.

The naturally progressing Cy/+ rat model has been used for decades to study manifestations of kidney disease [12–14]. One long-standing question of the model has been when cortical porosity develops, as the previously published studies exclusively used end-point bone assessments [15,16][17]. The work of McNerney and others used *in vivo* microCT to track the time course of cortical porosity changes during disease development in the Cy/+ rat model [18]. At a scanning voxel size of 9 microns, the distal tibia was imaged at three timepoints, which based on historical data corresponded to early, mid, and late disease stages. The imaging data revealed that porosity formed only during the later stages of disease (between the latter two timepoints) (Figure 2). Additionally, there was a fair amount of heterogeneity in the degree of porosity that developed, although within each animal there was homogeneity in porosity among bones studied (tibia and femur). One of the more intriguing findings was the dynamic nature of pores that can only be garnered from *in vivo*

scans. That is, over time it appeared that some pores refilled, some grew, and others were newly developed . This ability to 'watch' pores over time opens new avenues of work that can focus on individual pore dynamics and how they are affected not only by disease (in this case to the kidney) but more importantly by interventions.

Conclusion/Future directions

Medical imaging, for both clinical and pre-clinical applications, is advancing at an unparalleled rate. One of the most exciting research-related aspects of this advancement is that it opens doors to answer questions that simply were not possible to address in previous generations. For bone, this means allowing us to move beyond the traditional morphological assessments of cortical area and thickness. Visualization of cortical pores, which have a well-known relationship to bone mechanical properties and fracture risk, likely represents the next frontier for skeletal imaging to improve our understanding of physiology in health and disease. Conditions like kidney disease where there are dramatic changes in cortical porosity provide an excellent starting point to develop improved quantification of cortical bone microarchitecture and the early work in this field has been provocative for several reasons.

Longitudinal changes in cortical porosity provide proof-of-principle evidence that changes over time can be detected with some degree of accuracy using high resolution imaging. Although data are currently limited, the clinical data showing cortical porosity is the most dramatically changed variable over time in CKD is eye-opening. This positions HR-pQCT imaging and cortical porosity assessment as a highly viable clinical biomarker of disease progression/treatment efficacy. Certainly, larger databases and imaging consortiums will be needed to establish reference populations to which various stages of CKD or other disease populations can be compared.

In the same way, preclinical studies can assess cortical porosity longitudinally within animals, thus overcoming the need for large group sizes to compensate for individual variation in porosity at baseline. One particular area where *in vivo* tracking over time could be essential is in answering questions about pore dynamics - how individual pores change over time with and without treatments/interventions. Currently, these questions remain unanswered as the ability to track individual pores over time has not been explored in great detail.

Finally, although cortical bone measures are possible in the distal radius and tibia, the cortex at each of these locations is thin relative to other bone sites. Clinical protocols exist to image at more proximal locations, such as the diaphysis of the tibia or radius, but data can also potentially be obtained in the fibula/ulna which both have thicker cortexes at the more distal sites. Work to potentially describe the utility of these sites in assessing cortical bone properties seems warranted.

Finally, with the advancement of MRI technology it is now possible to generate porosity data that is highly correlative to CT [19]. Advancement of MRI measures would help move the concepts of porosity forward as scans could more easily be undertaken without radiation

concerns. Sites with high fracture risk such as the femoral neck, which are not reachable with current HR-pQCT approaches, could be easily imaged with MRI.

References

**1. Parfitt AM. A structural approach to renal bone disease. J. Bone Miner. Res 1998 p. 1213–20. [PubMed: 9718188] A timeless review, from one of the greatest thought-leaders in metaboli bone disese, that is a must read for anyone interested in kidney disease and bone.

2. Pereira RC, Bischoff DS, Yamaguchi D, Salusky IB, Wesseling-Perry K. Micro-CT in the assessment of pediatric renal osteodystrophy by bone histomorphometry. Clin J Am Soc Nephrol. 2016;11:481–7. [PubMed: 26712809]

3. Carvalho C, Magalhães J, Neto R, Pereira L, Branco P, Adragão T, et al. Cortical bone analysis in a predialysis population: a comparison with a dialysis population. J Bone Miner Metab. 2017;35:513–21. [PubMed: 27830383]

4. Carvalho C, Magalhães J, Pereira L, Simóes-Silva L, Castro-Ferreira I, Frazão JM. Evolution of bone disease after kidney transplantation: A prospective histomorphometric analysis of trabecular and cortical bone. Nephrology. 2016;21:55–61. [PubMed: 26201946]

5. Santos MFP, Hernández MJ, de Oliveira IB, Siqueira FR, Dominguez WV., dos Reis LM, et al. Comparison of clinical, biochemical and histomorphometric analysis of bone biopsies in dialysis patients with and without fractures. J Bone Miner Metab; 2019;37:125–33. [PubMed: 29372334]

6. Malluche HH, Monier-Faugere MC, Blomquist G, Davenport DL. Two-year cortical and trabecular bone loss in CKD-5D: biochemical and clinical predictors. Osteoporos Int. 2018;29:125–34. [PubMed: 28993865]

7. Cejka D, Weber M, Diarra D, Reiter T, Kainberger F, Haas M. Inverse association between bone microarchitecture assessed by HR-pQCT and coronary artery calcification in patients with end-stage renal disease. Bone. 2014;64:33–8. [PubMed: 24709688]

8. Marques IDB, Araújo MJCLN, Graciolli FG, Reis LM do., Pereira RM, Custódio MR, et al. Biopsy vs. peripheral computed tomography to assess bone disease in CKD patients on dialysis: differences and similarities. Osteoporos Int. 2017;28:1675–83. [PubMed: 28204954]

9. Bielesz B, Patsch JM, Fischer L, Bojic M, Winnicki W, Weber M, et al. Cortical porosity not superior to conventional densitometry in identifying hemodialysis patients with fragility fracture. PLoS One. 2017;12:1–12.

10**. Nickolas TL, Stein EM, Dworakowski E, Nishiyama KK, Komandah-Kosseh M, Zhang CA, et al. Rapid cortical bone loss in patients with chronic kidney disease. J Bone Miner Res. 2013;28:1811–20. [PubMed: 23456850] The first in vivo HR-pQCT study in patients with CKD. Elegent data showing the dramatic changes in cortical porosity over time.

11. Nishiyama KK, Pauchard Y, Nikkel LE, Iyer S, Zhang C, McMahon DJ, et al. Longitudinal HR-pQCT and image registration detects endocortical bone loss in kidney transplantation patients. J Bone Miner Res. 2015;30:456–63.

12. Cowley BD, Grantham JJ, Muessel MJ, Kraybill AL, Gattone VH. Modification of disease progression in rats with inherited polycystic kidney disease. Am J Kidney Dis. 1996;27:865–79. [PubMed: 8651252]

13. Moe SM, Radcliffe JS, White KE, Gattone VH, Seifert MF, Chen X, et al. The pathophysiology of early-stage chronic kidney disease-mineral bone disorder (CKD-MBD) and response to phosphate binders in the rat. J Bone Miner Res. 2011;26:2672–81. [PubMed: 21826734]

14. Moe SM, Chen NX, Seifert MF, Sinders RM, Duan D, Chen X, et al. A rat model of chronic kidney disease-mineral bone disorder. Kidney Int. 2009;75:176–84. [PubMed: 18800026]

15. Moe SM, Chen NX, Newman CL, Gattone VH, Organ JM, Chen X, et al. A comparison of calcium to zoledronic acid for improvement of cortical bone in an animal model of CKD. J Bone Miner Res. 2014;29:902–10. [PubMed: 24038306]

16. Moe SM, Chen NX, Newman CL, Organ JM, Kneissel M, Kramer I, et al. Anti-sclerostin antibody treatment in a rat model of progressive renal osteodystrophy. J Bone Miner Res. 2015;30:539–49.

17. Aref MW, Swallow EA, Metzger CE, Chen N, Moe SM, Allen MR. Parathyroid suppression therapy normalizes chronic kidney disease-induced elevations in cortical bone vascular perfusion: a pilot study. Osteoporos Int. Osteoporosis International; 2019;30:1693–8. [PubMed: 31069439]

18**. Mcnerny EMB, Buening DT, Aref MW, Chen NX, Moe SM, Allen MR. Time course of rapid bone loss and cortical porosity formation observed by longitudinal μ CT in a rat model of CKD. Bone; 2019;125:16–24. [PubMed: 31059864] The first preclinical study using microCT imaging to show in vivo changes in rodents with CKD. The data clearly illustrate the development of cortical proosity.

19. Rajapakse CS, Bashoor-Zadeh M, Li C, Sun W, Wright AC, Wehrli FW. Volumetric cortical bone porosity assessment with MR imaging: Validation and clinical feasibility. Radiology. 2015;276:526–35. [PubMed: 26203710]

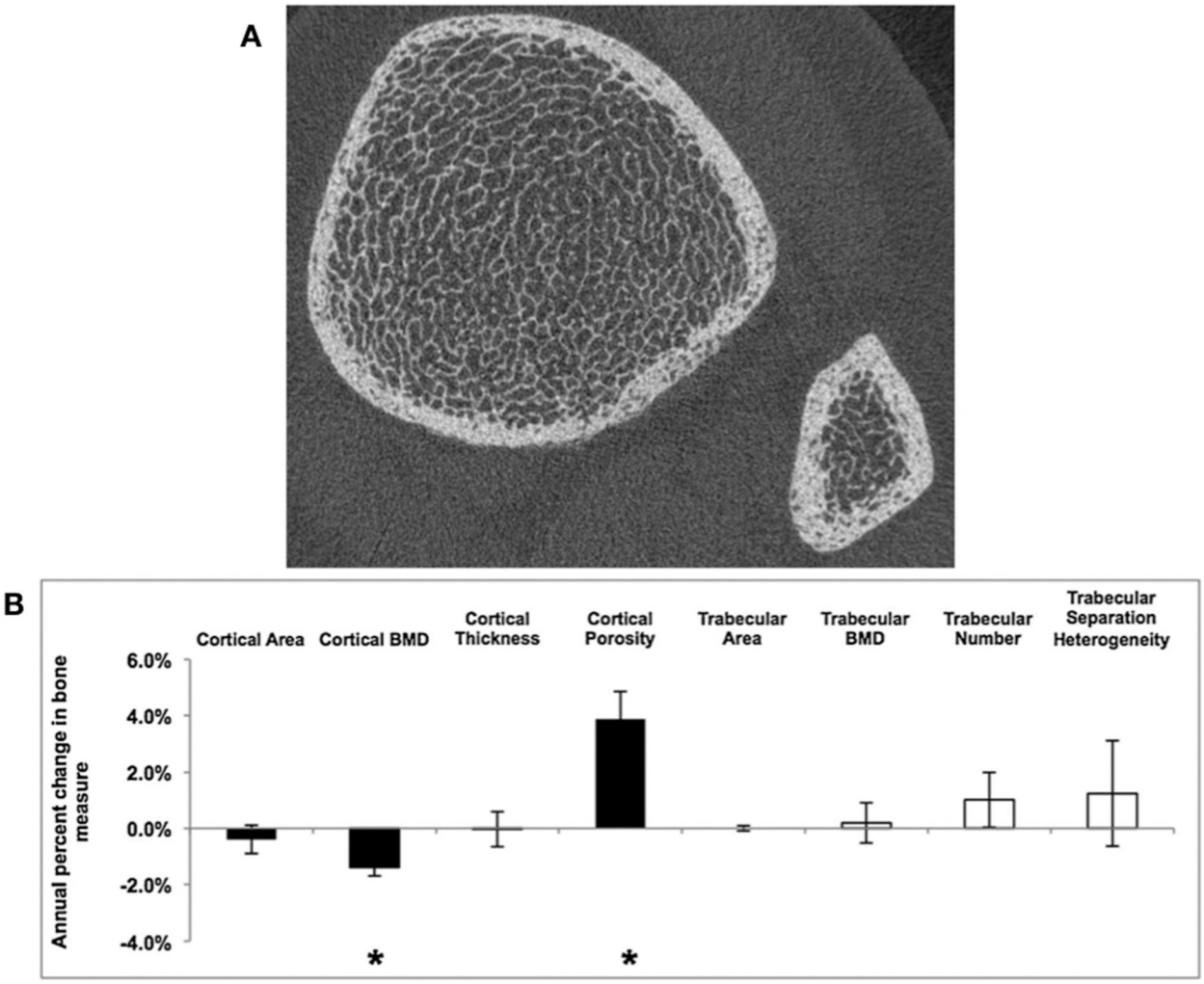

Figure 1.

Cortical porosity is the key skeletal phenotype in patients with chronic kidney disease. (A) HRpQCT provides unparalleled resolution imaging to visualize *in vivo* porosity. Lower limb scans typically involve the distal tibia, with scans also capturing the adjacent distal fibula which has been neglected in published papers despite it having a much thicker cortex compared to the tibia which may help in defining the cortical shell. Image courtesy of Tom Nickolas. (B) Annual percent change from baseline in volumetric BMD and bone geometry/microarchitecture by HRpQCT at the tibia (mean ± SEM). Reproduced with permission from *Nickolas TL, Stein EM, Dworakowski E, Nishiyama KK, Komandah-Kosseh M, Zhang CA, et al. Rapid cortical bone loss in patients with chronic kidney disease. J Bone Miner Res. 2013;28(8):1811–20.* Used with permission from John Wiley and Sons

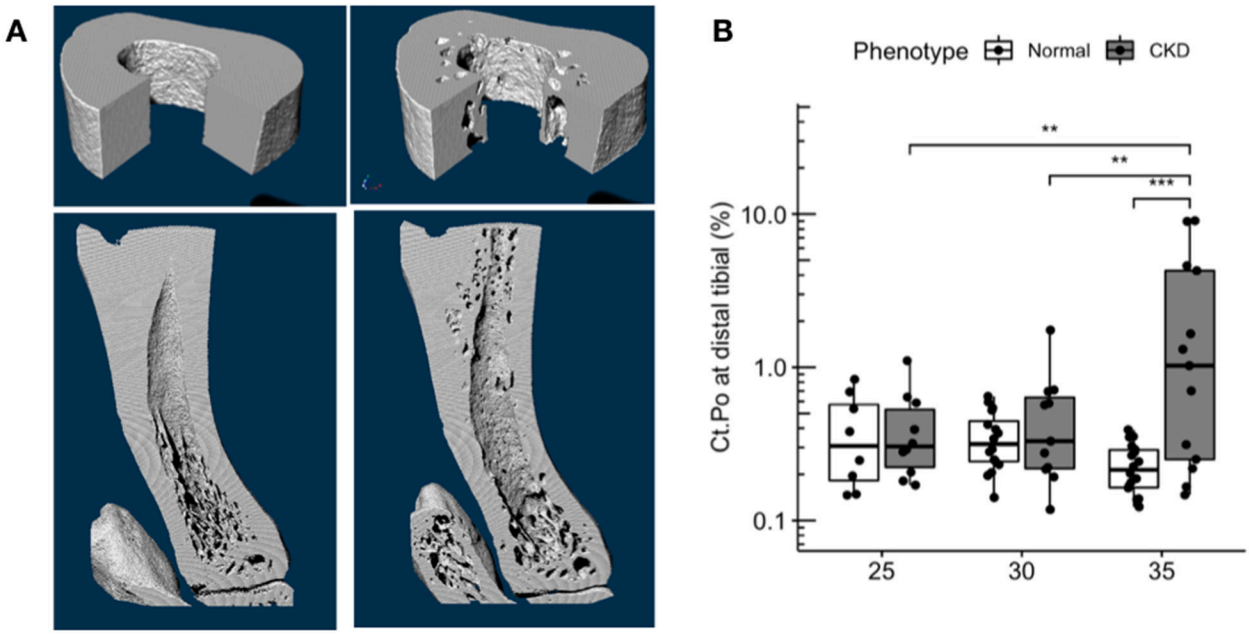

Figure 2.

(A) 3D renderings of longitudinal distal tibia scans a CKD rat at 30 and 35 weeks of age showing notable development of cortical pores. (B). Longitudinal measures of cortical bone porosity at the distal tibia in rats that progressively develop CKD. CKD animals had increasing amounts of cortical porosity (Ct.Po, %) over the 10-week study while normal littermates had little/no porosity over the same timeframe. Data shown as a box and whisker plot and log axis to accommodate the strongly skewed distribution. *p≤0.05; **p≤0.01; ***p≤0.001; ****p≤0.0001. Reproduced with permission from *McNerny EMB, Buening DT, Aref MW, Chen NX, Moe, SM, and Allen MR. Time course of rapid bone loss and cortical porosity formation observes by longitudinal uCT in a rat model of CKD. Bone. 125 (2019) 16–24.* Used with permission from Elsevier.