Abdominal pain at an altitude

Jason Russ, MD, FACP

Areeba Kara, MD, MS, FACP, SFHM

Department of Medicine, Indiana University School of Medicine

Presentation

A 29-year-old man presented for evaluation to the Emergency Department with 3 days of worsening abdominal pain. The pain was described as severe and was located in the left lower quadrant without radiation. It improved with assuming the supine position and was exacerbated by movement. On the day of presentation, he developed nausea, vomiting, and diarrhea. He was traveling in Peru when the pain began and thought it was related to something he ate, so he did not initially seek medical attention. Upon returning to the United States, he sought evaluation as his symptoms escalated. He had no known chronic medical problems and was not taking any prescription medications.

Assessment

On evaluation in the Emergency Department, he was afebrile and vital signs were stable (temperature 37°C, heart rate 66 beats per minute, blood pressure 134/74 mm Hg, respiratory rate 16 breaths per minute, and oxygen saturation 94% on room air). Abdominal examination revealed mild distention but no rigidity or rebound tenderness. Pain on deep palpation in the left upper quadrant was noted. The remainder of his physical examination was unremarkable. A computed tomography examination of the abdomen and pelvis with intravenous (IV) contrast showed concern for global infarction of his spleen without occlusion of the splenic artery or vein (Figure). Laboratory evaluation revealed a white blood cell count of 18.1 k/mm^3, hemoglobin 14.9 gm/dL, mean corpuscular volume 89 fL, and platelet count 207 k/mm^3. Chemistries were sodium 130 mmol/L, potassium 3.8 mmol/L, chloride 92 mmol/L, bicarbonate 30 mmol/L, blood urea nitrogen 18 mg/dL, creatinine 1.22 mg/dL, glucose 102 mg/dL, and calcium 10.4 mg/dL. Liver function tests were normal.

Diagnosis

Stool studies were sent to evaluate the patient's acute diarrhea to assess for infectious etiologies. These revealed the presence of enterotoxigenic *Escherichia coli* with both heat stable and labile toxins. Blood cultures showed no growth. He had no personal or family history of thrombophilia. To evaluate for sickle cell trait as an etiology, hemoglobin electrophoresis was performed and showed 57.7% hemoglobin A, 39.2% hemoglobin S, and 3.1% hemoglobin A2, consistent with

---

This is the author's manuscript of the article published in final form as:

Russ, J., & Kara, A. (2022). Abdominal Pain at an Altitude. *The American Journal of Medicine, 135*(4), 459–460. https://doi.org/10.1016/j.amjmed.2021.08.033

sickle cell trait (SCT). The patient was diagnosed with infectious diarrhea and splenic infarction related to SCT.

Management

The patient was managed symptomatically with pain control and IV hydration. His pain and gastrointestinal symptoms resolved with conservative treatment.

Traveler's diarrhea lasting <14 days does not need further investigation unless complicated by fever, bloody or mucoid stools, severe abdominal pain, or signs of sepsis. Ideally, a stool specimen is sent for molecular testing rather than culture, as these tests tend to be more sensitive and less dependent on the quality of the stool specimen. Treatment should be tailored to the pathogen identified.[1] The most common cause of traveler's diarrhea is enterotoxigenic *E. coli*.[2] Diarrhea may persist for 10-14 days even with antibiotic therapy.[1]

Splenic infarctions have been associated with cardioembolic sources (atrial fibrillation, endocarditis), malignant neoplasms, hypercoagulable states, sickle cell disease/trait, trauma, postoperative states, inflammatory conditions, infections, atherosclerosis, and cirrhosis.[3] Splenic infarctions are typically managed with IV hydration, analgesia, and monitoring. Improvement of symptoms is expected in 1-2 weeks. Splenectomy should be considered if pain does not improve or complications such as a splenic pseudocyst, abscess, or hemorrhage develop.[4] Anticoagulation is the mainstay in treatment for infarctions caused by an underlying hypercoagulable state, however, it is not required in those with sickle cell disease or trait, where infarction is related to the sickling of the red blood cells.

According to the Centers for Disease Control and Prevention, 1 in every 13 black or African American children born in the United States has the SCT.[5] The worldwide prevalence of SCT is about 300 million, with newborn screening data showing a prevalence of 1.5% (8% in African Americans).[6,7] Although sickle cell disease has been on every state's newborn screen since 2006 and participation in these screens reaches 99.9% of all births, there are still a significant number of adults who are unaware of their SCT diagnosis.[8,9] While individuals with SCT have a normal life expectancy, it has been linked to complications such as hematuria, renal papillary necrosis, hyposthenuria, splenic infarction, exertional rhabdomyolysis, and exercise-related sudden death.[10]

People with SCT are at an increased risk of splenic infarction when at high elevations, but there have been case reports of splenic infarctions occurring at or near sea level.[11] The risk of splenic infarction increases with exercise at high altitudes or flying in an unpressurized aircraft.[10] Our patient likely experienced a splenic infarction secondary to hiking at an altitude in Peru in conjunction with dehydration related to infectious diarrhea.

References

1. Shane AL, Mody RK, Crump JA, et al. 2017 Infectious Diseases Soci-ety of America clinical practice guidelines for the diagnosis and man-agement of infectious diarrhea. Clin Infect Dis 2017;65(12):e45–80.
2. Qadri F, Svennerhold AM, Faruque ASG, Sack RB. Enterotoxigenic Escherichia coli in developing countries: epidemiology, microbiol-ogy, clinical features, treatment, and prevention. Clin Microbiol Rev 2005;18(3):465–83.
3. Brett AS, Azizzadeh N, Miller EM, Collins RJ, Seegars MB, Marcus MA. Assessment of clinical conditions associated with splenic infarc-tion in adult patients. JAMA Intern Med 2020;180(8):1125–8.
4. Jaroch MT, Broughan TA, Hermann RE. The natural history of splenic infarction. Surgery 1986;100(4):743–50.
5. Centers for Disease Control and Prevention (CDC). Data & statistics on sickle cell disease. Available at: https://www.cdc.gov/ncbddd/sicklecell/data.html. Accessed August 10, 2021.
6. Grant AM, Parker CS, Jordan LB, et al. Public health implications of sickle cell trait: a report of the CDC meeting. Am J Prev Med 2011;41 (6 suppl 4):S435–9.
7. Kehinde TA, Osundiji MA. Sickle cell trait and the potential risk of severe Coronavirus Disease 2019 − a mini-review. Eur J Haematol 2020;105(5):519–23.
8. Centers for Disease Control and Prevention (CDC). State-based select hemoglobinopathies monitoring. Available at: https://www.cdc.gov/ncbddd/hemoglobinopathies/features/keyfinding-state-based.html. Accessed August 10, 2021.
9. Eunice Kennedy Shriver National Institute of Child Health and Human Development, National Institutes of Health. How many new-borns are screened in the United States? Available at: https://www. nichd.nih.gov/health/topics/newborn/conditioninfo/infants-screened. Accessed August 10, 2021.
10. Tsaras G, Owusu-Ansah A, Boateng FO, Amoateng-Adjepong Y. Complications associated with sickle cell trait: a brief narrative review. Am J Med 2009;122(6):507–12.
11. Seegars MB, Brett AS. Splenic infarction associated with sickle cell trait at low altitude. Hematology 2015;20(10):607–9.

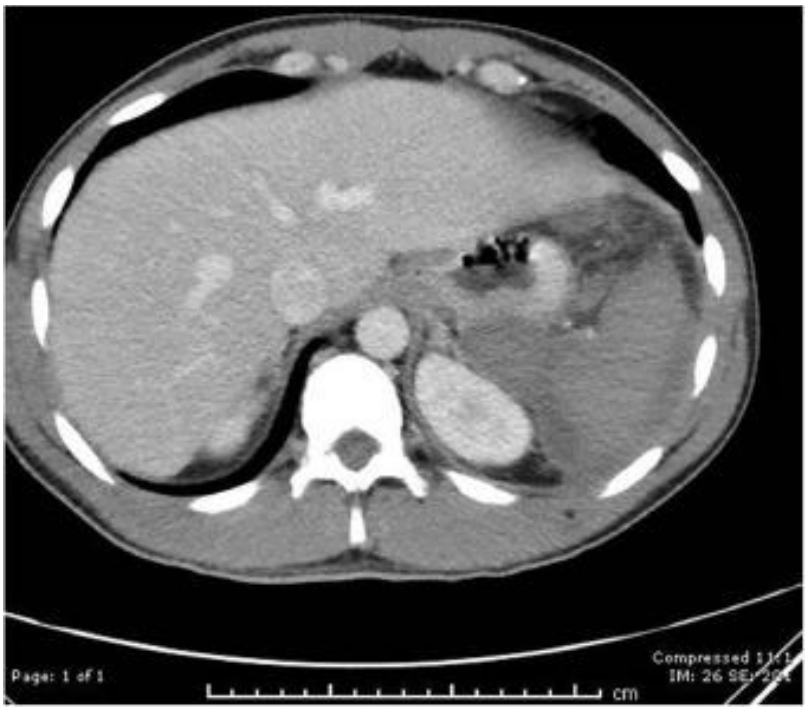

Figure. Computed tomography of the abdomen shows global infarction of the spleen.