Use of a novel *Chinchilla* skull base repair model

to test a photo-initiated thiol-ene biopolymer

Adam M. Terella, MD[1], Peter Mariner, PhD[2], Carlyne D. Cool, MD[3], Vijay R. Ramakrishnan, MD[4]

[1]Departments of Otolaryngology – Head and Neck Surgery and Dermatology, University of Colorado School of Medicine. Aurora, Colorado.

[2]Department of Chemical and Biological Engineering, University of Colorado at Boulder, Boulder, Colorado.

[3]Department of Pathology, University of Colorado School of Medicine. Aurora, Colorado.

[4]Department of Otolaryngology – Head and Neck Surgery, Indiana University School of Medicine. Indianapolis, Indiana.

Corresponding Author:

Vijay R. Ramakrishnan, MD

Department of Otolaryngology-Head and Neck Surgery, Indiana University School of Medicine
1130 W. Michigan St.
Fesler Hall, Ste 400
Indianapolis, IN 46202
E-mail: vrramakri@iu.edu

Ethics Statement: Animal experimental methods were approved by the University of Colorado Denver Institutional Animal Care and Use Committee (IACUC, Protocol 95011(06)1D).

Keywords: Skull base repair, CSF leak repair, Chinchilla, Hydrogel, Polyethylene Glycols, Reconstructive Surgical Procedures, Skull Base, Wound Healing, Biomaterials

---

This is the author's manuscript of the article published in final edited form as:

Terella, A. M., Mariner, P., Cool, C. D., & Ramakrishnan, V. R. (2022). Use of a novel Chinchilla skull base repair model to test a photo-initiated thiol-ene biopolymer. International Forum of Allergy & Rhinology. https://doi.org/10.1002/alr.23004

Disclosure of Funding: This projected was funded by a CORE grant through the American Academy of Facial Plastic and Reconstructive Surgery (AAFPRS Leslie Bernstein Investigator Development Grant, AAO239891).

Conflict of Interest: Peter Mariner, PhD, has a former affiliation with Mosaic Biosciences.

Introduction

Widespread adoption of minimally-invasive skull base surgery required reliable reconstructive options.[1] Although reliable vascularized flaps are available, there is associated morbidity, and such repairs may still fail in challenging situations. Novel repair techniques are often applied in patients after radiographic and cadaveric feasibility studies, and recommended based on anecdotal experience. The myriad options currently available for reconstruction, and novel biomaterials in development, deserve more rigorous study. A simple and accessible animal model would be helpful to answer these questions and to evaluate new biomaterials. PEG hydrogels have been considered as a tissue sealant, and through their tunable chemistry, can be enhanced with time release formulations of cell-adhesion molecules and growth factors to modify strength, rate of degradation, and program wound healing processes such as fibrosis and bone regeneration.[2] Moreover, degradable moieties can release growth factors to expedite neo-vascularization, bone ingrowth, or any number of regenerative cellular programs. In this study we aimed to: 1) establish a simple and accessible *Chinchilla* skull base defect model, and 2) evaluate the use of a biocompatible, light-initiated polymer matrix for use in minimally-invasive repair of skull base defects.

Methods

Enrofloxacin (5 mg/kg PO) was administered at the onset of surgery and continued twice daily for 7 days. Surgical access is described in **Fig 1**. For each repair, thinned fascia was placed as an intradural graft, and an extradural fascial onlay was applied. On the control side, fibrin glue and a piece of gelfoam were placed, and on the contralateral (experimental) side, light-initiated poly(ethylene glycol (PEG) hydrogel was applied. Monomer photo-initiated polyethylene glycol (PEG) gel biopolymer solutions were created as previously described.[3] Solutions were added dropwise to surgical defects and polymerized in place by exposure to 385nM light (10mW/cm2) for 20 seconds. Postoperative pain was controlled with meloxicam 1-2 mg/kg daily for 3 days. Animals were sacrificed by pentobarbital injection.

To test burst pressure, the scalp incision was reopened and a large bore needle was placed through the occiput into the subdural space and sealed, creating a fixed system for dynamic fluid testing. Dynamic fluid testing was completed using a Propaq CS Monitor connected to an invasive blood pressure pressure transducer (Welch Allyn, Skaneateles Falls, NY), and an Encore 26 pressure bag with manual balloon catheter pump (Boston Scientific, Marlborough, MA). The system was primed with dyed saline and injected into the intracranial space. The intracranial pressure recorded at the point of first visualization of dye was defined as the burst pressure of the repair.

Histologic processing using hematoxylin and eosin and Masson trichrome stains was done using standard protocols.[4,5] Statistical comparison of semi-quantitative grading was done with one-way ANOVA on ranks and paired permutation.

Results

36/40 animals survived to their designated endpoint (90%). Post-mortem examination of the four remaining animals by the staff veterinarian concluded attributed death to anesthetic (1), diarrheal infection (1), and unknown cause (2).

At day 0, animals showed a wide range of burst pressures (11 mm Hg - 300 mm Hg). At later timepoints, leak thresholds for both the experimental and control sides generally occurred at pressures exceeding the maximal range of the manometer (>300 mmHg). Ordinal values were assigned and compared using a Wilcoxon signed-rank test, demonstrating no difference between the repair groups.

Differences in bony defect diameter between the experimental and control sides was not significant, as measured by microCT ($p=0.36$) [**Supplementary Figures 1 and 2**].

Histologic comparison revealed no significant difference in inflammation, collagen deposition, fibrosis, vascularity, or bone formation [**Figure 2, Supplementary Figure 3**]. In the PEG gel polymer repairs, complete filling of the surgical defect was routinely observed.

Discussion

Many types of skull base repairs have been advocated, with testing of novel biomaterials in different systems.[6-8] The chinchilla offers several advantages—it is small, resilient, and affordable, and the temporal bone anatomy is favorable for rapid surgery and appropriate defect size, while recapitulating histologic and microbiologic features of the human skull base.[9] CSF pulsation and intracranial pressures are of generally similar magnitude to human, and within-animal control procedures can be performed.

In our experiments, wound healing and high tensile strength was reached quickly. At 0-3 days, tests of intracranial leak pressure exceeded maximum capability of our manometer (>300 mm Hg) and far surpassed the pressures observed in human pathology. There may have been some variability in these measurements due to microscopic differences in graft placement or manual pressure application in the burst pressure measurement apparatus, which could be corrected for in the future with improved design. Our postoperative examinations suggest that early postoperative endpoints for pressure testing, and assessment of bone and tissue remodeling, can occur at early timepoints. Although this timeline does not directly parallel human wound healing, the resiliency of rodents and early postoperative time point after survival surgery experiments offers a lower expense and higher likelihood of success when compared to large animal surgery (e.g., pig or sheep) where there are increased costs, perioperative care requirements, longer postoperative time courses, and lower rates of survival.

Our examinations of repair with the photo-initiated thiol-ene polymer showed non-inferiority when compared to traditional fibrin glue. Importantly, the polymer matrix completely filled the defect space and its application did not incite any additional inflammatory response. This study offers promising initial findings promoting innovation in biomaterials development for this challenging wound-healing environment, where modern chemical engineering approaches can be applied to develop a simpler reconstructive strategy that meets a set of unique needs.

Figure Legend

Figure 1. *Top panel,* Surgical creation of bilateral skull base defects in the chinchilla. Under inhaled isoflurane anesthesia, bilateral defects were created through a single dorsal postauricular incision. Posterior (dorsal) view of the chinchilla skull demonstrating the prominent superior bullae of the temporal bone (A). The bullae are opened with a curette (B). Cadaveric dissection of the left side illustrates the ~5x8mm bony defect that can be created (C), and a sharp pick can be used to open the dura once bone has been removed with a diamond bur (D). *Bottom panel,* flow diagram of animal survival and postoperative assessments.

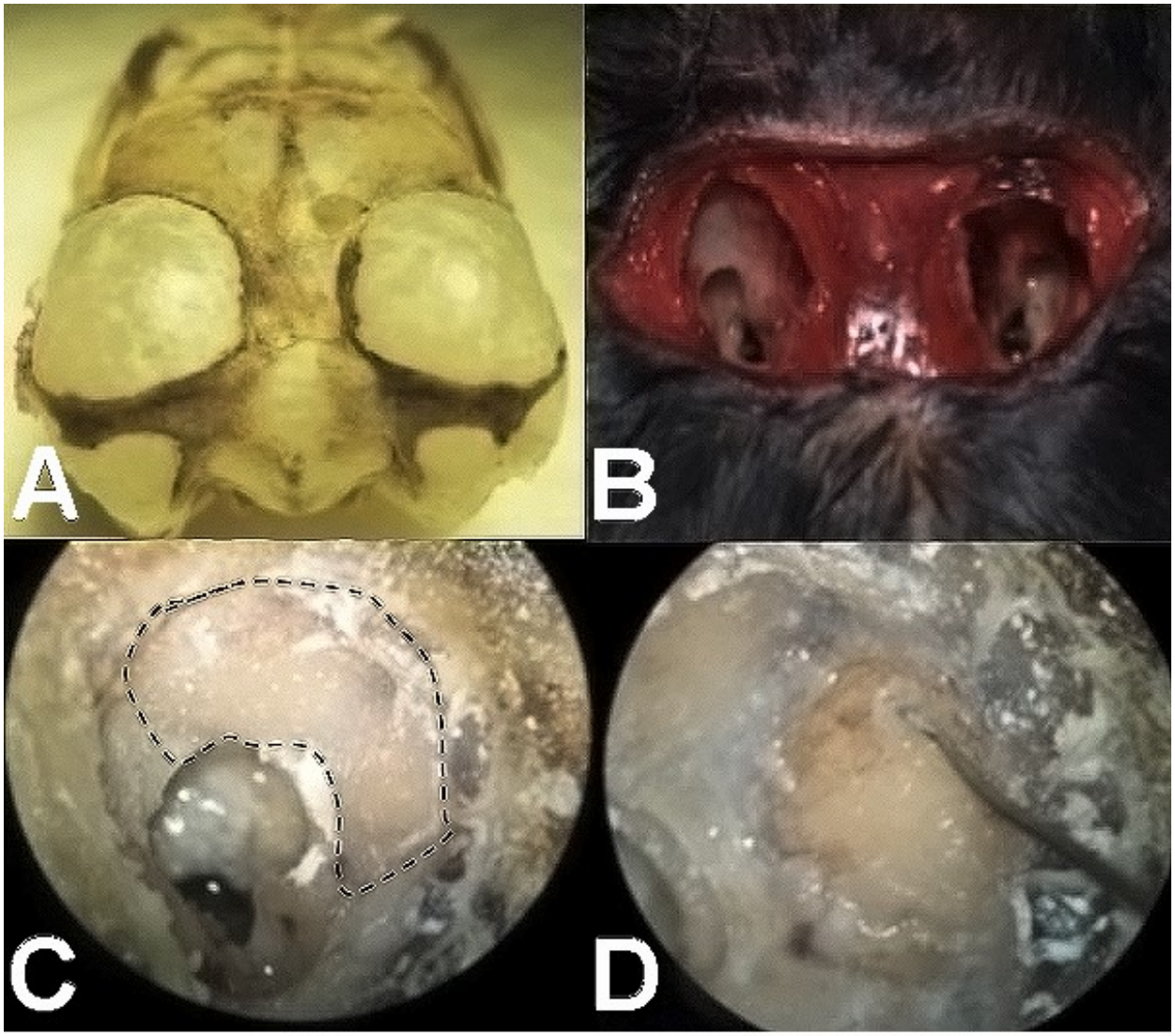

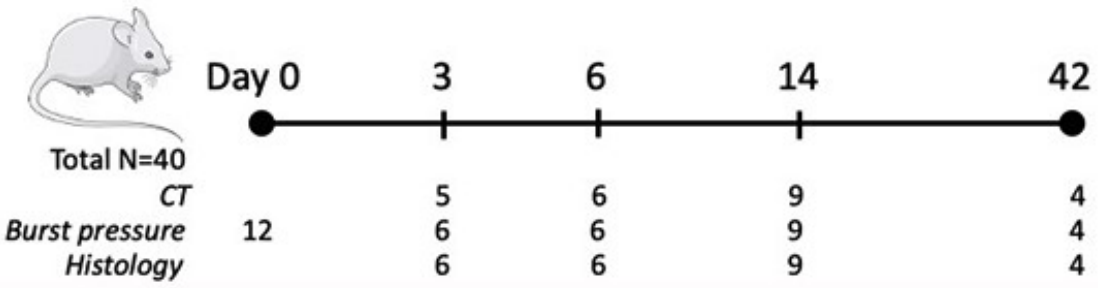

Figure 2. Representative H&E and Masson trichrome stained coronal sections of skull base repairs at 2-weeks postoperatively. Control (A) and experimental PEG-gel (B) repairs demonstrate complete filling of the defect in the PEG-treated repairs, whereas the standard repair shows irregular closure with adherence of fascia to underlying bony edges (total magnification, 40X). Masson trichrome stain images demonstrate absence of inflammatory reaction to the PEG-gel repair; inflammatory reaction was not seen in an immediate or delayed fashion in the underlying cerebellum (C), total magnification 100X. *Gelfoam (G), Fascial repair layer (F), Bony defect margin (arrowheads), incomplete soft tissue closure (*).*

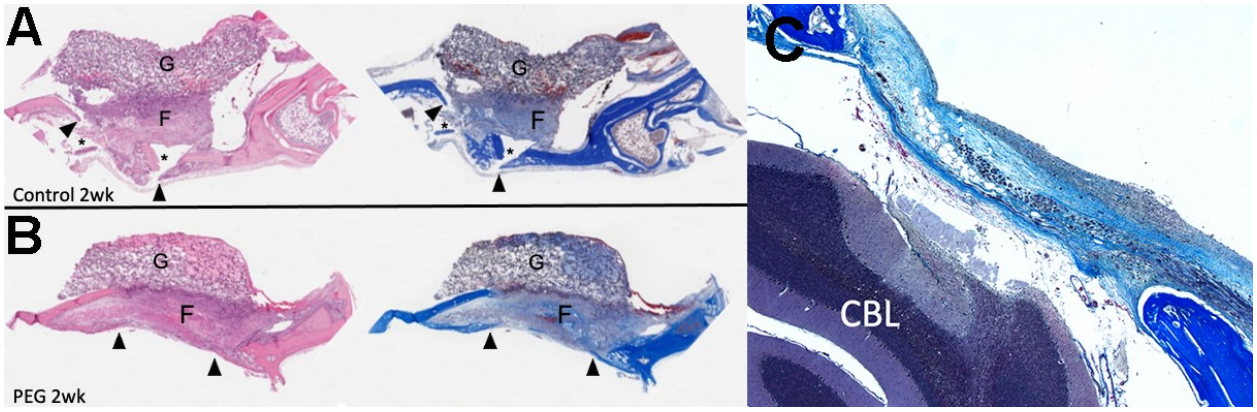

Supplementary Figure 1. Micro-CT evaluation of temporal defects utilizing 3-dimensional reconstruction (bottom right) to measure defect diameter. The defect is shown in the axial and coronal planar images with arrowheads, and in the 3-dimensional reconstruction with the dotted circle. Micro-CT was performed immediately after sacrifice using a protocol with a spatial resolution of 70μm, and 3D analysis was completed with Mimics software (Materialise, Leuven, Belgium).

Supplementary Figure 2. Osseous skull base defect closure was similar between the two groups, as measured by difference in maximal defect diameter (mm). Lines represent the predicted difference between sides (center line) and 95% confidence intervals. Comparisons were made by ANOVA.

Supplementary Figure 3. Similar histologic parameters were seen in both groups at 2-weeks postoperatively. Characteristics were assessed by a blinded pathologist according to a previously used semi-quantitative scale[7] for degree of inflammation, collagen deposition, fibrosis, and vascular or bony ingrowth (0=absent, 1=mild, 2=moderate, 3=pronounced).

References

1. Wang EW, Zanation AM, Gardner PA, Schwartz TH, Eloy JA, Adappa ND, et al. ICAR: endoscopic skull-base surgery. Int Forum Allergy Rhinol. 2019 Jul;9(S3):S145-S365.

2. Aimetti AA, Machen AJ, Anseth KS. Poly(ethylene glycol) hydrogels formed by thiol-ene photopolymerization for enzyme-responsive protein delivery. Biomaterials 2009 ;30(30):6048-54.

3. Fairbanks BD, Schwartz MP, Bowman CN, Anseth KS. Photoinitiated polymerization of PEG-diacrylate with lithium phenyl-2,4,6-trimethylbenzoylphosphinate: polymerization rate and cytocompatibility. Biomaterials 2009;30(35):6702–6707.

4. Terella A, Mariner P, Brown N, Anseth A, Streubel SO. Repair of a calvarial defect with biofactor and stem cell-embedded polyethylene glycol scaffold. Arch Facial Plast Surg 2010;12(3):166-171.

5. Gouveris H, Nousia C, Giatromanolaki A, Riga M, Katomichelakis M Ypsilantis P, et al. Inferior nasal turbinate wound healing after submucosal radiofrequency tissue ablation and monopolar electrocautery: histologic study in a sheep model. Laryngoscope 2010;120:1453-9.

6. Ein L, Sargi Z, Nicolli EA. Update on anterior skull base reconstruction. Curr Opin Otolaryngol Head Neck Surg 2019;27(5):426-430.

7. Bleier BS, Palmer JN, Sparano AM, Cohen NA. Laser-assisted cerebrospinal fluid leak repair: an animal model to test feasibility. Otolaryngol Head Neck Surg 2007;137(5):810-4.

8. De Almeida JR, Ghotme K, Leong I, Drake J, James AL, Witterick IJ. A new porcine skull base model: fibrin glue improves strength of cerebrospinal fluid leak repairs. Otolaryngol Head Neck Surg 2009;141(2):184.

9. Bakaletz LO. Chinchilla as a robust, reproducible and polymicrobial model of otitis media and its prevention. Expert Rev Vaccines 2009;8(8):1063-82.

