HHS Public Access

Author manuscript

Pathology. Author manuscript; available in PMC 2022 July 14.

Published in final edited form as:

Pathology. 2021 February ; 53(2): 214–219. doi:10.1016/j.pathol.2020.07.005.

Invasive poorly differentiated adenocarcinoma of the bladder following augmentation cystoplasty: a multi-institutional clinicopathological study

Joshua A. Anderson[1], **Andres Matoso**[2], **Belkiss I. Murati Amador**[2], **Liang Cheng**[3], **Bradley A. Stohr**[4], **Emily Chan**[4], **Adeboye O. Osunkoya**[1,5,6,7]

[1]Department of Pathology, Emory University School of Medicine, Atlanta, GA, USA;

[2]Department of Pathology, Johns Hopkins University School of Medicine, Baltimore, MD, USA;

[3]Department of Pathology and Laboratory Medicine, Indiana University School of Medicine, Indianapolis, IN, USA;

[4]Department of Pathology, University of California San Francisco, San Francisco, CA, USA;

[5]Department of Urology, Emory University School of Medicine, Atlanta, GA, USA;

[6]Winship Cancer Institute of Emory University, Atlanta, GA, USA;

[7]Department of Pathology, Veterans Affairs Medical Center, Decatur, GA, USA

Summary

Augmentation cystoplasty is a surgical procedure used in the management of patients with neurogenic bladder. This procedure involves anastomosis of the bladder with gastrointestinal grafts, including portions of ileum, colon, or stomach. A rare but important complication of augmentation cystoplasty is the development of malignancy. The majority of malignancies arising in this setting have been described in case reports. A search for cases of non-urothelial carcinoma following augmentation cystoplasty was conducted through the urological pathology files of four major academic institutions. Ten cases were identified, including six cystoprostatectomy/cystectomy, two partial cystectomy, and two transurethral resection of bladder tumour specimens. The mean patient age at diagnosis was 47 years (range 27–87 years). The male:female ratio was 4:6. The tumours tended to present at an advanced stage; four cystoprostatectomy/cystectomy cases were categorised as pT3a, one was categorised as pT3b, and one was categorised as pT4a. Lymph node metastases were present in all cases which had lymph node excision (range 1–16 positive nodes per case). The majority of cases (90%) were predominantly characterised by a poorly differentiated adenocarcinoma with signet ring cell features. Other morphological features included mucinous features (30%), plasmacytoid features (20%), enteric/villous architecture (10%), and large cell undifferentiated morphology (10%). This is the largest study to date on the clinicopathological features of invasive non-urothelial carcinoma of the bladder following augmentation cystoplasty. The tumours are typically poorly differentiated adenocarcinoma, with

Address for correspondence: Dr Adeboye O. Osunkoya, Department of Pathology, Emory University School of Medicine, Suite H174, 1364 Clifton Road, NE, Atlanta, GA, USA. adeboye.osunkoya@emory.edu.

Conflicts of interest and sources of funding: The authors state that there are no conflicts of interest to disclose.

diffuse signet ring cell features, aggressive, and present at high stage. Further molecular characterisation may provide additional insights into the pathogenesis of this entity.

Keywords

Adenocarcinoma; bladder; augmentation cystoplasty; signet-ring cells; poorly differentiated

INTRODUCTION

Augmentation cystoplasty is a surgical procedure used for the treatment of neurogenic bladder complications, such as over activity and low compliance. This procedure involves anastomosis of the bladder with gastrointestinal grafts, usually from portions of ileum, colon, or stomach. The goal of surgery is to increase bladder capacity and compliance in order to alleviate symptoms and protect against upper tract deterioration. Today, augmentation cystoplasty is primarily used after failure of conservative therapies, such anticholinergics, β3 agonists, or detrusor injections with botulinum toxins.[1]

An uncommon but important complication of bladder augmentation is the development of malignancy, which was first reported in 1971.[2] Retrospective studies have reported rates of malignancy following augmentation cystoplasty of up to 5.5%, with an estimated incidence of 0–273.3 per 100,000 patients/year. The median latency period between surgery and a malignant tumour has been reported to be 19 years. The most common histological tumour type is adenocarcinoma.[3]

Due to the rarity of this entity and long latency period, the clinicopathological features of malignancy following augmentation cystoplasty are poorly described in the literature with most cases being described in case reports. The aim of this case series is to describe the clinicopathological features of adenocarcinomas arising following augmentation cystoplasty.

MATERIALS AND METHODS

A search for cases of carcinoma of the bladder following augmentation cystoplasty was conducted through the urological pathology and expert consultation files of four major academic centres in the United States. Radical cystoprostatectomy, cystectomy, partial cystectomy, and TURBT (transurethral resection of bladder tumour) specimens were included. Cases that were diagnosed as urothelial carcinoma were excluded. All cases were re-reviewed by urological pathologists. Clinicopathological features were documented and follow-up data were obtained.

This study was completed following the guidelines of and with approval from our institutional review board.

RESULTS

A total of 10 cases (67%) following augmentation cystoplasty that were not diagnosed as urothelial carcinoma were identified including six cystoprostatectomy/cystectomy, two

partial cystectomy, and two TURBT specimens (Table 1). Five cases of urothelial carcinoma (33%) were excluded.

The mean patient age at diagnosis was 47 years (range 27–87 years). The male:female ratio was 4:6.

The type of augmentation cystoplasty included gastrocystoplasty (5 cases), colocystoplasty (3 cases), and ileocystoplasty (2 cases).

Pathological features

Grossly, the tumours were firm masses, often with surface ulceration, that histologically showed infiltrative growth into the bladder wall and perivesical adipose tissue.

The tumours tended to present at an advanced stage; four cystoprostatectomy/cystectomy cases were categorised as pT3a, one was categorised as pT3b, and one was categorised as pT4a. Lymph node metastases were present in all cases which had lymph node excision (range 1–16 positive nodes per case). In the cystectomy specimens, the tumours originated from the gastrointestinal grafts adjacent to the anastomotic site.

The majority of cases (9/10) were predominantly characterised by a poorly differentiated adenocarcinoma with signet ring cell features (Fig. 1). Signet ring cells were often seen diffusely (5/10), but in some cases signet ring cell features were only focal (4/10). Diffuse signet ring cell features were more commonly seen in gastric augmentation cases, as opposed to colonic or ileal augmentation cases. Other morphological features included mucinous features (3/10) with tumour cells floating within pools of extraluminal mucin, and plasmacytoid features (2/10) with cords, nests, and sheets of relatively bland tumour cells that mimicked chronic inflammation. The least common morphological features present in 1/10 cases each included enteric/villous architecture and large cell undifferentiated morphology (Fig. 2 and 3). A desmoplastic stromal response and tumour necrosis were present in 5/10 and 4/10 cases, respectively. Angiolymphatic invasion was present in half of the cases (5/10). Glandular dysplasia was identified in the augmentation specimens in 3/10 cases, two with high grade dysplasia and one with low grade dysplasia. No urothelial dysplasia was identified in any of the cases. Variable degrees of inflammatory and reactive changes were often seen intimately admixed with the tumour cells in most cases. Three gastrocystoplasty cases showed significant acute and chronic inflammation and two had foci of intestinal metaplasia. All three colocystoplasty cases showed extensive chronic inflammation and focal to extensive Paneth cell change. One ileocystoplasty case showed villous atrophy with chronic inflammation and prominent lymphoid aggregates. One patient with a prior colocystoplasty subsequently developed rectal adenocarcinoma. The rectal adenocarcinoma was morphologically and immunohistochemically distinct from the adenocarcinoma in the cystoplasty specimen; the rectal adenocarcinoma showed typical colorectal adenocarcinoma morphology and immunohistochemical profile (positive CDX2 and CK20 expression) while the tumour in the cystoplasty specimen showed signet ring cells, villous architecture, mucinous features, and negative CDX2 and CK20 expression. Given the different morphological features and immunohistochemical profiles, the two tumours were favoured to represent separate primaries.

In the cases in which immunohistochemical stains were performed (Fig. 4), the tumour cells were positive for CK20 (3/5), CDX2 (3/4), CK7 (3/4), p63 (1/2, focal positivity) and negative for GATA3 (0/4). Synaptophysin and chromogranin showed focal to patchy positive staining (2/3). In one of the latter cases, the corresponding left external iliac lymph node metastasis also showed neuroendocrine features.

Follow-up information

Follow-up information was available for 9/10 patients. Mean duration of follow-up was 7 months (range 1–13 months). Of those with follow-up information, 8/9 patients developed distant metastasis to various sites, including liver, lung, bone, retroperitoneum, and peritoneal cavity. Two patients died of disease within a mean duration of 7 months (range 1–13 months). Two patients were transferred to hospice within a mean duration of 6 months (range 4–7 months). Two patients had initial follow-up of 3–5 months but were subsequently lost to follow-up. Two patients are alive with disease 10–11 months following surgery. Finally, one patient is alive with no evidence of disease recurrence 10 months following surgery.

DISCUSSION

Due to the rarity of malignancy following augmentation cystoplasty, the pathological features of these tumours have mostly been described in case reports. The first case of malignancy following augmentation cystoplasty was reported by Smith and Hardy in 1971.[2] They described the case of a 43-year-old woman who developed carcinoma 17 years following ileocystoplasty performed for bladder contraction due to tuberculous cystitis. Pathologically, they described the tumour as a poorly differentiated ‘transitional cell carcinoma’ arising in the small intestinal type mucosa of the augmentation specimen.[2] Following this initial case report, more malignancies occurring following ileocystoplasty and colocystoplasty were subsequently reported. Multiple different histological subtypes of malignancy were described including adenocarcinoma, signet ring cell carcinoma, urothelial carcinoma, squamous cell carcinoma, neuroendocrine tumours, and leiomyosarcoma.[3–7] The most commonly reported histological subtype was adenocarcinoma. The first case of carcinoma following gastrocystoplasty was reported by Qiu *et al.* in 2003, which was described as a high grade ‘transitional carcinoma’ in the setting of extensive squamous metaplasia arising in the gastric augment near the anastomosis site.[8] A couple of years later, the first case of signet ring carcinoma arising following a gastrocystoplasty case was reported by Baydar *et al.*[9] A more recent review of malignant tumours occurring after augmentation cystoplasty was performed by Biardeau *et al.*[3] They found that the most common histological subtype was adenocarcinoma, encompassing 51.6% of tumours. Urothelial carcinoma was the second most common subtype (23.4%) and signet ring cell carcinoma the third most common (10.9%). The authors noted that the pathological results of their study should be interpreted with caution due to the lack information about who performed pathological assessment.[3]

Our contemporary study adds to the existing literature by describing the clinicopathological features of an additional ten cases of adenocarcinoma following augmentation cystoplasty

reviewed by expert urological pathologists. We found that the morphology of these tumours was varied, often showing multiple morphological patterns within the same tumour. The tumours were usually poorly differentiated, and the most common morphological pattern was that of signet ring cells. The immunohistochemical profile of these tumours was also variable. The tumours tended to show dual positivity for CK7 and CK20, but expression of these markers was variable. CDX2 was often positive, consistent with glandular/enteric differentiation. Importantly, markers of urothelial differentiation, such as p63 and GATA3, were almost always negative or only focally positive to help distinguish these tumours from conventional urothelial carcinoma (or urothelial carcinoma with glandular differentiation). The tumours tended to be aggressive, often presenting at high stage and with lymph node metastases. Morphological features suggestive of aggressive behaviour, such angiolymphatic invasion, florid desmoplastic stromal reaction, and tumour necrosis, were often present.

The pathogenesis of adenocarcinoma following augmentation cystoplasty is poorly understood. Several possible mechanisms have been proposed.[4,6,10–14] One of the earliest proposals suggested that the production of carcinogenic N-nitrosamines by bacteria contributed to the development of malignancy. Animal models have shown that exposure to these compounds led to the development of tumours in rats with ureterosigmoidostomy, and high concentrations of urinary N-nitrosamines have been found in patients with tumours following ureterocolic anastomosis.[4,14] In addition, histological studies have shown inflammatory and dysplastic changes within the mucosa of gastrointestinal augmentation specimens, and the extent of the histological alteration was correlated with the presence of bacteriuria.[5] However, this hypothesis is controversial, as more recent studies have shown no correlation between bacteriuria and the development of malignancy.[6,15]

Chronic inflammatory changes have also been suggested as a possible pathogenic mechanism. Studies have shown that chronic inflammatory histological changes occur within the gastrointestinal augmentation specimens, including increased chronic inflammatory cells, mucosal atrophy, and metaplasia.[5,11] These chronic inflammatory changes are theorised to induce malignancy through increased cell turnover as well as the production of compounds such as prostaglandins, growth factors, and free radicals which have been implicated in carcinogenesis.[10,11]

In addition, some studies have shown an increase in molecular alterations occurring near the enterovesical anastomosis in augmentation cystoplasties. Appanna *et al.* observed chromosomal amplifications on 2p, 3q, 8q, 9p, 17p, 18pq, and 20pq which were more likely to occur near the anastomosis site compared to sites distant from the suture line.[11] Ivil *et al.* demonstrated an increased rate of p53 mutations and aneuploidy, most commonly affecting chromosome 18, both of which occurred preferentially at the anastomotic sites in patients with ileocystoplasties.[12,13] Taken together, these molecular alterations suggest that there is increased genetic instability in the epithelium at the enterovesical anastomosis which may play a role in tumourigenesis.

An interesting observation from our case series is that only one of the patients subsequently developed carcinoma at the native site of the gastrointestinal graft. This finding could suggest that the development of carcinoma in augmentation cystoplasty may be related to

the unique environment of the augmented bladder. It has been previously observed that the risk of developing malignancy in ileal and gastric augmented bladders appears to be higher than the risk of carcinoma at the native gastrointestinal site.[16] Whether or not bladder augmentation is an independent risk factor for malignancy is debated within the literature, since congenitally aberrant and neurogenic bladders may also be at increased risk to develop malignancy.[6,16] Further research is needed to understand the unique pathophysiological changes that occur within augmented bladders.

In summary, this is the largest study to date, to our knowledge, on the clinicopathological features of invasive adenocarcinoma of the bladder following augmentation cystoplasty. The tumours are typically poorly differentiated, with diffuse signet ring cell features, aggressive, and present at high stage. Further molecular characterisation may provide additional insights into the pathogenesis of this entity.

Acknowledgement:

Parts of this study were presented at the 2020 USCAP Meeting in Los Angeles, CA.

References

1. Budzyn J, Trinh H, Raffee S, et al. Bladder augmentation (enterocystoplasty): the current state of a historic operation. Curr Urol Rep 2019; 20: 50. [PubMed: 31342172]
2. Smith P, Hardy GJ. Carcinoma occurring as a late complication of ileocystoplasty. Br J Urol 1971; 43: 576–9. [PubMed: 5118135]
3. Biardeau X, Chartier-Kastler E, Rouprêt M, et al. Risk of malignancy after augmentation cystoplasty: a systematic review. Neurourol Urodyn 2016; 35: 675–82. [PubMed: 25867054]
4. Crissey MM, Steele GD, Gittes RF. Rat model for carcinogenesis in ureterosigmoidostomy. Science 1980; 207: 1079–80. [PubMed: 7355272]
5. Vajda P, Kaiser L, Magyarlaki T, et al. Histological findings after colocystoplasty and gastrocystoplasty. J Urol 2002; 168: 698–701. [PubMed: 12131353]
6. Higuchi TT, Granberg CF, Fox JA, et al. Augmentation cystoplasty and risk of neoplasia: fact, fiction and controversy. J Urol 2010; 184: 2492–6. [PubMed: 20961577]
7. Austen M, Kälble T. Secondary malignancies in different forms of urinary diversion using isolated gut. J Urol 2004; 172: 831–8. [PubMed: 15310979]
8. Qiu H, Kordunskaya S, Yantiss RK. Transitional cell carcinoma arising in the gastric remnant following gastrocystoplasty: a case report and review of the literature. Int J Surg Pathol 2003; 11: 143–7. [PubMed: 12754637]
9. Baydar DE, Allan RW, Castellan M, Labbie A, Epstein JI, et al. Anaplastic signet ring cell carcinoma arising in gastrocystoplasty. Urology 2005; 65: 1226.
10. Shacter E, Weitzman SA. Chronic inflammation and cancer. Oncology 2002; 16: 217–26. [PubMed: 11866137]
11. Appanna TC, Doak SH, Jenkins SA, et al. Comparative genomic hybridization (CGH) of augmentation cystoplasties. Int J Urol 2007; 14: 539–44. [PubMed: 17593101]
12. Ivil KD, Jenkins SA, Doak SH, et al. Identification of early p53 mutations in clam ileocystoplasties using restriction site mutation assay. Urology 2007; 70: 905–9. [PubMed: 17919692]
13. Ivil KD, Doak SH, Jenkins SA, et al. Fluorescence in-situ hybridisation on biopsies from clam ileocystoplasties and on a clam cancer. Br J Cancer 2006; 94: 891–5. [PubMed: 16552418]
14. Stewart M, Hill MJ, Pugh RC, et al. The role of N-nitrosamine in carcinogenesis at the ureterocolic anastomosis. Br J Urol 1981; 53: 115–8. [PubMed: 7237041]
15. Husmann DA, Rathbun SR. Long-term follow up of enteric bladder augmentations: the risk for malignancy. J Pediatr Urol 2008; 4: 381–5. [PubMed: 18653384]

16. Husmann DA. Malignancy after gastrointestinal augmentation in childhood. Ther Adv Urol 2009; 1: 5–11. [PubMed: 21789049]

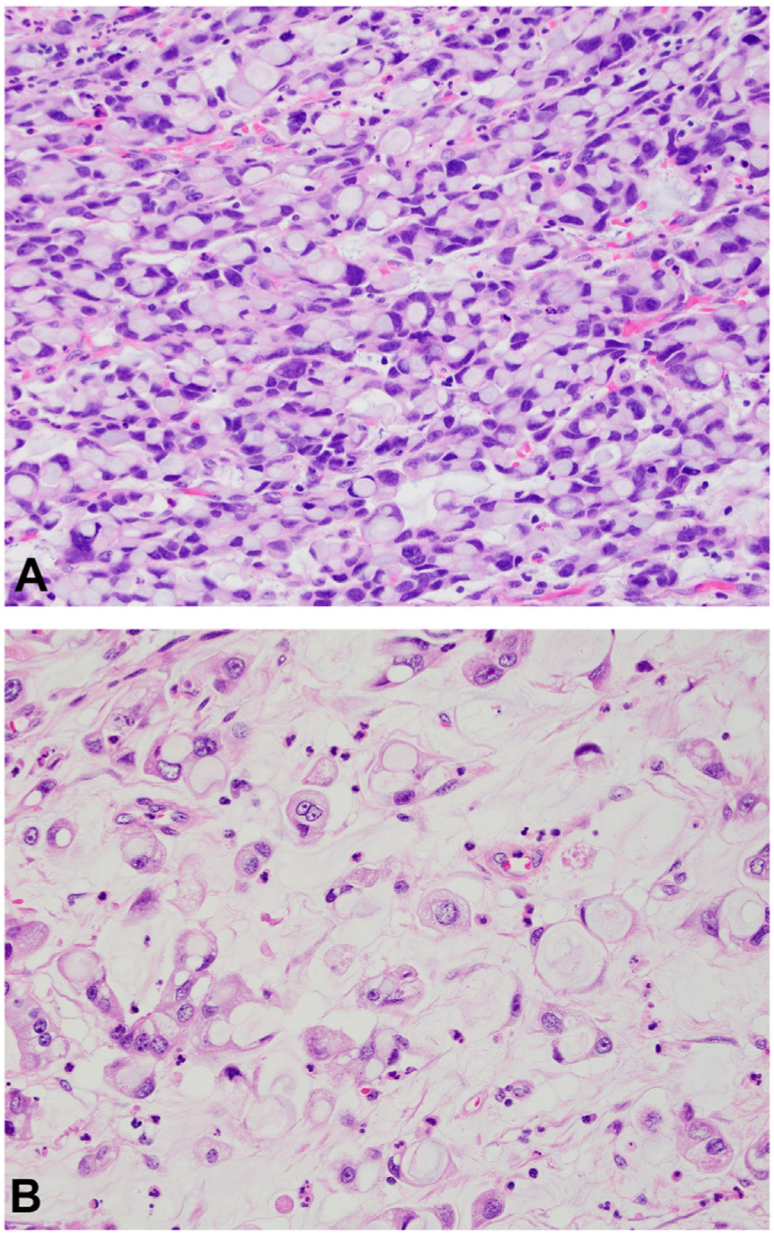

Fig. 1.

Poorly differentiated adenocarcinoma of the bladder following augmentation cystoplasty with (A) diffuse signet ring cell features and (B) extraluminal mucin (H&E).

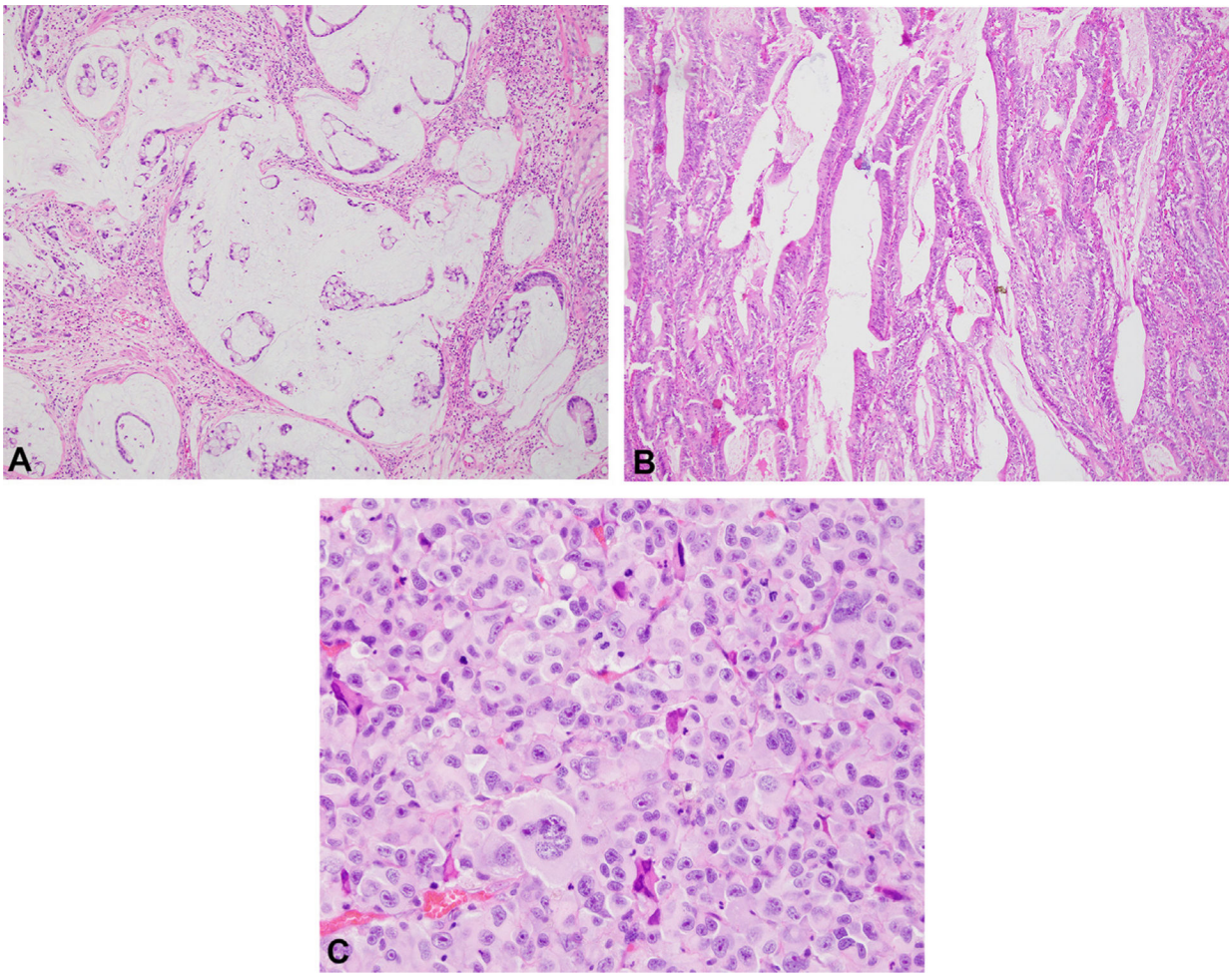

Fig. 2.

Poorly differentiated adenocarcinoma of the bladder following augmentation cystoplasty with (A) extensive mucinous features (tumour cells within pools of extraluminal mucin) and host inflammatory response; (B) enteric/villous architecture; and (C) large cell undifferentiated morphology characterised by large cells with pleomorphic nuclei (H&E).

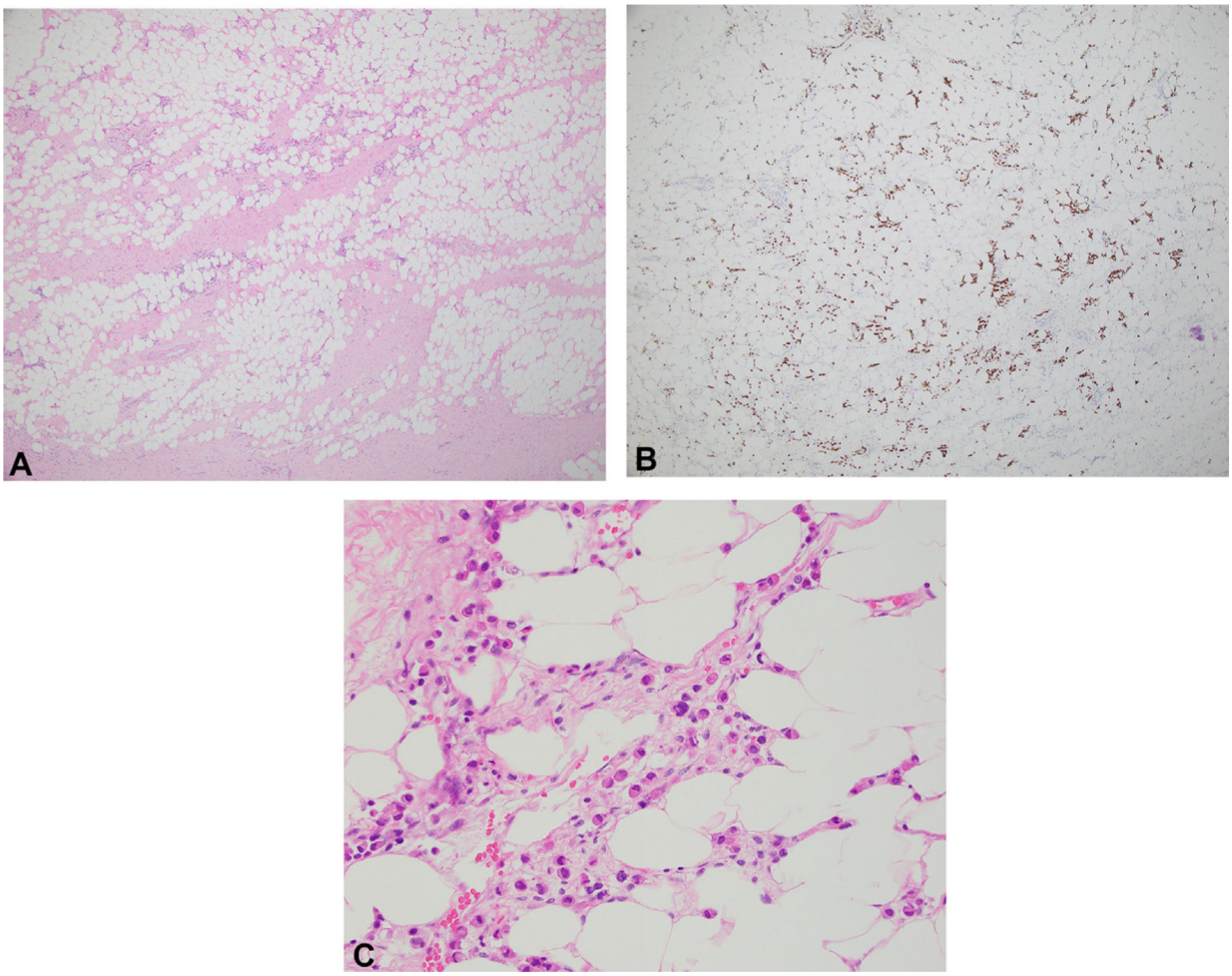

Fig. 3.

Poorly differentiated adenocarcinoma of the bladder following augmentation cystoplasty with (A) extensive plasmacytoid and focal signet ring cell features (tumour cells were small and mimicked chronic inflammation) (H&E); (B) extensive plasmacytoid and focal signet ring cell features (tumour cells were small and mimicked chronic inflammation) (AE1/AE3); and (C) extensive plasmacytoid and focal signet ring cell features (H&E).

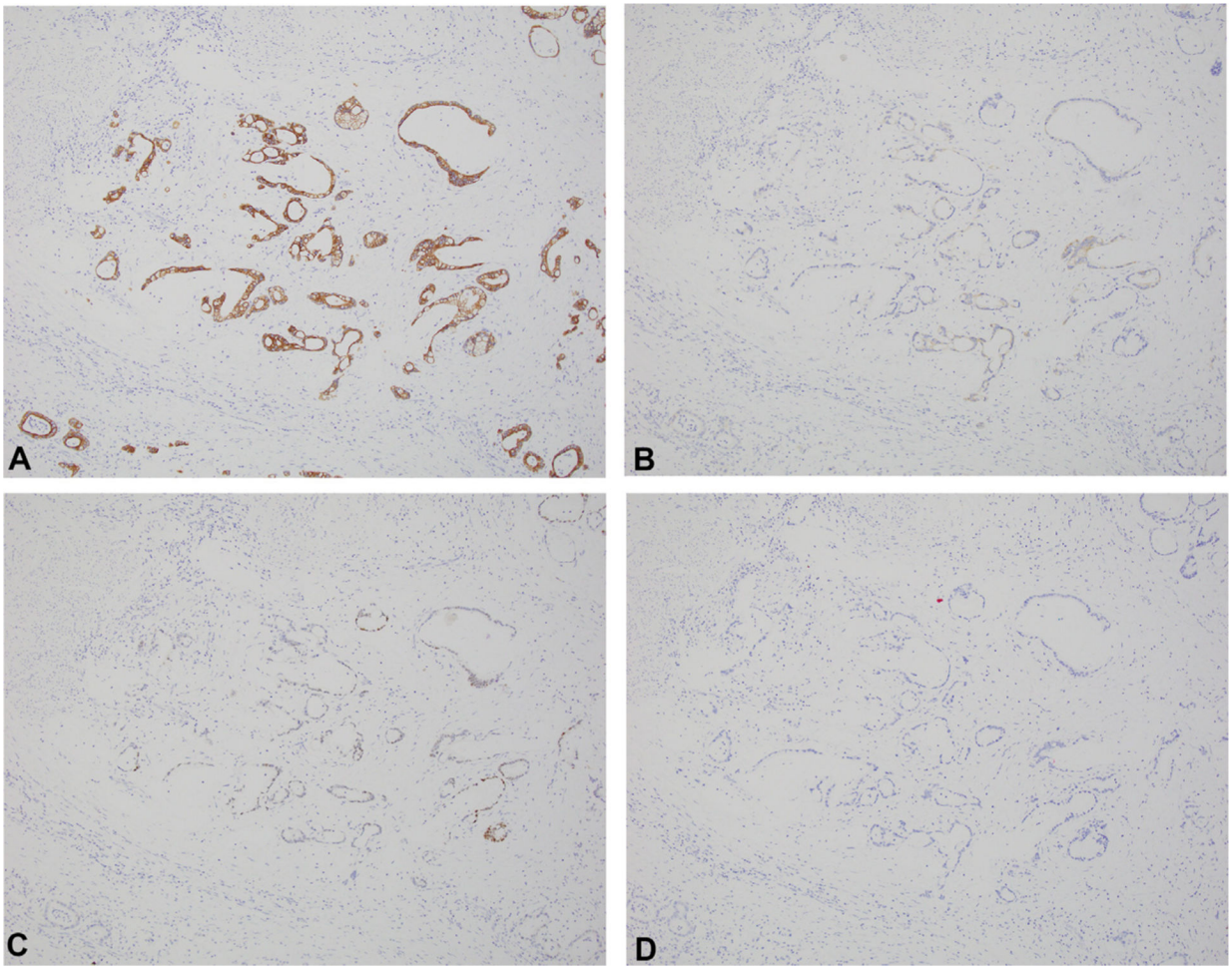

Fig. 4.

Poorly differentiated adenocarcinoma of the bladder following augmentation cystoplasty showing expression of (A) CK7, (B) CK20, (C) CDX2, and (D) GATA3.

Table 1

Summary of clinicopathological features

Type of augmentation	Gender, age (years)[a]	Specimen type	Stage	Morphological features	Follow-up (months)	Immunohistochemistry
Gastrocystoplasty	F, 27	Cystectomy	pT3aN2	Adenocarcinoma with diffuse signet ring and plasmacytoid features	Discharged to hospice (7 months)	GATA3−
Gastrocystoplasty	F, 28	Cystectomy	pT4aN2	Adenocarcinoma with diffuse signet ring and mucinous features	Alive with disease (11 months)	CK7+, CK20+, CDX2+, GATA3−
Gastrocystoplasty	F, 29	Cystectomy	pT3aN2	Adenocarcinoma with diffuse signet ring cell features	Alive with no evidence of disease recurrence (10 months)	None
Gastrocystoplasty	F, 40	Cystectomy	pT3aN2	Adenocarcinoma with diffuse signet ring and mucinous features; neuroendocrine carcinoma in one lymph node	Alive with disease (10 months)	Synaptophysin+, chromogranin+
Gastrocystoplasty	M, 67	TURBT	N/A	Large cell undifferentiated	Died of disease (13 months)	CK7+, CK20−
Colocystoplasty	F, 48	Partial cystectomy	N/A	Adenocarcinoma with focal signet ring cell features	Lost to follow-up (3 months)	None
Colocystoplasty	M, 72	Partial cystectomy	N/A	Adenocarcinoma with focal signet ring cell features	Unavailable	None
Colocystoplasty	F, 87	Cystectomy	pT3aN1a	Adenocarcinoma with enteric/villous, focal signet ring and mucinous features; subsequent rectal adenocarcinoma with different morphological features and immunohistochemical profile	Lost to follow-up (5 months)	p63+, GATA3−, CDX2−, CK20−
Ileocystoplasty	M, 32	Cystoprostatectomy	pT3bN1a	Adenocarcinoma with diffuse signet ring and plasmacytoid features	Discharged to hospice (4 months)	CK20+, CDX2+, CK7−, GATA3−, p63−, synaptophysin−, chromogranin−
Ileocystoplasty	M, 39	TURBT	N/A	Adenocarcinoma with focal signet ring cell features	Died of disease (1 month)	CK7+, CK20+, CDX2+, synaptophysin+, chromogranin+

F, female; M, male; N/A not applicable; TURBT, transurethral resection of bladder tumour.

[a]Age at diagnosis.