JOURNAL OF ENDOUROLOGY
Volume 34, Number 2, February 2020

Pp. 203–208
DOI: 10.1089/end.2019.0378



# *In Vivo* Renal Tubule pH in Stone-Forming Human Kidneys

Michael S. Borofsky, MD,[1,*] Rajash K. Handa, PhD,[2] Andrew P. Evan, PhD,[2] James C. Williams Jr. PhD,[2] Sharon Bledsoe,[2] Fredric L. Coe, MD,[3] Elaine M. Worcester, MD,[3] and James E. Lingeman, MD[1]

## Abstract

***Introduction:*** There is evidence that patients with a history of ileostomies, who produce acidic urine and form uric acid or calcium oxalate stones, may plug some collecting ducts with calcium phosphate (CaP) and urate crystals. This is a paradoxical finding as such minerals should not form at an acid pH. One possible explanation is the presence of acidification defects due to focal damage to inner medullary collecting duct and Bellini duct (BD) cells. We sought to further investigate this hypothesis through direct measurement of ductal pH in dilated BDs in patients with ileostomies undergoing percutaneous nephrolithotomy (PCNL) for stone removal.

***Methods:*** After obtaining institutional review board approval, we used a fiber-optic pH microsensor with a 140-$\mu$m-diameter tip to measure intraluminal pH from the bladder, saline irrigant, and dilated BDs of patients undergoing PCNL.

***Results:*** Measurements were taken from three patients meeting inclusion criteria. Measured pH of bladder urine ranged from 4.97 to 5.58 and pH of saline irrigant used during surgery ranged from 5.17 to 5.75. BD measurements were achieved in 11 different BDs. Mean intraductal BD pH was more than 1 unit higher than bulk urine ($6.43 \pm 0.22$ *vs* $5.31 \pm 0.22$, $p < 0.01$).

***Conclusions:*** This is the first evidence for focal acidification defects within injured/dilated BDs of human kidneys producing highly acidic bulk phase urine. These results may help explain the paradoxical finding of CaP and urate plugs in dilated ducts of patients with stone-forming diseases characterized by highly acidic urine.

**Keywords:** nephrolithiasis, pH, Bellini duct, kidney stone, tubule, pathogenesis

## Introduction

Although kidney stone formers who have had ileostomy[1] or extensive small bowel resection[2] produce highly acidic urine, they can deposit crystals in their renal papillae that form only in alkaline environments. The presence of hydroxyapatite crystals within the lumens of inner medullary collecting ducts (IMCDs) and urates (sodium acid urate and ammonium acid urate) in the Bellini ducts (BDs) of such patients has been previously demonstrated even though measured bladder urine pH was too low for stability of such crystals. Their presence therefore implies that acidification can become defective in individual IMCD and BD of kidneys, otherwise intact, in that the majority of nephrons produce highly acidic urine.

To prove this conjecture, one needs to measure fluid pH directly in such tubules. We sought to further investigate this hypothesis using a pH sensor, small enough to enter the BD lumens.[3]

## Methods

After institutional review board (IRB) approval, three patients with ileostomies undergoing planned percutaneous nephrolithotomy (PCNL) for the treatment of large renal stones met inclusion criteria for study enrollment. A fourth patient was also consented, but pH readings proved technically impossible to make and therefore not further reported. Informed consent was obtained from each patient before undergoing the planned procedure. Percutaneous

[1]Department of Urology, Indiana University Health at Methodist Hospital, Indianapolis, Indiana.
[2]Department of Anatomy and Cell Biology, Indiana University School of Medicine, Indianapolis, Indiana.
[3]Section of Nephrology, Department of Medicine, University of Chicago, Chicago, Illinois.
*Current affiliation: Department of Urology, University of Minnesota, Minneapolis, Minnesota.

access, collecting system mapping, and stone removal were performed by a single surgeon (J.E.L.) as previously described.[4] Patients were exclusively given intravenous physiologic saline during surgery to minimize any potential confounding effect that lactated Ringers solution might have on the serum and urine acid base status.

Upon completion of stone removal from the collecting system, the kidney was meticulously inspected for evidence of dilated BDs from which to record intraluminal urine pH. The pH-1 microsystem (PreSens, Regensburg, Germany), a fiber-optic phase detection system with 140-$\mu$m-diameter sensor, was used to measure urine pH within these dilated ducts. This optical pH sensing system has demonstrated success in accurately measuring pH values in blood volumes as low as 15 $\mu$L, and has been used previously to measure BD pH in a porcine model.[3,5,6] Before use, all pH sensors were calibrated and then sterilized with ethylene oxide.[3] In all cases, pH measurements were first taken from catheterized bladder urine collected at the beginning of the procedure without the use of irrigant. Additional measurements were taken from the physiologic saline irrigant itself, used to facilitate visualization through the rigid and flexible nephroscope used during the procedure. Once these measurements had been made, the standard surgical procedure began.

Percutaneous access to the kidney was achieved and flexible nephroscopy was performed. Upon identification of an accessible dilated BD (terminal collecting duct), the pH sensor was advanced through the inner lumen of a 5F open-ended catheter and directed until the entirety of the fiber-optic tip (3 mm) was fully within the duct (Fig. 1). Saline irrigation was suspended before and during pH measurement to minimize confounding of the readings. Care was taken to ensure that the sensor did not come into contact with tissue to minimize the likelihood of damage to the fragile sensor tip. Extreme stability was required during each measurement to keep the sensor tip within the duct to obtain a stable pH reading. To help achieve this, patient respirations were suspended during the measurement period. In the event a plateau in pH reading had not been reached before the sensor being removed from the duct, a relatively narrow pH range could still be determined.[3] In such cases, the mean of the range was used for data analysis purposes.

Papillary biopsy specimens were obtained from accessible papillae after pH measurement in each case as approved by the IRB Committee for Indiana University (No. 98-073). There was no significant hemorrhage or other complications related to the biopsy itself. Biopsy specimens were then processed and prepared in a manner similar to our prior research on papillary anatomy of ileostomy and short gut patients with nephrolithiasis, using hematoxylin and eosin for routine histologic analysis and Yasue metal substitution for calcium histochemistry.[1,2] Biopsy specimens were examined to determine the histologic changes of the terminal collecting ducts, including mineral type, completeness of plugging, alterations of lining cells, and level of inflammatory changes in the adjacent interstitium to determine if they showed similar changes to comparable patients from our prior research.[1,2]

All patients underwent routine serum basic metabolic testing as well as two 24-hour urine collections, the results of which were averaged for all measured values. The exception to this is patient 1 who suffered from a urinary tract infection with a urease splitting bacteria during one of the collections. It was subsequently treated with antibiotics leaving results from only one collection suitable for inclusion. Patients were asked to stop taking stone preventative medications during the time of metabolic evaluation and through surgery. Stones were collected individually when feasible and analyzed by both infrared spectroscopic analysis (Beck Analytical Services, Indianapolis, IN) and micro-CT.[7]

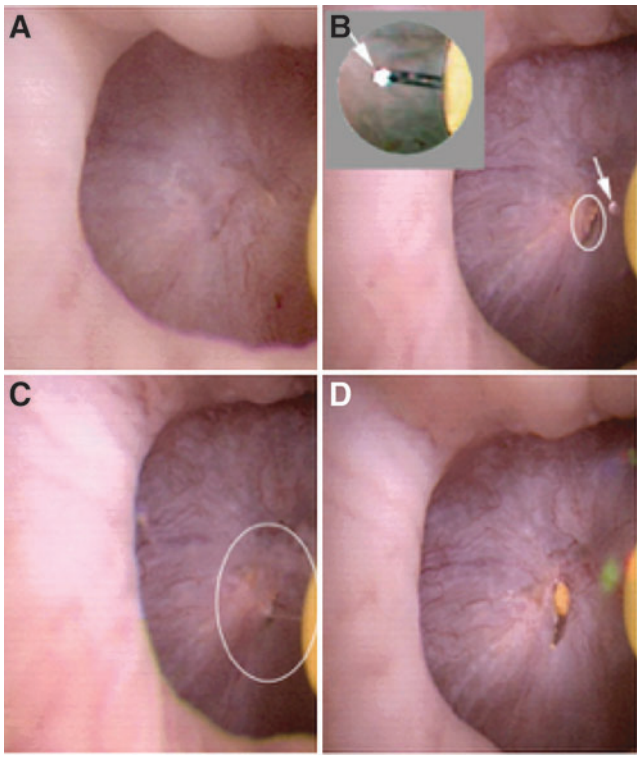


**FIG. 1.** Example of pH microsensor taking measurement from within a dilated BD. **(A)** The *yellow tubing* of the open-ended catheter is seen in the *bottom right*. **(B)** The pH microsensor is advanced so that its tip is protruding from the catheter (*arrow* and *inset*). A dilated duct is identified (*circle*). **(C)** The pH probe is guided into the duct (*circle*) and held there until a stable reading is achieved. **(D)** In this instance, a holmium laser (*green light*) was used after measuring ductal pH to expose and facilitate removal of an underlying ductal plug (*yellow deposit*). BD, Bellini duct.

Confirmatory analysis was performed to determine whether the physical contact of the pH microsensor with a tissue surface interferes with sensor accuracy. To do this, caps from 2-mL cryostat plastic vials were filled with physiologic saline, pH buffer solutions (pH 5, 6, or 7), or urine extracted from porcine bladder. The fiber-optic pH microsensor assembly was attached to a micromanipulator so that the tip of the microsensor could be moved in the $x$, $y$, and $z$ planes. Papillary tissue was excised from the kidney of euthanized adult farm pigs, bathed with saline, and blotted dry. These tissue samples were obtained from a colleague who had euthanized pigs as part of a separate study, and thus, Institutional Animal Care and Use Committee (IACUC) approval was not

necessary. A piece of papillary tissue was subsequently submerged into each of the solution-filled caps. The pH microsensor was introduced into the solution under microscope guidance and then advanced to contact the papillary tissue with sufficient force to compress the sensor's matrix on the fiber-optic tip. A total of 11 calibrated microsensors were evaluated with pH readings continuously recorded before, during, and after the sensor's contact with the tissue surface. The microsensor tip was rinsed with distilled water after pH readings were acquired in a test solution. The average pH value recorded by an individual microsensor in each of the test solutions was calculated for statistical analysis.

### *Statistics*

Statistical analysis was performed using IBM:SPSS Statistics version 22 (Armonk, NY). Continuous measures were compared between groups using Student's *t*-tests, and categorical measures were compared between groups using Fisher's exact tests with $p < 0.05$ being considered statistically significant.

### *Study approval*

All participants gave informed consent before participation in this study, which was approved by the IRB of Indiana University.

## Results

We studied three patients with ileostomies (Table 1), during PCNL, for stone removal. Patient 3 had a ureteropelvic junction obstruction on the right side, which was treated with antegrade endopyelotomy at the time of PCNL. As expected, stones were calcium oxalate and uric acid (Table 1). Measurements of ductal pH were effectively obtained in all three cases. Our technique is illustrated in Figure 1. Papillary appearance and retrograde pyelography from each patient are provided as Supplementary Figures.

Routine laboratory results (Table 1) showed variably reduced renal function, remarkable acid bladder urine pH, consistent uric acid supersaturation, and no trace of calcium

Table 1. Patient Demographics and Results of Biochemical Tests on Serum, Urine, and Stones

| *Patient demographics* | *Patient 1* | *Patient 2* | *Patient 3* |
|---|---|---|---|
| Sex | Female | Female | Female |
| Pathology | UC, ileostomy | UC, ileostomy | UC, ileostomy |
| Age at first stone (years) | 40s | 55 | 67 |
| Prior stones (*n*) | 3 | >10 | 3 |
| Age at biopsy (years) | 72 | 64 | 73 |
| SWL (*n*) | 2 | 2 | 1 |
| PCNL (*n*) | 0 | 7 | 0 |
| Open (*n*) | 0 | 0 | 0 |
| URS (*n*) | 1 | 0 | 1 |
| Total (*n*) | 3 | 9 | 2 |
| Weight (kg) | 82.1 | 72.5 | 72.7 |
| Calcium (mg/dL) | 10.5 | 9.6 | 9.5 |
| Phosphorus (mg/dL) | 3.94 | | 3.8 |
| Creatinine (mg/dl) | 0.82 | 0.96 | 1.45 |
| Uric acid (mg/dL) | 6.0 | 7.3 | 5.0 |
| Magnesium (mg/dL) | 2.1 | | 1.8 |
| Sodium (mmol/L) | 137 | 139 | 141 |
| Potassium (mmol/L) | 4.9 | 4.2 | 4.5 |
| Chloride (mmol/L) | 101 | 102 | 105 |
| eGFR (mL/min/1.73 $m^2$) | 80 | 80 | 40 |
| Volume (L) | 2.82 | 0.67 | 1.50 |
| pH | 4.86 | 5.02 | 5.17 |
| Citrate (mg/day) | 661 | 95 | 66 |
| Calcium (mg/day) | 130 | 108 | 37 |
| Oxalate (mg/day) | 34 | 21 | 22 |
| Sodium (mmol/day) | 150 | 37 | 66 |
| Uric acid (mg/day) | 650 | 340 | 360 |
| Ammonium (mmol/day) | 37 | 38 | 15 |
| Sulfate (meq/day) | 55 | 16 | 26 |
| SS uric acid | 1.93 | 3.84 | 1.60 |
| SS calcium oxalate | 2.61 | 11.71 | 2.14 |
| SS calcium phosphate | 0.03 | 0.45 | 0.04 |
| Stone analysis (right kidney) | 100% UA | 50%–80% COM, 20%–50% UA | 100% UA |
| Stone analysis (left kidney) | | 90%–95% UA, 5%–10% COM | 100% UA |

COM = Calcium Oxalate Monohydrate; eGFR = estimated glomerular filtration rate; SWL = extracorporeal shockwave lithotripsy; PCNL = percutaneous nephrolithotomy; SS = supersaturation; UA = Uric Acid; UC = Ulcerative Colitis; URS = Ureteroscopy.

phosphate (CaP) supersaturation. Patient 1 had elevated serum calcium but normal parathyroid hormone.

Tubule pH values were obtained (Fig. 2) for six BDs of patient 1. In each BD measurement, tubular fluid pH far exceeded the pH of bladder urine. In patient 2, similar results were found in three BDs (Fig. 2). In that patient, we could document not only acidic urine pH of bladder urine but also in samples of fluid from two renal calices, including the one within which the papilla lay. Finally, in patient 3, we obtained two BD measurements along with bladder urine. Universally, BD pH exceeded bladder urine and, when available, caliceal pH. Bladder urine pH ranged between 4.97 and 5.58, and mean bladder pH for the three patients was $5.31 \pm 0.22$. BD pH (Fig. 2) ranged between 5.97 and 6.72, and mean BD pH was $6.43 \pm 0.22$.

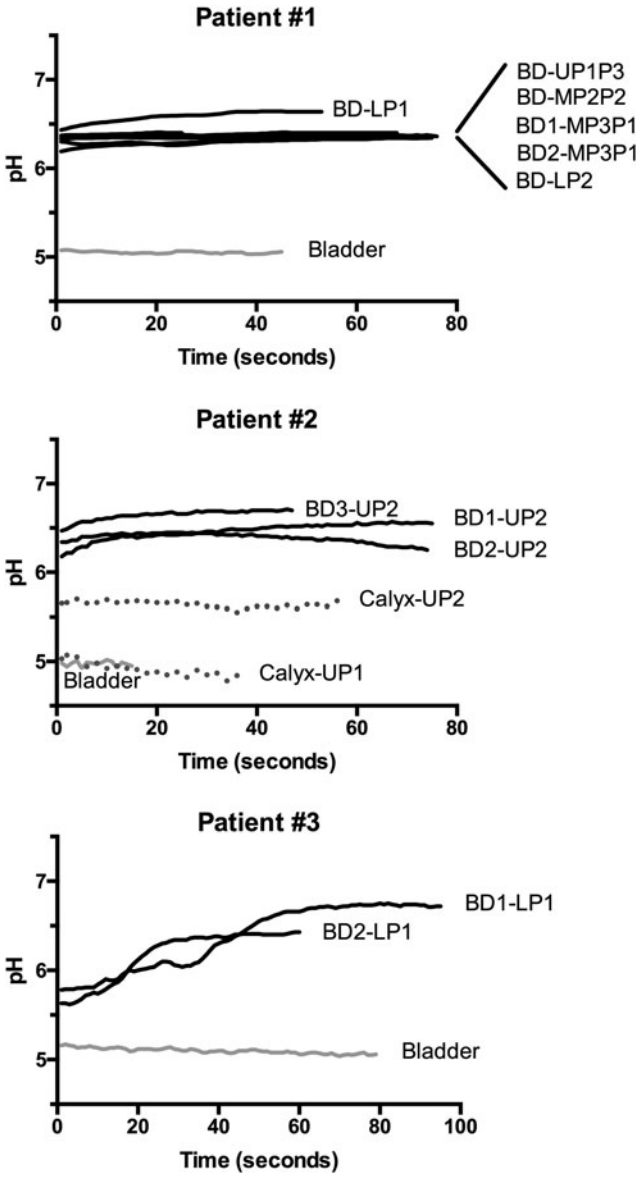


**FIG. 2.** pH microsensor tracings from bladder (*red line*), calix (*green dotted line*), and dilated terminal collecting ducts (*black lines*). Each BD where a measurement was performed is denoted in the legend based on polar location, numbered calix, and numbered papilla (i.e., MP3P1—interpolar, 3rd calix, first papilla). This nomenclature is being used for the purpose of operative recording, more than a formal anatomic mapping system.

Renal papillary biopsy histopathology was identical to the ileostomy patients we have reported elsewhere.[1,2] Biopsies from patients 1 and 2 (Fig. 3) show collecting duct dilation, loss of lining cells, mineral deposits, and surrounding moderate interstitial fibrosis (Fig. 3A). Areas of Randall's plaque were easily identified. A papilla from patient 2 illustrates the more severe histopathologic changes that can occur in ileostomy patients (Fig. 3C) that include extensive dilation of papillary collecting ducts with intraluminal CaP deposits and loss of lining cells, widespread and severe interstitial fibrosis, and multiple sites of Randall's plaque.

## Discussion

These are the first reported measurements of pH in lumens of individual human collecting ducts. In this group of ileostomy patients with highly acidic urine, we found that pH values within damaged/dilated BD were on average >1 pH unit higher than in bulk urine. These highly novel measurements demonstrate heterogeneous acidification within stone-forming kidneys.

The results may explain the paradoxical presence of apatite and urate plugs in kidneys producing highly acidic urine. The patients included in our study were similar to those in our prior studies of ileostomy stone formers, both in terms of serum and urine chemistries as well as histologic tissue analysis.[1,2] In addition, all patients had endoscopically demonstrable abnormally dilated terminal collecting ducts scattered about their papillae as we have found in larger prior patient series (Supplementary Figs. S1–S3). In other words, our findings here may well apply widely to such stone formers.

Possibly the ducts we studied were damaged by crystal plugging. However, the crystals that caused the injury could not have been apatite or urate because before damage, the pH would have been too low. We postulate that uric acid crystals formed and damaged IMCD and BD cells. The damage led to rising tubule fluid pH. Thereupon, uric acid species dissolved and reformed as urate salts, and apatite crystals formed *de novo*. Our data do not permit testing of this proposed scheme beyond the idea that crystal types changed between the initial insult and condition in which we made our measurements. However, our methods do detect the urates and apatites with high specificity, so we can be sure they are indeed present as we have described.

Another possible cause might be extracorporeal shockwave lithotripsy (SWL). In pig experiments,[8] we demonstrated that SWL produced a marked loss of normal nephron acidification by injury mainly to thick ascending limbs, permitting delivery of large volumes of alkaline tubule fluid downstream into collecting ducts. Possibly alkaline apatite or urate crystals formed during post-SWL periods. All of these patients had prior SWL treatments although the specific details of these procedures, including stone location in the kidney, were unknown.

Whatever the details of these crystal formations, dilated collecting ducts have histologic evidence of tubular epithelial destruction, and fibrosis of the interstitium in the region

around it.[9,10] It is thus plausible that such damaged collecting ducts would not acidify tubular fluid normally, creating a microenvironment that would facilitate the deposition of CaP and urate salts.[11]

We recognize that there are a number of potential limitations to our study. Perhaps the greatest is the inability to use the pH sensor to measure the acidity of a normal-sized BD, which at 100 to 200 $\mu$m is near the same size as the pH microsensor tip (140 $\mu$m).[12] To our knowledge, pH microsensors small enough to enter a normal-sized BD are not commercially available. Furthermore, even the latest generation digital nephroscopes used during PCNL do not feature the necessary magnification and resolution to readily identify a normal-sized BD.

Another potential limitation is our inability to visualize the probe tip during measurement within the ducts, raising the possibility that the probe touched the tubule cells or pushed through the BD cells into the interstitium, creating in either case a measurement artifact. However, we do not believe that this occurred as it would have led to bleeding, none of which was seen intraoperatively or upon video review of all available measurements. Nonetheless, to estimate probable errors from tissue contact, we performed ancillary testing of 11 microsensors in solutions containing excised porcine renal papillary tissue. Continuous measurements were taken before, during, and after intentionally contacting tissue with the sensor. We found a mean deviation in pH of 0.1 pH units or less (Table 2). Therefore it is unlikely that our pH measurements are due to artifacts created by contact with the duct epithelium.

## Conclusion

With the aid of a microscopic pH sensor, we were able to determine that pH values within individual dilated BDs dramatically differ from that of acidic bulk urine in ileostomy patients. These findings are the first to directly demonstrate focal defects in urinary acidification mechanisms within damaged portions of the human kidney. Furthermore, these more alkaline pH values within the diseased portions of the papillae help explain the presence of apatite deposits in certain stone-forming diseases characterized by markedly acidic urinary pHs where apatite would be unexpected to form.

## Authors' Contributions

M.S.B.: data analysis and article preparation. R.K.H.: conducted experiments, data analysis, and article preparation. A.P.E.: research design and data analysis. J.C.W.:

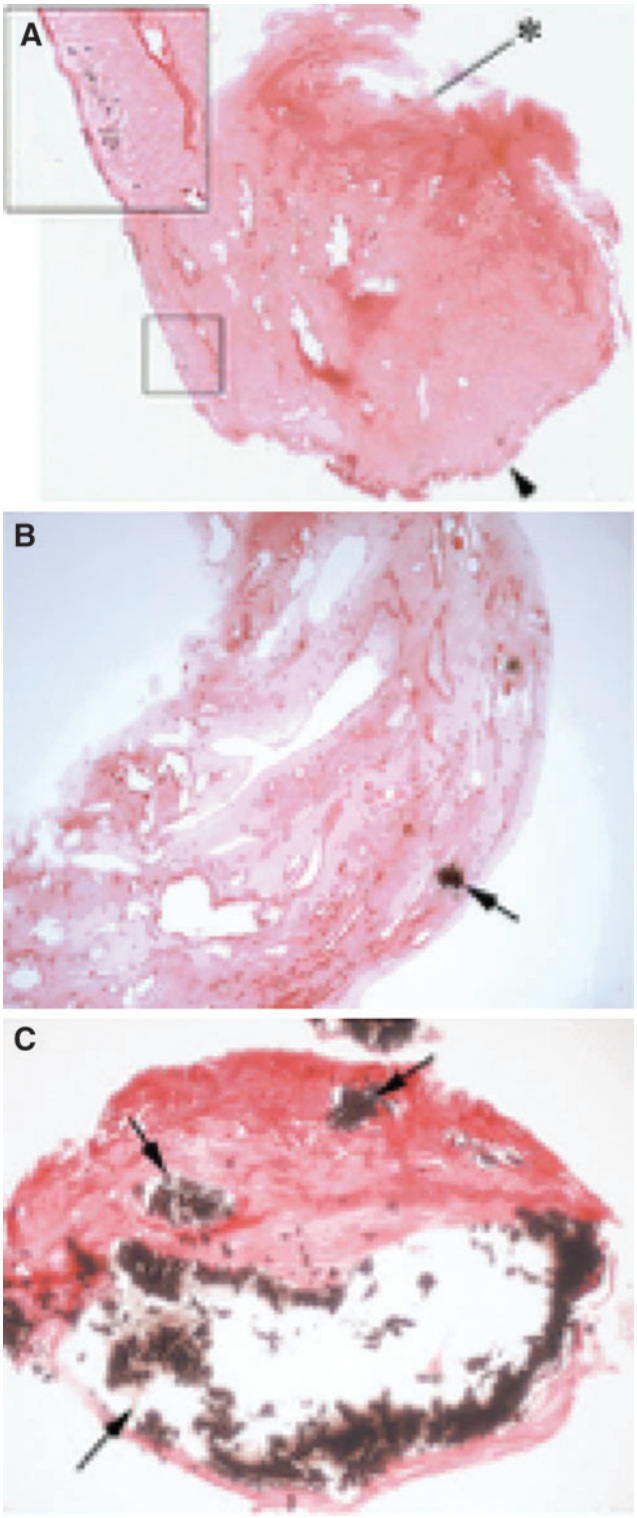


**FIG. 3.** Papillary biopsies from ileostomy patients 1 and 2. **(A)** The BD that was used to measure ductal pH (marked with an *asterisk*) from patient 1. It is slightly dilated, lacks lining cells, contains some mineral, and surrounded by a moderate level of interstitial fibrosis. The area marked by a *square* is magnified as an insert in the *upper left* to show a site of Randall's plaque. **(B)** Obtained from an adjacent papilla of patient 1 from the site of pH measurements and shows the moderate types of histopathologic changes illustrated in **(A)** and previously reported in ileostomy patients. Two sites of intratubular calcium deposit in IMCD are designated with *arrows*. **(C)** An adjacent papilla from patient 2 and shows the more severe histopathologic changes that occur in ileostomy patients. These changes include varying degrees of dilation (at times extensive) of IMCD with intraluminal calcium phosphate deposits (*arrows*) and loss of lining cells, widespread and severe interstitial fibrosis, and multiple sites of Randall's plaque. IMCD, inner medullary collecting duct.

Table 2. Results of Ancillary pH Validation Experiment Determining Influence of Tissue Interaction on pH Measurement

| | *Saline* | *pH 5 buffer* | *pH 6 buffer* | *pH 7 buffer* | *Pig urine* |
|---|---|---|---|---|---|
| Solution pH | 6.14 ± 0.34 | 4.83 ± 0.16 | 5.88 ± 0.04 | 6.69 ± 0.04 | 6.30 ± 0.36 |
| Change in pH upon contact with tissue | –0.10 ± 0.17 | 0.07 ± 0.03* | –0.05 ± 0.12 | –0.09 ± 0.15 | –0.02 ± 0.01* |
| No. of pH sensors tested | 8 | 7 | 6 | 5 | 4 |

*$P < 0.05$ using an unpaired Student *t*-test.

conducted experiments, data analysis, and article preparation. S.B.: conducted experiments and data acquisition. F.L.C.: research design and data analysis. E.M.W.: data analysis and article preparation. J.E.L.: research design, conducted experiments, data analysis, and article preparation.

### Author Disclosure Statement

The authors have declared that no conflict of interest exists.

### Funding Information

Research reported in this publication was supported by NIDDK P01DK056788.

### Supplementary Material

Supplementary Figure S1
Supplementary Figure S2
Supplementary Figure S3

### References

1. Evan AP, Lingeman JE, Coe FL, et al. Intra-tubular deposits, urine and stone composition are divergent in patients with ileostomy. Kidney Int 2009;76:1081–1088.
2. Evan AP, Lingeman JE, Worcester EM, et al. Renal histopathology and crystal deposits in patients with small bowel resection and calcium oxalate stone disease. Kidney Int 2010;78:310–317.
3. Handa RK, Lingeman JE, Bledsoe SB, Evan AP, Connors BA, Johnson CD. Intraluminal measurement of papillary duct urine pH, in vivo: A pilot study in the swine kidney. Urolithiasis 2016;44:211–217.
4. Kuo RL, Lingeman JE, Evan AP, et al. Endoscopic renal papillary biopsies: A tissue retrieval technique for histological studies in patients with nephrolithiasis. J Urol 2003; 170(6 Pt. 1):2186–2189.
5. Oellermann M, Portner HO, Mark FC. Simultaneous high-resolution pH and spectrophotometric recordings of oxygen binding in blood microvolumes. J Exp Biol 2014;217(Pt. 9):1430–1436.
6. Kocincova AS, Borisov SM, Krause C, Wolfbeis OS. Fiber-optic microsensors for simultaneous sensing of oxygen and pH, and of oxygen and temperature. Anal Chem 2007;79:8486–8493.
7. Williams JC, Jr., McAteer JA, Evan AP, Lingeman JE. Micro-computed tomography for analysis of urinary calculi. Urol Res 2010;38:477–484.
8. Evan AP, Coe FL, Connors BA, Handa RK, Lingeman JE, Worcester EM. Mechanism by which shock wave lithotripsy can promote formation of human calcium phosphate stones. Am J Physiol Renal Physiol 2015;308:F938–F949.
9. Evan AP, Coe FL, Gillen D, Lingeman JE, Bledsoe S, Worcester EM. Renal intratubular crystals and hyaluronan staining occur in stone formers with bypass surgery but not with idiopathic calcium oxalate stones. Anat Rec (Hoboken) 2008;291:325–334.
10. Worcester EM, Evan AP, Coe FL, et al. A test of the hypothesis that oxalate secretion produces proximal tubule crystallization in primary hyperoxaluria type I. Am J Physiol Renal Physiol 2013;305:F1574–F1584.
11. Coe FL, Evan AP, Lingeman JE, Worcester EM. Plaque and deposits in nine human stone diseases. Urol Res 2010; 38:239–247.
12. Peter K, University of C, Department of A. Untersuchungen über Bau und Entwicklung der Niere (Investigation of the construction and development of the kidney). Jena, Gernamy: Verlag von G. Fischer, 1927.

Address correspondence to:
*Michael S. Borofsky, MD*
*Department of Urology*
*University of Minnesota*
*420 Delaware Street SE, Box 394 Mayo*
*Minneapolis, MN 55391*

*E-mail:* mborofsk@umn.edu

**Abbreviations Used**

BD = Bellini duct
CaP = calcium phosphate
eGFR = estimated glomerular filtration rate
IMCD = inner medullary collecting duct
IRB = institutional review board
PCNL = percutaneous nephrolithotomy
SS = supersaturation
SWL = extracorporeal shockwave lithotripsy