Authors have no conflicts to disclose

Multi-focal *Clostridium difficle* Osteomyelitis in a Patient with Sickle Cell Anemia: Case Presentation and Literature Review

Multi-focal *Clostridium difficle* Osteomyelitis

Jaffar A. Al-Tawfiq, MD, FACP[1,2,3,4,*] jaffar.tawfiq@aramco.com, Mohammad Babiker, MD[1,3,4],

[1]Specialty Internal Medicine and Quality Department, Johns Hopkins Aramco Healthcare, Dhahran, Saudi Arabia

[2]Indiana University School of Medicine, Indiana, USA

[3]Johns Hopkins University School of Medicine, Baltimore, MD, USA

[4]General Internal Medicine Unit, Johns Hopkins Aramco Healthcare, Dhahran, Saudi Arabia

[*]Corresponding author at: P. O. Box 76, Room A-420B, Building 61, Dhahran Health Center, Saudi Aramco, Dhahran 31311, Saudi Arabia. Tel.: +96613-870-7794; fax: +96613-870-3790.

Abstract

This is the author's manuscript of the article published in final edited form as:

Al-Tawfiq, J. A., & Babiker, M. M. (2019). Multi-focal Clostridioides (Clostridium) difficile osteomyelitis in a patient with sickle cell anemia: Case presentation and literature review. Diagnostic Microbiology and Infectious Disease, 114915. https://doi.org/10.1016/j.diagmicrobio.2019.114915

Clostridium difficile infection manifests as intestinal infections, namely pseudomembranous colitis. The occurrence of extra-intestinal disease is thought to be rare with a rate of 1.08% of 2034 isolates of *C. difficile* and an incidence of 4/100,000 admissions. *C. difficile* had been rarely associated with osteomyelitis. Here, we report the occurrence of *C. difficile* infection in a patient with sickle cell disease. The patient had multiple surgeries and a prolonged antimicrobial therapy to achieve a cure. The patient had *C. difficile* infection of native bone and of a prosthetic joint. The patient received prolonged therapy with amoxicillin-clavulanic acid and metronidazole and she remained free of *C. difficile* infection for three years off antibiotics.

Keywords: *Clostridium difficle*; Osteomyelitis; Sickle cell anemia

Introduction:

Clostridium difficile is usually associated with intestinal infections, namely pseudomembranous colitis. *Clostridium difficile* colitis is an important healthcare associated gastrointestinal infection. There is limited data on the prevalence or incidence of *C. difficile* infection in Saudi Arabia. In one study, the annual incidence rates of *C. difficile* infections were 1.2 and 0.9 per 1000 discharges, and 2.4 and 1.7 per 10,000 patient days in 2007 and 2008, respectively (Al-Tawfiq and Abed 2010). The occurrence of extra-intestinal disease is thought to be rare. In one study, 21 (1.08%) of 2034 isolates were from extra-intestinal sources (García-Lechuz et al. 2001) with an incidence of 4/100,000 admissions (García-Lechuz et al. 2001). Of those cases, five patients had either brain abscess, bacteremia, foot infections, or chronic osteomyelitis (García-Lechuz et al. 2001). Other studies estimated extra-intestinal CDI to represents 0.17-0.6% of all CDI (Mattila et al. 2013; Gupta et al. 2014). In a review article, 33

cases of extra-intestinal infections were summarized (Jacobs et al. 2001; Morioka et al. 2017). Extra-intestinal manifestation of *C. difficile* had been reported in the form of bacteremia (Feldman et al. 1995; García-Lechuz et al. 2001; Jacobs et al. 2001; Libby and Bearman 2009; Choi et al. 2013; Shah et al. 2017), abscesses (Durojaiye et al. 2011; Ulger Toprak et al. 2016; Roy et al. 2017), and rarely had also been associated with osteomyelitis (Riley and Karthigasu 1982; Towns et al. 1984; Incavo et al. 1988; Pron et al. 1995; Gaglani et al. 1996; García-Lechuz et al. 2001; Bachmeyer et al. 2008; Al-Najjar et al. 2013; Curtis and Lipp 2013; Ranganath and Midturi 2013). Two previous cases of *C. difficile* chronic osteomyelitis were reported among sickle cell patients (Gaglani et al. 1996; Bachmeyer et al. 2008). Here, we report a case of multi-focal osteomyelitis caused by *C. difficile* and review the available literature in this regard.

Case Presentation:

The patient is a 28-year-old Saudi female with a history of sickle cell disease and was maintained on Hydroxyurea. She presented with pain in the right arm and right shoulder associated with fever of few days in duration. She did not have any other symptoms and initial temperature was 39.3^{0}C. Laboratory data showed a hemoglobin of 7gm/dl; total white cell count of 6.2 and platelets count was normal, Erythrocyte sedimentation rate (ESR) was 111 mm/hr, and C-reactive protein (CRP) 15 mg/dl. Chest X-ray did not show any infiltrates. She was empirically started on ceftriaxone on admission. Urine and several blood cultures came back negative.

The right shoulder pain got worse and a Magnetic Resonance Imaging (MRI) showed destructive osseous changes involving proximal part of the humerus and a large effusion (Figure

1). Joint aspiration was carried out and synovial fluid analysis showed 200 White Blood Cell (WBC) (80% neutrophil), 4900 Red Blood Cell (RBC), friable and anaerobic culture grew *C. difficile*. She was started on intravenous metronidazole but she developed severe nausea and vomiting and could not tolerate metronidazole despite anti-emetics. She was switched to intravenous vancomycin. She also developed pancytopenia, so hydroxyurea was discontinued pending recovery of the bone marrow. Right shoulder incision and drainage and irrigation was done.

Three weeks after starting vancomycin, she developed severe pain in her right leg with tenderness over the shin, and fever recurred. MRI of the right lower extremity showed sickle cell changes and possible osteomyelitis involving the mid-shaft of the right tibia (Figure 2). Debridement of the right tibia was done with creation of a bone window. The cultures from the right tibia tissue grew *C. difficile*. Metronidazole was added to vancomycin plus anti-emetics. The patient tolerated metronidazole well this time. Two months on a combination of vancomycin and metronidazole, she developed an abscess in the proximal right arm (figure 3); the abscess was evacuated down to the bicepital tendon. There was no communication with the humerus; nevertheless, several drills were made into the humerus and there was no pus or debris. Culture from abscess material grew *C. difficile*.

A month later she developed a right tibial osteomyelitis confirmed by bone curettes cultures to be a recurrence of *C. difficile* infection. She was treated with intravenous (IV) metronidazole 500mg IV and amoxicillin-clavulanic acid 1gm orally twice a day (BID) for 8 weeks. She had multiple debridement and irrigation and subsequent tissue cultures were negative. She was referred for hyperbaric oxygen therapy and had 46 sessions. She required a total of six months of treatment with metronidazole and vancomycin. Although, there is no

specific minimum inhibitory concentration (MIC) cut down for antimicrobial sensitivity, the organism was tested with E-test and the diameter of inhibition is shown in table 1.

Fourth month after completing therapy, the patient went to an out-off Kingdom hospital where she had bilateral total hip replacement for aseptic necrosis. Two weeks after the surgery, she had post-operative course complication in the form of early right total hip prosthetic *C. difficile* infection. She initially had a debridement of the hip and two weeks later she had hardware removal and a two-stage surgery. Patient was maintained on oral amoxicillin-clavulanic acid and metronidazole. She subsequently returned to our hospital with continue dozing from the right hip. Patient was maintained on oral amoxicillin-clavulanic acid and metronidazole for twelve months. She was followed for three years off antibiotics and she had no evidence of recurrence of *C. difficile* infection.

Discussion:

We presented a case of Sickle cell disease who had multi-focal osteomyelitis with *C. difficle* and had a prolonged and protracted illness followed by a complete cure with no evidence of relapse. The pure growth on several occasions and from different sites is strong evidence for the responsibility of *C. difficle* in the infectious process of this case.

The occurrence of *C. difficle* osteomyelitis rarely reported (Riley and Karthigasu 1982; Towns et al. 1984; Incavo et al. 1988; Pron et al. 1995; Gaglani et al. 1996; García-Lechuz et al. 2001; Bachmeyer et al. 2008; Al-Najjar et al. 2013; Curtis and Lipp 2013; Ranganath and Midturi 2013) and two previous cases were reported among sickle cell patients (Gaglani et al. 1996; Bachmeyer et al. 2008). In a study of 17 cases of extra-intestinal *C. difficle*, only 1 (5.9%) had osteomeylitis (García-Lechuz et al. 2001). The development of skin and

bone infections may follow traumatic injury (Jacobs et al. 2001) or secondary to bacteremia. In the current case, the patient had multifocal osteomyelitis and this suggest bacteremia followed by seeding of abnormal bone that may had been traumatized in the course of sickle cell disease. Although, the current patient did not have a documented bacteremia, such occurrence in relation to *C. difficle* had been reported (Libby and Bearman 2009). In another case, vertebral osteomyelitis followed an episode of *C. difficile* diarrhea suggesting a dissemination (Al-Najjar et al. 2013). However, the current case did not have diarrheal illness to suggest this mechanism for the multifocal osteomyelitis. In a case report, a prosthetic devise infection secondary to *C. difficle* occurred two years after diarrheal diseases (Al-Najjar et al. 2013) and thus a remote diarrheal *C. difficle* infection (CDI could not be excluded in the current patient.

In this case, the patient had a chronic relapsing multi-focal osteomyelitis of the tibia, shoulder, arm and of prosthetic hip. The infection was eventually cured after prolonged therapy with oral *amoxicillin*-clavulanic acid and metronidazole for twelve months from the last infection. The exact duration of therapy for *C. difficle* osteomyelitis is not known (Gaglani et al. 1996; Bachmeyer et al. 2008; Al-Najjar et al. 2013).

In conclusion, *C. difficle* osteomyelitis remains rare and this patient had a prolonged and protracted course of infection involving initially native bones and later involved prosthetic hip joint. Such patients may need prolonged antimicrobial therapy coupled with surgical debridement.

References:

Al-Najjar A, Al-Rawahi GN, Hoang LM, Kollmann TR. Clostridium difficile vertebral osteomyelitis. Pediatr Infect Dis J [Internet]. 2013 Sep [cited 2018 Apr 2];32(9):1030–2. Available from: http://www.ncbi.nlm.nih.gov/pubmed/23594589

Al-Tawfiq JA, Abed MS. Clostridium difficile-associated disease among patients in Dhahran, Saudi Arabia. Travel Med Infect Dis. 2010;8(6):373–6.

Bachmeyer C, Lionnet F, Gibeault M, Damsin J-P. Chronic multifocal osteomyelitis due to Clostridium difficile in an adolescent with sickle cell anemia. Pediatr Infect Dis J [Internet]. 2008 Oct [cited 2019 Feb 22];27(10):951–2. Available from: https://insights.ovid.com/crossref?an=00006454-200810000-00028

Choi J-L, Kim B-R, Kim J-E, Woo K-S, Kim K-H, Kim J-M, et al. A Case of *Clostridium difficile* Bacteremia in a Patient with Loop Ileostomy. Ann Lab Med [Internet]. 2013 [cited 2019 Feb 22];33(3):200. Available from: https://synapse.koreamed.org/DOIx.php?id=10.3343/alm.2013.33.3.200

Curtis L, Lipp MJ. Clostridium difficile infection of a prosthetic knee joint requiring amputation. Surg Infect (Larchmt) [Internet]. 2013 Feb [cited 2019 Feb 22];14(1):163–4. Available from: https://www.liebertpub.com/doi/10.1089/sur.2012.098

Durojaiye O, Gaur S, Alsaffar L. Bacteraemia and breast abscess: unusual extra-intestinal manifestations of Clostridium difficile infection. J Med Microbiol [Internet]. 2011 Mar 1 [cited 2019 Feb 22];60(3):378–80. Available from: http://jmm.microbiologyresearch.org/content/journal/jmm/10.1099/jmm.0.027409-0

Feldman RJ, Kallich M, Weinstein MP. Bacteremia due to Clostridium difficile: case report and review of extraintestinal C. difficile infections. Clin Infect Dis [Internet]. 1995 Jun [cited 2019 Feb 22];20(6):1560–2. Available from: http://www.ncbi.nlm.nih.gov/pubmed/7548512

Gaglani MJ, Murray JC, Morad AB, Edwards MS. Chronic osteomyelitis caused by Clostridium difficile in an adolescent with sickle cell disease. Pediatr Infect Dis J [Internet]. 1996 Nov [cited 2019 Feb 22];15(11):1054–6. Available from: http://www.ncbi.nlm.nih.gov/pubmed/8933563

García-Lechuz JM, Hernangómez S, Juan RS, Peláez T, Alcalá L, Bouza E. Extra-intestinal infections caused by Clostridium difficile. Clin Microbiol Infect [Internet]. 2001 Aug [cited 2019 Feb 22];7(8):453–7. Available from: http://www.ncbi.nlm.nih.gov/pubmed/11591212

Gupta A, Patel R, Baddour LM, Pardi DS, Khanna S. Extraintestinal Clostridium difficile Infections: A Single-Center Experience. Mayo Clin Proc [Internet]. 2014 Nov [cited 2019 May 11];89(11):1525–36. Available from: http://www.ncbi.nlm.nih.gov/pubmed/25245597

Incavo SJ, Muller DL, Krag MH, Gump D. Vertebral osteomyelitis caused by Clostridium difficile. A case report and review of the literature. Spine (Phila Pa 1976) [Internet]. 1988 Jan [cited 2019 Feb 22];13(1):111–3. Available from: http://www.ncbi.nlm.nih.gov/pubmed/3381119

Jacobs A, Barnard K, Fishel R, Gradon JD. Extracolonic manifestations of Clostridium difficile infections. Presentation of 2 cases and review of the literature. Medicine (Baltimore) [Internet]. 2001 Mar [cited 2019 Feb 22];80(2):88–101. Available from: http://www.ncbi.nlm.nih.gov/pubmed/11307591

Libby DB, Bearman G. Bacteremia due to Clostridium difficile -review of the literature. Int J Infect Dis [Internet]. 2009 Sep [cited 2019 Feb 22];13(5):e305-9. Available from: https://linkinghub.elsevier.com/retrieve/pii/S1201971209000800

Mattila E, Arkkila P, Mattila PS, Tarkka E, Tissari P, Anttila V-J. Extraintestinal Clostridium difficile Infections. Clin Infect Dis [Internet]. 2013 Sep 15 [cited 2019 May 11];57(6):e148–53. Available from: http://www.ncbi.nlm.nih.gov/pubmed/23771984

Morioka H, Iguchi M, Kuzuya T, Mikamo H, Yagi T. Recurrent bacteremia and liver abscess caused by Clostridium difficile. Medicine (Baltimore) [Internet]. 2017 Sep [cited 2019 May 11];96(35):e7969. Available from: http://www.ncbi.nlm.nih.gov/pubmed/28858131

Pron B, Merckx J, Touzet P, Ferroni A, Poyart C, Berche P, et al. Chronic septic arthritis and osteomyelitis in a prosthetic knee joint due to Clostridium difficile. Eur J Clin Microbiol Infect Dis [Internet]. 1995 Jul [cited 2019 Feb 22];14(7):599–601. Available from: http://www.ncbi.nlm.nih.gov/pubmed/7588845

Ranganath S, Midturi JK. Unusual Case of Prosthetic Shoulder Joint Infection Due to Clostridium difficile. Am J Med Sci [Internet]. 2013 Nov [cited 2019 Feb 22];346(5):422–3. Available from: https://linkinghub.elsevier.com/retrieve/pii/S0002962915304985

Riley T V, Karthigasu KT. Chronic osteomyelitis due to Clostridium difficile. Br Med J (Clin

Res Ed) [Internet]. 1982 Apr 24 [cited 2019 Feb 22];284(6324):1217–8. Available from: http://www.ncbi.nlm.nih.gov/pubmed/6803907

Roy M, Dahal K, Roy AK. Invading beyond bounds: extraintestinal *Clostridium difficile* infection leading to pancreatic and liver abscesses. BMJ Case Rep [Internet]. 2017 Aug 28 [cited 2019 Feb 22];bcr-2017-220240. Available from: http://casereports.bmj.com/lookup/doi/10.1136/bcr-2017-220240

Shah K, Brauch R, Cherabuddi K. Successful Treatment of Clostridium difficile Bacteremia with Aortic Mycotic Aneurysm in a Patient with Prior Endovascular Aortic Aneurysm Repair. Case Rep Infect Dis [Internet]. 2017 [cited 2019 Feb 22];2017:8472930. Available from: https://www.hindawi.com/journals/criid/2017/8472930/

Towns M, Hill EO, Tindall SC. Frontal bone osteomyelitis due to Clostridium difficile. Clin Microbiol Newsl [Internet]. 1984 Jan 1 [cited 2019 Feb 22];6(1):6–7. Available from: https://www.sciencedirect.com/science/article/pii/S0196439984800938

Ulger Toprak N, Balkose G, Durak D, Dulundu E, Demirbaş T, Yegen C, et al. Clostridium difficile : A rare cause of pyogenic liver abscess. Anaerobe [Internet]. 2016 Dec [cited 2019 Feb 22];42:108–10. Available from: https://linkinghub.elsevier.com/retrieve/pii/S1075996416301160

Figure 1: MRI showing destructive osseous changes involving proximal part of the humerus and a large effusion

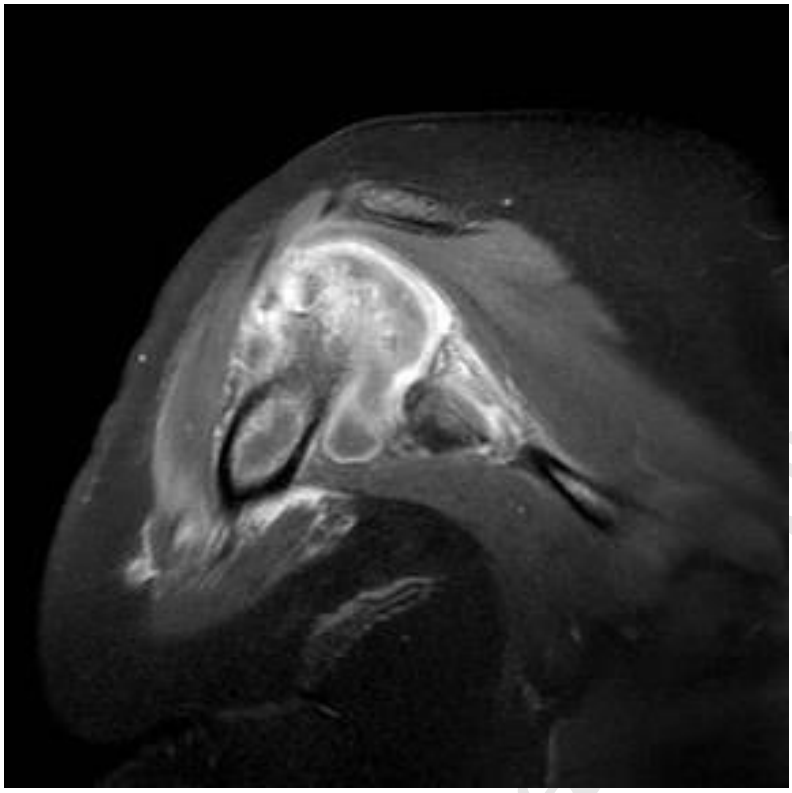

Figure 2: MRI of the right lower extremity showing sickle cell changes and possible osteomyelitis involving the mid-shaft of the right tibia

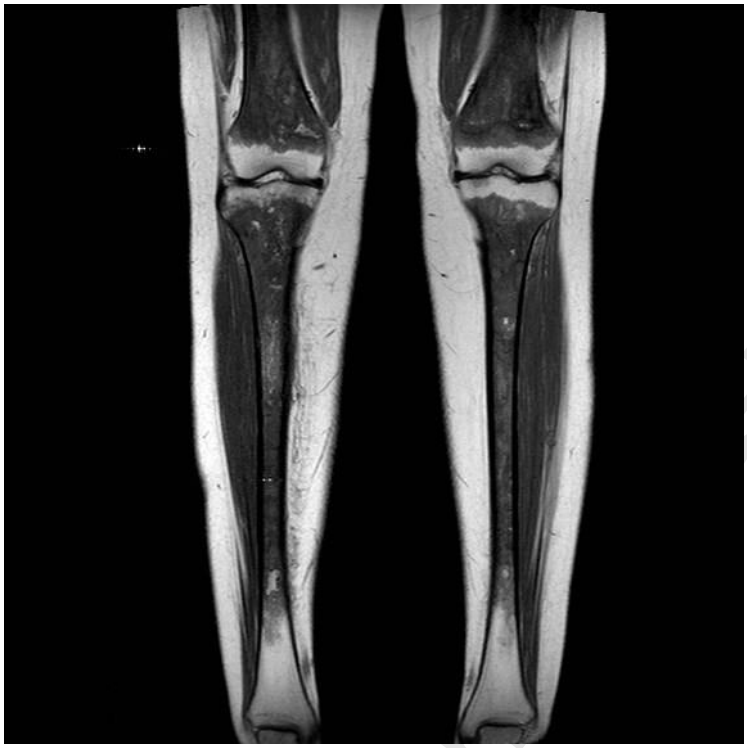

Figure 3: Severe right shoulder changes in keeping with chronic septic arthritis of the shoulder with osteomyelitis of the proximal right humerus with new multifocal proximal right arm fluid collections most likely abscesses

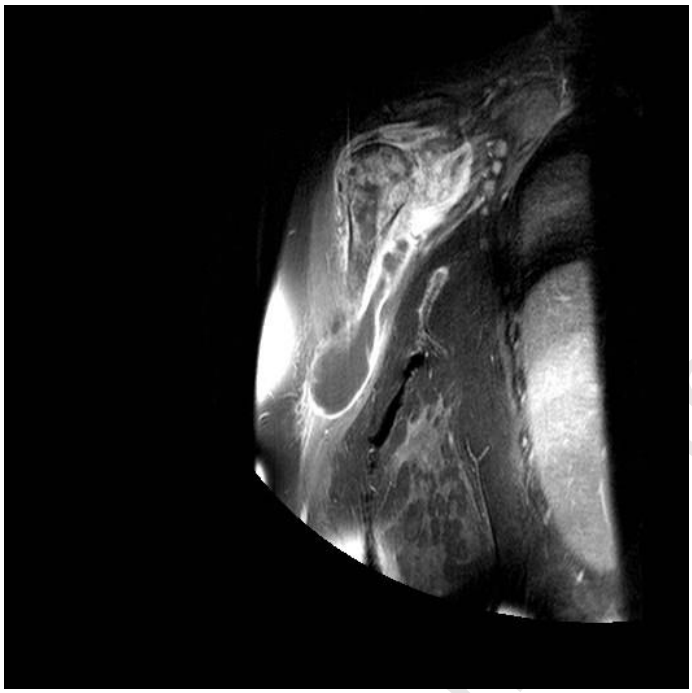

Table 1: Results of E-test of susceptibility tests of different antibiotics against *Clostridium difficle* (Inhibition zone in millimeter)

	Zone of Inhibition in millimeter
Ciprofloxacin	**0**
Penicillin G	**26**
Nitrofurantoin	**37**
Cefuroxime	**22**
Oxacillin	**0**
Cefoxitin	**0**
Clindamycin	**0**
Vancomycin	**35**