THE EFFECT OF FORMOCRESOL AND CALCIUM HYDROXIDE ON THE DENTAL PULPS OF RHESUS MONKEYS

By

Robert H. Spedding

Submitted to the Faculty of the Graduate School of Indiana University School of Dentistry in partial fulfillment of the requirements for the degree of Master of Science in Dentistry, 1963.

ACKNOWLEDGEMENTS

The author would like to express his appreciation for the opportunity to conduct this research project under the supervision of Dr. Ralph E. McDonald. His advice and guidance helped to provide for a pedodontic program of the highest quality.

The author wishes to extend a generous "thank you" to Dr. David F. Mitchell. His patience, understanding, and encouragement made the difficult tasks encountered in the course of research more tolerable.

Miss Donna Lee Wright assisted the author during the operative procedures. Her willingness to work and sense of good humor made the work more enjoyable.

Miss Shirley Elizabeth Shazer prepared the many, many histologic sections for this study. Her sound advice concerning various technical details was freely given to the author. Her efforts and contributions are genuinely appreciated.

The author appreciates the suggestions the graduate committee proposed concerning the written presentation of this study.

The author wishes to thank Mrs. Margaret Smith and Miss Sarah England for their valuable assistance in typing this thesis.

The author appreciates the services of Mrs. Gloria Spray, Dr. Charles H. Rosenbaum, and Mr. Richard Scott for the prep-

aration of the illustrations used in this thesis.

My wife, Ann, and my children, Bobby and Johnny, provided the impetus necessary to conduct this project. Their love and understanding were my most valuable assets.

TABLE OF CONTENTS

Page

INTRODUCTION..... 1

REVIEW OF LITERATURE..... 2

Early Attempts at Pulp Therapy..... 2
Use of Formaldehyde Compounds..... 4
Use of Calcium Compounds..... 13

STATEMENT OF PROBLEM..... 31

EXPERIMENTAL PROCEDURE..... 32

RESULTS..... 41

TABLES AND FIGURES..... 51

DISCUSSION..... 69

Selection and Maintenance of Monkeys..... 69
Microscopic Observations..... 71

SUMMARY..... 78

CONCLUSIONS..... 81

REFERENCES..... 83

VITA

ABSTRACT

LIST OF TABLES AND FIGURES

Table | Page

I. Microscopic Findings in Twenty Teeth Treated with Formocresol..... 51

II. Microscopic Findings in Twenty-Five Teeth Treated with Calcium Hydroxide..... 52

Figure

1. Preoperative Periapical Radiograph..... 53

2. Deciduous Cuspid Treated with Formocresol (17 days)..... 54

3. Deciduous First Molar Treated with Formocresol (17 days)..... 55

4. Permanent First Molar Treated with Formocresol (17 days)..... 56

5. Unoperated Permanent First Molar..... 56

6. Deciduous Cuspid Treated with Formocresol (51 days)..... 57

7. Deciduous Second Molar Treated with Calcium Hydroxide (24 days)..... 58

8. Permanent First Molar Treated with Calcium Hydroxide (167 days)..... 59

9. Permanent First Molar Treated with Calcium Hydroxide (167 days)..... 60

10 A & B. Diffusion of Formocresol..... 61

11. Relative Size of Bur and Cavity Preparation..... 62

12. Deciduous Cuspid Treated with Calcium Hydroxide (38 days)..... 63

List of Figures (Continued)

Figure		Page
13.	Permanent First Molar Treated with Calcium Hydroxide (38 days)	64
14.	Deciduous Second Molar Treated with Calcium Hydroxide (24 days)	65
15.	Deciduous First Molar Treated with Calcium Hydroxide (24 days)	66
16.	Deciduous Cuspid Treated with Calcium Hydroxide (24 days)	67
17 A-C.	Deciduous Cuspid Treated with Calcium Hydroxide	68

INTRODUCTION

A survey of the dental literature revealed various methods of treating a carious exposure of the dental pulp and maintaining it in a healthy condition. Many of these studies were empirical and little histologic evidence was presented in evaluating the results.

In order to properly evaluate a method or material used in the treatment of the human dental pulp tissue, several studies by independent investigators utilizing all available means of evaluation should be performed. Histologic evidence of success or failure is essential. A most logical beginning in such an evaluation would seem to be the use of an experimental animal whose dentition is closely related to that of man.

Studies of this nature have the advantages of various control measures not attainable in many clinical situations which depend on the whim of the human out-patient. In addition, the opportunity to obtain the teeth and their investing tissues after preferred time intervals, whether the treatment is considered successful or not, is more satisfactory in an animal study.

REVIEW OF LITERATURE

Early Attempts At Pulp Therapy

In 1836, Spooner[1] reported great satisfaction with the preservation of teeth by using arsenic upon the pulp tissue. "Instead of extracting teeth whenever the nerve is badly exposed, we destroy it, plug the teeth, and thus preserve them".

Burdell[2], in 1838, stated his violent opposition to the use of arsenic or "rat's bane" as a most deadly and corrosive poison. He advocated the use of caustics, actual cautery, or the mechanical removal of the nerve.

Koecker[3], in 1842, spoke of the impropriety of destroying the entire nerve of the tooth by any operation. He recommended the use of cautery (a red hot wire) to aid in pulp healing, followed by the placement of a thin lead leaf directly over the exposure, and then gold in the remaining area. He strongly believed that a tooth deprived of its nerve acted as a foreign body.

Arthur[4] reported, in 1852, that he had very little success in treating pulp exposures. He felt that once the "integrity of the body of the pulp" was disturbed it would no longer function properly. He advocated the use of arsenic (arsenous acid) to devitalize the pulp prior to extirpation.

Taft[5], in 1860, reported diverse reactions to arsenic ranging from good to bad. He recommended the use of skill instead of counter-irritants in order to avoid undesirable results. Chase[6], Hitchcock[7], and Arnold[8] spoke very favorably

of arsenic compounds in treating pulps. Hitchcock at one time used oxychloride of zinc but later used arsenous acid which seemed to give better results. Arnold's technique was actually a pulpotomy instead of a pulpectomy.

Allen[9], in 1866, carefully selected his patients for pulp therapy. He found the greatest success with patients in good physical conditions with recently exposed, non-painful pulps. He advised the use of creosote to preserve the pulp and the use of metallic caps placed over the exposure.

Atkinson[10], in 1868, favored the use of creosote to cauterize the pulp followed by oxychloride of zinc over the area. If pain recurred, he removed the dressing and repeated the treatment with creosote and oxychloride of zinc.

In 1881, Witzel[11] reported that oxychloride of zinc was very corrosive and appealed to the reader to refrain from the indiscriminate treatment of exposed pulps using strong corrosive substances.

Credit for the first pulp amputation or pulpotomy was given to Adolph Witzel by Christensen[12] in 1893. Cobalt was the material used by Christensen in his treatment of pulp exposures.

Harlan[13], in 1893, concluded that all methods of pulp treatment and pulp capping were subject to variations in detail but all had as their objective pulp preservation; nevertheless, he favored complete extirpation of the pulp.

Use of Formaldehyde Compounds

In 1897, a report[14] appeared concerning one of the earliest formaldehyde preparations. This substance was labelled "Formagen" and consisted of a liquid and powder both saturated with formaldehyde. After being mixed and applied to the pulp, the material hardened and gave off formaldehyde vapor which was reported to be painless in its action on pulp tissue. It was stated that Formagen absorbed suppuration and exudation (which put pressure on the vessels resulting in a constricted flow) and relieved congention thus allowing the pulp to return to its normal function. This material was applied to the cavity of teeth not destroyed by suppuration and a permanent filling was then placed.

Boennecken[15], in 1899, reported the use of formaldehyde to mummify the pulp after previous cauterization with arsenic.

In 1904, Buckley[16] reported the use of tricresol and formalin for the treatment of putrescent pulps. He advocated the establishment of asepsis, the prevention of recurring sepsis, and the preservation of tooth color. He recommended that formaldehyde should not be forced through the root apices because of possible irritation to the periapical tissues. He emphasized the lack of scientific and practical therapeutics stating that the treatment of putrescent pulps was based on empiricism.

In 1909, Boennecken[17] claimed that his mixture of 40 per

cent formalin could change the remains of the root into a "stiff fibrous tissue". He added one per cent cocaine to his preparation to prevent pain. Prior to amputation of the pulp he inserted arsenic for 24 hours.

Alvord[18], in 1929, reported the use of formocresol in the treatment of root canals. He sealed in treatments of formocresol on cotton and when the conditions were suitable for filling the canals he used zinc oxide and eugenol and silver nitrate to fill them. He claimed that the roots and the filling materials would resorb under physiological conditions when used in deciduous teeth.

In 1929, Bossard[19] reported the use of Gysi's Triopaste which contained trioxymethylene (paraformaldehyde). He used cobalt ($CoAs_2$) or arsenic acid (As_2O_3) for initial cauterization and left it in contact with the pulp from four to eight days. The coronal pulp was then cleanly amputated and phenol in combination with cobalt was sprinkled on cotton and sealed into place. This in turn was followed by Gysi's Triopaste which mummified the pulp and rendered it unfavorable for growth of microorganisms. He recommended this treatment for deciduous teeth to prevent early or late exfoliation which he felt often occurred. When non-resorbable materials were placed in the canals, he claimed the amputated tooth pulp was non-reactive but <u>not dead</u> and responded to the healing process in accordance with "the theory of wound healing".

Müller[20], in 1929, advocated the use of Gysi's Triopaste. He felt that when the pulp was devitalized by arsenic trioxide thus being free from germs, and was then extirpated, it was incomprehensible how an infection could occur after using Triopaste. The photomicrographs presented revealed secondary cementum closing the apical foramen and adjoining canals. He regarded this formation of secondary cementum as the most ideal root filling.

In 1934, Levine[21] advocated the devitalization of the pulp by 0.0009 As_2O_3 (arsenic trioxide), amputation of the coronal pulp, sterilization of the remaining pulp by the action of arsenic, and the mummification of this pulp by Triopaste. He concluded that the remaining necrotic pulp was calcified by an ingrowth of cementum from the periodontal membrane. He reported 500 successfully treated cases over a twenty year period supported by radiographic and oral findings.

Orban[22], in 1934, reported that a large percentage of paraformaldehyde treatments produced pulp metaplasia resulting in a change from embryonic tissue to fibrous connective tissue and bone tissue (osteoblasts, etc.). He stated that low concentrations of paraformaldehyde produced pulp anesthesia and stimulated secondary dentin formation, whereas large concentrations of paraformaldehyde caused metaplasia of the pulp and endangered the teeth.

In 1936, Sweet[23] reported a technique for the treatment of exposed pulps in deciduous teeth. Three appointments were recommended. At the first sitting the coronal pulp was amputated under local anesthesia and formocresol or beechwood creosote was sealed in with temporary stopping for two or three days. The stains or exudate present were removed at the second appointment and formocresol or beechwood creosote was sealed in for two or three more days. The pulp chamber was filled with a creamy mixture of zinc oxide and eugenol at the third appointment, and the final restoration (silver amalgam alloy) was inserted.

Easlick[24], in 1939, advocated the use of a paraformaldehyde paste for the treatment of vital exposed deciduous pulps and after vital pulpotomy of exposed permanent anterior and posterior teeth with uncalcified root ends. No discussion of results was reported, however. In 1943[25], he reported 70 per cent success in the treatment of pulps with his paraformaldehyde paste. He stated that improved diagnoses and technics would probably improve the success of treatment.

In 1950, Low and Krasnow[26], advocated the use of zinc oxide and eugenol and 1 per cent paraformaldehyde in the treatment of vital exposed pulps indicated for pulp therapy. They believed that the paraformaldehyde in this concentration was not enough to mummify the pulp but instead acted as an antiseptic and also encouraged secondary dentin formation.

They reported 89.7 per cent deciduous teeth saved until normal exfoliation occurred and 88.7 per cent success in permanent teeth. No histologic data were given.

Castagnola and Orlay[27], in 1951, stated that the deposition of secondary cementum around the apex provided a biological seal in cases where pulp devitalization was necessary. Their requirements for a devitalizing paste were as follows:

1. Render the remaining pulp sterile.
2. Maintain sterility of the amputated pulp for an unlimited time.
3. Diffuse and permeate the pulp easily without reaching the apical parts and without disturbing the biological reactions at the apex.
4. Should not discolor the tooth.

They believed that formaldehyde was the essential agent in drugs used for devitalization. They tested various pastes and reported clinical success in 93.7 per cent and radiographic success in 81.6 per cent of 1,000 teeth. From histological specimens, they noted the invasion of the devitalized parts by granulation tissue which in turn was replaced by periodontal tissue from which secondary cementum was formed (lacunar type, osteocementum).

Rabinowitch[28], in 1953, reported his treatment of pulpless teeth in which he used a mixture of beechwood creosote or cresol (50 per cent), formaldehyde (30 per cent), absolute

alcohol (20 per cent), and Howe's ammoniacal silver nitrate. He stated that silver nitrate destroyed organisms and in combination with other organic materials splits protein and toxic and putrescent substances and changes them to inert materials.

In 1953, Mohammed and Schour[29], reported a histologic study of the effect of cavity preparation and two combinations of Aquadont in rat incisors. Aquadont in combination with one per cent paraformaldehyde produced morphologic changes varying in degree from reversible albuminoid degeneration to necrosis. These changes increased in intensity with the depth of the cavity preparation. With Aquadont alone there was complete recovery in 96 hours, partial recovery with one per cent paraform in shallow cavities, and no recovery with one per cent paraform in deep cavities.

In 1955, Mohammed and Schour[30], again reported the effects of a paraformaldehyde filling material on the rat incisor. It was observed that the effects of zinc oxide in deep and shallow cavities were mild and transitory with complete recovery in 96 hours, whereas zinc oxide with one per cent paraform elicited partial recovery under shallow cavities and no evidence of recovery under deep cavities.

In 1956, Nacht[31] reported data accumulated by the Vancouver Pedodontic Study Club on 467 deciduous molars using Oxpara powder and liquid in a devitalizing pulpotomy. Repeated

clinical examinations over a five year period were performed. These and radiographic evidence were the only basis for judgment of success. For the first two years no significant changes were noted. Then progressive bone loss in the root bifurcation area was observed, although there were no noticeable clinical changes evident. The end result was early loss of the deciduous molar and early eruption of the succeeding permanent tooth. The deciduous teeth prior to exfoliation remained functional. He concluded that many teeth were retained over a critical period of dental development without any apparent deleterious results to the patient.

In 1958, Wong[32] reported the effects of paraformaldehyde on periapical tissues using a non-vital pulpotomy procedure. This work was performed on Rhesus monkeys. Thirty-four teeth were used as controls and 34 teeth were treated with the material under investigation. Histologic findings of the pulp and periapical tissues revealed changes varying in nature from pulpal inflammation to degenerative changes in bone where the material came in contact with the bone as the roots resorbed. He noted a marked difference of pulp tissue of the deciduous and permanent teeth; a fibrous appearance was dominant in the deciduous pulp while bone formation was prominent in the permanent pulp. He observed toxic reactions of the tissues in contact or in close proximity to the parts. In tissues farther away from the filling material, lymphocytic infiltration was

noted. He found no untoward effects on periapical tissues although there was evidence of lymphocytic infiltration of the underlying dental sac surrounding the permanent tooth with subsequent degeneration of the ameloblastic layer of the tooth germ. He advocated the application of this material in young permanent teeth rather than in deciduous teeth because of the possibility that the permanent tooth might be damaged.

In 1959, Emmerson et al[33], reported on the pulp changes found in rat molars and human deciduous molars elicited by application of formocresol. They concluded that the pulpal reaction varied with the time of contact of formocresol with the pulp. The changes varied from surface fixation to calcific degeneration. They observed no cases of internal resorption or inflammation. They proposed that this technique may be called vital or non-vital depending upon the length of time the formocresol is in contact with the pulp. They found complete fixation in human cases observed over a long period of time but did not report the extent of this period.

Mansukhani[34], in 1959, reported an investigation based on two series of experiments in human and rat molars using a formocresol preparation sealed into the pulp chamber for varying periods of time. In the human series, the length of time the medicament remained in contact with the pulp varied from one minute to three years. Histologic examination revealed

an area of fixation immediately beneath the medicament (fibrous and acidophilic in appearance). In the seven and fourteen day specimens, three distinct zones were described: a broad acidophilic (fixed) zone, a broad pale-stained zone where cells and fibers were greatly diminished (atrophy), and a broad zone of inflammatory cells concentrated at the junction with the pale-staining zone and diffusing deeply into the underlying normal pulp tissue to the apex. The thirty day specimens showed an inflammatory zone at or through the apex and a pale-staining zone near the apex. The specimens observed from the sixty day and two year groups revealed complete pulpal fixation described as strands of eosinophilic fibrous tissue.

The histologic evidence collected in the group of rat molars revealed a defensive reaction of fibrous encapsulation of the inflammatory cells with subsequent calcification of the capsule and reparative dentin formation. This was the outstanding difference from the human reactions studied.

In 1961, Velling[35] reported a clinical study of 863 cases of infected and necrotic deciduous teeth treated at Fort Riley, Kansas with a "formalin" solution since January, 1958. He reported only five failures and attributed these to mechanical perforations of the bifurcation of the roots during pulp therapy. No histologic confirmation was reported.

Doyle[36], in 1961, compared the effects of the formocresol and the calcium hydroxide pulpotomy technique on mechanically

exposed dental pulps in 65 human deciduous teeth. Eighteen teeth treated with calcium hydroxide and 17 teeth treated with formocresol were extracted and examined microscopically. The time lapse between treatment and extraction varied from four to 388 days. Fifty per cent of the 18 calcium hydroxide specimens and 71 per cent of the 17 formocresol specimens exhibited a satisfactory histologic appearance. He concluded that under the conditions of this study, the formocresol pulpotomy technique was superior to the calcium hydroxide pulpotomy technique for at least the first 18 months following treatment of normal primary dental pulps.

Use of Calcium Compounds

McBride[37], in 1936, discussed the treatment of pulps in first permanent molars that were observed to be exposed or nearly exposed. He observed clinical success more frequently in the pulp capping treatment of a young permanent molar than in the same treatment of the deciduous molars. He advocated the partial removal of the pulp in the event of a carious exposure or in instances where the apices of the permanent molar roots were not completely formed. He covered the pulp tissues with zinc oxide and eugenol or thymolized calcium phosphate and metal discs or plates.

In 1938, Teuscher and Zander[38] presented a preliminary report on the treatment of vital pulp exposures with calcium

hydroxide and water. One deciduous molar and one permanent molar were examined histologically and a dentin "bridge" was described. The structure of this bridge was discussed; the dentin toward the pulp showed no cellular enclosures whereas that portion toward the capping material contained enclosed cellular elements. A microscopic picture of hyaline degeneration was described upon examination of the young permanent molar. They concluded that the pulp was maintained in a vital condition after treatment because of the ability of the pulp to construct its own defensive mechanism, i.e., a laying down of a protective dentin barrier.

Zander[39], in 1939, reported 150 cases of permanent teeth treated with a calcium hydroxide paste (90 cases) and Calxyl (60 cases). Radiographic evidence revealed no apical changes in 70 per cent of the cases. Histologic evidence revealed a formation of structureless dentin in almost every case resulting in a calcified bridge. He stated that dentin formation occurred not only in healthy pulps but also in the presence of inflammation.

Restarski[40], in 1940, reported results of pulpotomies performed on permanent teeth extracted for prosthetic reasons, and deciduous teeth extracted just prior to exfoliation. These teeth were treated with either Calxyl, zinc oxide and eugenol, or dentinoid and eugenol. Histologic findings of the Calxyl treated teeth extracted after 28 days revealed

calcified bridges with normal tissue beneath these bridges. He observed a uniform layer of odontoblasts present on the apical side of the dentin bridge. He did not observe inflammatory changes in these teeth treated with Calxyl. Some of the teeth treated with the zinc oxide and eugenol compound revealed granulation tissue beneath the material. Underneath the granulation tissue a fibrous layer with some calcification was observed. Normal tissue was also observed in these specimens. He concluded that there was a rapid calcification and bridge formation in the Calxyl treated teeth with a regular pattern of deposition of secondary dentin. All teeth treated with zinc oxide and eugenol showed incomplete calcification at the end of five months. The number of teeth used in this microscopic study was not reported.

In 1949, Glass and Zander[41] reported the results of a study in which they attempted to determine the conditions under which a young, healthy exposed pulp would heal. They capped the pulps of 40 sound teeth in children nine to fifteen years of age with zinc oxide and eugenol and calcium hydroxide. One type of each material was placed in the same mouth for comparison. These teeth were extracted at intervals of 24 hours, 2, 4, 6, 8 and 12 weeks after the procedures. A pulp was considered to be healed if the exposure site was walled off by new dentin formation. They found the pulps capped with calcium hydroxide were healed in four weeks time, whereas the

pulps treated with zinc oxide and eugenol remained vital and asymptomatic but did not elicit the "bridging effect" and exhibited chronic inflammation around the exposure site. The only evidence of healing in the zinc oxide and eugenol group was the attempt of the pulp to join the dentin fragments which were forced into the pulp at the time of the preparation. There was no walling off of the exposure site by new dentin formation observed in the zinc oxide eugenol specimens during the 12 week duration of this study. They did not specify whether or not deciduous pulps were treated in this study. In 1949, Zander and Glass[42] again reported a study of pulps treated with phenol prior to being capped with zinc oxide and eugenol and calcium hydroxide. In their previous study reported in 1949, they found a necrotic layer of pulp existing which was superficial to the calcium hydroxide medicament. In four weeks time a new odontoblastic layer and a dentin bridge was observed. This phenomenon was not observed in the pulps treated with zinc oxide and eugenol. They proposed that if the necrotizing action of calcium hydroxide was responsible for new dentin formation and healing of the pulp, then phenol, an escharotic, might possibly elicit a similar response. They used 44 normal teeth in a group of nine 46-year-old patients and extracted their teeth at intervals of 24 hours up to 16 weeks. The histologic findings revealed a superficial necrotic zone produced by phenol which did not

favorably influence pulp healing. This was evidenced by a layer of granulation tissue in the pulps treated with zinc oxide and eugenol. Phenol neither enhanced nor interfered with the healing action of calcium hydroxide. No references to deciduous teeth were found in this report.

In 1950, Hess[43] reported on pulp capping of 600 teeth treated with Calxyl in which all caries were removed. The teeth were checked by visual, radiologic, and histologic examination. He reported 95 per cent success in exposed healthy pulps with healthy dentin, 88 per cent success in exposed healthy pulps with carious dentin, and 85 per cent success in exposed healthy pulps in contact with saliva for a short period of time. He noted that 65 per cent of the deciduous teeth treated remained vital and revealed dentin bridges over the pulp stumps.

Tananbaum[44], in 1951, reported an evaluation of pulp capping with zinc oxide and eugenol and calcium hydroxide in 128 permanent and deciduous teeth over a period of five to 39 months. He found that 116 teeth were treated successfully. This represented 89 per cent success with zinc oxide and eugenol and 92 per cent success with calcium hydroxide. Upon radiographic examination he observed bridging in four per cent of the zinc oxide and eugenol treated teeth after two years and in 89 per cent of the calcium hydroxide treated teeth at the end of one year. No histologic evidence was reported.

Wittich[45], in 1952, presented a preliminary report on data collected in a five year period at the University of Minnesota concerned with pulp capping of deciduous teeth. The capping material used consisted of iodoform, calcium hydroxide, zinc oxide and eugenol, and phenol. Results were based on clinical and radiographic findings on 243 teeth. Abscesses were found in 32 teeth and the remaining 211 teeth were judged to be successfully capped. This represented 87 per cent success of all treated teeth.

In 1953, Strange[46] reported a study of vital pulpotomies on 29 deciduous teeth and 16 permanent teeth which were treated with calcium hydroxide. Success of treatment was based on clinical examination (no periapical involvement noted in radiographic examination, no history of pain, not sensitive to percussion, etc.). Successful results were observed in 26 deciduous and 12 permanent teeth or in 82.5 per cent of the treated teeth.

In 1954, Berk and Cohen[47] reported on vital pulpotomies performed on seven non-carious deciduous and permanent teeth that were to be extracted for orthodontic reasons in patients nine to twelve years of age. Histologic specimens of teeth extracted after five to six weeks were obtained in four patients and after 52 weeks in the fifth patient. Six pulpotomies treated with a mixture of calcium hydroxide and methyl cellulose showed dentin bridges with normal pulp tissue beneath

the bridges. An increase in fibroblasts was noted in the normal pulp tissue. One tooth was treated with zinc oxide and eugenol and extensive necrosis of the remaining tissue was observed.

In 1954, Patterson and Van Huysen[48] reported a study of pulp capping carried out in four non-carious human teeth (three premolars in a 14 year old girl and one molar in a 43 year old male). Two exposures were made with the airbrasive technique and two exposures were made with steel burs. Three teeth were capped with calcium hydroxide and one with a thin gold plate. The treatments were sealed in for two months with crown and bridge cement and then extracted for histologic examination. The results were as follows:

a. One premolar with calcium hydroxide - good bridge, no inflammation.

b. One premolar with calcium hydroxide - foreign bodies in pulp (Al_2O_3 from the airbrasive), no inflammation.

c. One molar with calcium hydroxide - no bridge, no inflammation, thick predentin layer around margin of the pulp chamber.

d. One premolar with gold plate - incomplete bridge, no inflammation.

A clinical follow-up examination was made of 56 teeth similarly capped and, combined with the four teeth examined

histologically, 92 per cent were considered to be successful. Only five failures were reported. They concluded that the dental pulp is amenable to healing at almost any age with or without closure of the exposure site. They also cautioned against the use of destructive drugs or procedures such as the use of cautery.

Seelig et al[49], in 1954, reported a histologic study of the effect of penicillin G potassium and calcium carbonate on 11 surgically exposed dental pulps of a rhesus monkey. In all cases in which the paste of penicillin G potassium and calcium carbonate was placed under zinc oxyphosphate cement, a normal pulp was observed and a dentin bridge was formed. A zinc oxide and eugenol paste was placed over the exposed pulps of four teeth and oxyphosphate of zinc cement was placed over the exposed pulp of one tooth. Two teeth were left exposed to the oral environment without treatment. These seven teeth were considered to be controls. Zinc oxide and eugenol and oxyphosphate of zinc cement in direct contact with the pulp produced an inflammatory response, abscess formation, or death of the pulp. No results were reported for those untreated pulps exposed to the oral cavity. They surmised that the calcium carbonate in the penicillin mixture neutralized the orthophosphoric acid in the cement enabling the penicillin to react in an alkaline medium.

In 1955, Via[50] presented the results of a study of 103

calcium hydroxide pulpotomies performed on deciduous molars and examined radiographically after an average of 24.9 months. He observed success in 32 teeth (31.1 per cent) and failure in 71 teeth (68.9 per cent). He noted internal resorption in 48 teeth classified as failures and 14.4 per cent of these teeth were considered to be successful because the resorption was repaired by a calcified tissue and the tooth was maintained in the arch. Histologic examination was made on two teeth, both exhibiting internal resorption and inflammation. From this study he concluded that the most important factor for successful pulp treatment is the determination of the condition of the pulp prior to treatment.

Brinsden[51], in 1955, reported a study of 30 cases of cariously exposed permanent teeth in which pulp therapy was performed. He divided the specimens into two groups. In the first group, the pulp was amputated to a level of one millimeter into the root canals. The second group comprised only three teeth in which only the affected pulpal horn was amputated. Calcium hydroxide was placed into the exposed areas and was covered by zinc oxide and eugenol only. The formation of dentin bridges was determined on radiographs and by direct examination with smooth broaches. Thirty-three calcified bridges were observed on the radiographs in 47 canals. Forty-five calcified bridges (five incomplete) were noted on direct examination of 47 canals. This represented a 66 per

cent agreement between radiographic and clinical evaluation of calcified bridge formation. Serial sections were evaluated on three teeth and complete bridging was evidenced in all sections examined. He concluded that the mature dental pulp retains its healing potential.

In 1955, Shoemaker[52] reported the results of a study of 28 pulpotomies performed on deciduous and permanent teeth (19 deciduous molars, nine permanent molars and incisors). A mixture of calcium hydroxide and bone meal was insufflated over the amputated pulpal stumps and covered with asbestos paper and zinc cement. Success was determined by oral radiographic examinations and the lack of pain. The treatment of nineteen deciduous molars was found to be successful over an average period of 18 months, and nine permanent molars and incisors were considered to be successful over an average time range of 15 months. He found the overall success to be 39 per cent in 28 teeth (32 per cent in deciduous teeth and 55 per cent in permanent teeth) over a period of two years.

In 1955, Massler et al[53] reported a study of pulpotomies performed in the incisors of over 100 rats sacrificed for histologic examination at intervals of 3, 7, 10, 14 and 21 days. Calcium hydroxide, calcium phosphate, or zinc oxide and eugenol was placed over the amputated pulp stump. Histologic analysis revealed a common pattern of pulp healing under each of the three substances. Acute inflammation, degeneration

and necrosis of the pulp immediately beneath the capping materials, diffuse calcification of the necrotic layer, and an occasional bridging by a dentin-like structure were observed. Although slight differences in the degree of healing were noted, the basic healing pattern was similar.

Kalnins[54], in 1955, reported the effect of pressure on 262 sound and cariously exposed human deciduous and permanent dental pulps. Calcium hydroxide, sulfathiazole, and strontium salts were formed into a paste, pressed into the coronal pulp after the pulp chamber roof was removed, and sealed with a filling material. Care was taken to wash out dentin chips from the preparation. Of the 127 permanent teeth treated, 107 teeth responded to vitality tests after two months to three years. A radiologic study revealed dentin bridging in 50 teeth. Of the 57 deciduous teeth treated, only six required root canal treatment or extraction. The histologic examination of 88 teeth revealed a fibrous metaplasia, capsule-like in appearance, of the superficial pulp. Underneath this zone, the pulp tissue appeared undisturbed. Dentin bridging developed at a later period in some specimens.

In 1955, Hunter[55] reported a study in which an investigation was made to determine the mechanism of bridge formation in an exposed pulp. The pulps of 42 teeth in dogs were exposed and covered with one of these materials: calcium hydroxide, magnesium hydroxide, zinc oxide and eugenol, zinc

oxide-phosphoric acid cement, calcium oleate, or cholesterol for various periods up to nine weeks. No bridging was found in the teeth treated with either calcium oleate, cholesterol, or zinc oxide-phosphoric acid cement. One pulp treated with zinc oxide and eugenol exhibited bridging and two zinc oxide and eugenol treated pulps showed depositions of dentin around dentin fragments. Ten out of 14 calcium hydroxide and five out of 10 magnesium hydroxide treated pulps revealed bridge formations. The investigator proposed that possibly the elevated pH of the magnesium and calcium compounds was responsible for the stimulation of new dentin formation.

In 1956, Bergh and Martensson[56] in Sweden reported the results of pulp treatment in 1,439 deciduous teeth. Pulp capping with either zinc oxide and eugenol, Calxyl, or calcium hydroxide paste was performed on 176 teeth. Vital amputations were performed on 1,101 teeth. Large exposures and minimal bleeding were noted. Either xeroform, a xeroform-penicillin-sulfathiazole combination, Calxyl, or calcium hydroxide paste was placed over the pulp stumps. Non-vital amputations in 162 teeth using xeroform paste were made. They claimed 80 per cent success (determined by radiographic and clinical tests only) regardless of methods or materials utilized. No histologic results were reported.

Kalnins and Frisbie[57], in 1956, examined 46 permanent and deciduous teeth capped with calcium hydroxide and sulfathiazole

which were extracted for histologic investigation after a two to fourteen month period. Each tooth showed dentin fragments in the pulp. Thirteen pulps were inflamed, 11 pulps were normal and no evidence of bridging or defective bridges was observed. The dentin fragments in the inflamed pulps were resorbing in the presence of giant cells. Only four cases showed normal healing and bridge formation with the dentin fragments confined to the superficial portion. They believed that the observation of inflammation, resorption of the dentin fragments, and their encapsulation in a callus suggested a foreign body reaction. They advised against the inclusion of dentin fragments in the pulp during the pulp capping or pulpotomy procedures.

In 1956, Janes and Englander[58] reported a study of the pulpal response to calcium compounds and antibiotics often used in vital pulp therapy. One hundred and thirty-three pulps with carious exposures were examined microscopically after a treatment period of four to 181 postoperative days. Their results showed bridging to have occurred in 35 per cent of the treated cases and internal resorption present in 19 per cent of these cases. Calcium hydroxide, calcium phosphate, calcium carbonate, aureomycin, penicillin, terramycin, and polyantibiotic (PBSC) were used alone or in combination and were placed over the amputated pulp stumps. They concluded that the incidence of internal resorption was directly related

to the severity of inflammation, whereas an inverse relationship between the incidence of bridging and the severity of inflammation occurred. They found a greater incidence of bridging in the teeth treated with the calcium salts as well as less inflammation and internal resorption when compared to the teeth treated with the antibiotics. The combination of calcium salts and antibiotics resembled the picture of those pulps treated with antibiotics alone.

Feitelson[59], in 1956, reported a study of pulp capping with calcium hydroxide and crystalline penicillin-G (10,000 units) in 96 human teeth. Eighty-three teeth (34 deciduous and 49 permanent) were examined by clinical means only and seven of these teeth developed acute alveolar abscesses or periapical bone changes. He reported 91 per cent success in deciduous and 92 per cent success in permanent teeth. The author stated that negative evidence alone can be used since dentin bridge formation is difficult to determine on radiographic examination. He arbitrarily chose a one year period of elapsed time after the procedure in which results of treatment might be expected so that pulp vitality might be reasonably ascertained. He advocated pulp capping since it was the least complex of the methods used for the treatment of carious pulp exposures. He explained failures on the basis that the existence of the pulp vitality was impaired prior to treatment, the pulp was traumatized seriously because of the procedure,

or because of a combination of these two factors.

Law[60], in 1956, reported a progress evaluation of 283 vital pulpotomies on permanent and deciduous teeth treated with calcium hydroxide. All cases were evaluated by visual and radiographic means every six months and were reported to be 49 per cent successful. He observed 61 per cent failure in the mandibular arch as compared to 43 per cent in the maxillary arch, and proposed that the higher mortality observed in the lower arch was due to earlier eruption of the teeth and early attack by the caries process. He stated that a diagnostic radiographic examination was more accurately determined in the lower arch.

In 1957, Miyamoto[61] reported the results of pulpotomies performed in 158 rat molars using various agents over the pulpal stumps (calcium hydroxide, calcium phosphate, calcium carbonate, zinc oxide and eugenol, amalgam, self-cure resin, silicate cement and zinc phosphate cement). The animals were sacrificed at one hour, 7, 14, 21 and 28 days after treatment and the teeth prepared for histologic observation. He noted that the pulpal reaction was similar under calcium and non-calcium materials. The presence of infection and inflammation prevented a secondary dentin bridge formation. He also observed a necrobiotic zone consisting of coarse collagen fibers and encapsulated pyknotic cells between the degenerative area under the medicament and the vital pulp which was appar-

ently calcified and stimulated the formation of new odontoblasts and subsequent formation of secondary dentin. Dentin spicules were reported to accelerate the formation of the necrobiotic zone and secondary dentin formation. He reported that the smaller exposures were sealed with a dentin bridge faster than the larger exposures. Adequate seal against the ingress of oral fluids seemed to be more significant in pulp healing than the type of material placed over the amputated stumps. The self-cure acrylic resins and amalgams were similar to the calcium salts and zinc oxide and eugenol in that there was relatively little inflammation. The acid cements caused necrosis except when a blood clot was allowed to form over the amputated pulp in which case the reaction was similar to that of the calcium salts and zinc oxide and eugenol.

Jensen[62] reported, in 1957, a histologic comparison of two pulp capping agents used in three adult dogs. The agents used were calcium hydroxide-distilled water and a combination of zinc oxide, calcium hydroxide, iodoform, eugenol and phenol. He observed a hard tissue bridge of irregular (secondary) dentin in four weeks and no distinguishable differences in the rate of healing from four to eight weeks or in the results produced by either capping agent. He found no apparent advantage or disadvantage in adding zinc oxide, iodoform, phenol, or eugenol to calcium hydroxide.

In 1958, Berman and Massler[63] reported a study of experi-

mental pulpotomies in the molars of rats using calcium hydroxide and zinc oxide and eugenol as pulp dressings. The pattern of healing was basically the same for both drugs. The seven day histologic picture was different for both drugs but was the same in the 21 day specimens (although a more rapid necrosis and bridging effect occurred in the calcium hydroxide treated teeth). They observed that unorganized blood seemed to retard healing whereas precipitated or coagulated protein material (pulp tissue or exudate) appeared to favor pulpal healing. An adequate seal was found to be a major factor in promoting healing of the treated pulps and bridge formation was found to occur in the teeth treated with either material.

Seltzer and Bender[64], in 1958, reported a study of the treatment of mechanically exposed pulps in 52 teeth of three dogs performed under aseptic conditions. Calcium chloride, calcium carbonate, calcium phosphate, calcium hydroxide, ammonium hydroxide, alkaline phosphatase or potassium penicillin were used to cover the exposure sites. The treated pulps were covered with sterile asbestos fibers, amalgam alloy, and observed over a period of seven to ninety days. One-half of the pulps were treated immediately after exposure and the other half was treated after the formation of a blood clot occurred. Calcium hydroxide was the only salt that stimulated reparative dentin. Ammonium hydroxide which has the same pH as calcium hydroxide, and potassium penicillin

caused pulpal necrosis in every instance. The formation of a blood clot was of no value from a therapeutic standpoint. Dentin bridge formation was evidenced in the control teeth where no medicaments were used. Apparently the dentin chips introduced into the pulp during the capping procedure stimulated the production of a dentinoid material. They found that inflammation, degeneration, and dentin resorption occurred in spite of the presence of dentin bridge formation and they questioned the formation of a dentin bridge as an indication of successful pulpal repair.

In 1961, Mohammed et al[65], presented a histologic study of the pulp tissues in dogs teeth which had been capped with either calcium hydroxide, zinc oxide and eugenol, or zinc oxyphosphate cement. Labial cavity preparations were made in the canine teeth and in 17 cases a calcium hydroxide material was inserted, while 16 cavities were capped with zinc oxide and eugenol, and 11 pulps were covered with zinc oxyphosphate cement.

Calcium hydroxide was observed to be the least irritating to the pulp whereas zinc oxide and eugenol was destructive in four cases. The zinc cement caused severe pulpal necrosis in every case. They stated that zinc cement is contraindicated for use in deep cavities.

STATEMENT OF PROBLEM

In recent years, two clinical techniques have been recommended for the management of carious pulp exposures in the deciduous teeth of children. After coronal pulpotomy, one technique makes use of a formalin containing compound which apparently devitalizes the pulp and produces a degree of pulpal fixation whereas the other technique involves the use of calcium hydroxide as a pulp dressing which reportedly maintains the vitality of the remainder of the pulp. At present, there is insufficient evidence from clinical and laboratory research to justify recommending one technique over the other.

The major objective of this study was to attempt to duplicate in monkeys these two clinical procedures in deciduous and young permanent teeth and to note the differences in the reactions of the pulp and periapical tissues of these teeth to formocresol and calcium hydroxide therapy after varying time intervals. The response of the pulp and the periapical tissues of these teeth to the pulp dressing materials was determined microscopically through the use of serial sections through the pulps of extracted teeth, as well as through quadrants of jaws sectioned en bloc.

EXPERIMENTAL PROCEDURE

According to some of the available data[66-70] pertaining to size, weight, and dentitions of the rhesus monkey, three animals approximately 20 months old were selected for this study. These animals had a full complement of deciduous teeth and first permanent molars. The original experimental sample consisted of forty-eight teeth: thirty-six deciduous and twelve young first permanent molars.

When the animals were first procured, they were dusted with five per cent DDT powder, given a vermifuge*, and a prophylactic dose of isoniazid** to combat tuberculosis. The animals were then isolated for two weeks before being placed into individual cages in the animal quarters of the dental school. Prior to each procedure the proper equipment and instruments for the work to be performed were placed in the operating area.

Each animal was removed from its cage with the aid of a folding net[71], and the arms and legs were securely wrapped behind the animal's back with one inch surgical tape. In order to facilitate safe handling for the operator, heavy gloves were used when the animal was removed from its cage. Two people could safely and rapidly secure the animal although, on occasion, the animal became traumatized during

---

* Vermaplex Capsule, Pittman-Moore Company, Indianapolis, Indiana.

** INH, Eli Lilly and Company, Indianapolis, Indiana.

heightened activity in the process.

The animal was weighed each time it was captured in order to calculate the proper dosage of anesthetic solution to be used. The recommended dosage for profound anesthesia was calculated to be 1.00 ml. (60 mgm) of Nembutal sodium* for every three pounds of body weight.

The anesthetic solution was administered via the intraperitoneal route and the animal was placed in a small metal carrying cage in order to protect the animal from any undue injury during the onset of anesthesia. The average time lapse from the injection of the anesthetic solution until the operative anesthetic level was obtained was approximately twenty minutes. The average length of operating time was approximately two and one-half hours and occasionally an additional 0.5 to 1.00 ml. anesthetic solution was injected in order to maintain the surgical plane of anesthesia.

In order to administer the anesthetic without injecting any vital organs, a twenty gauge (short) needle was used. The skin in the lower right quadrant of the abdomen was grasped between the thumb and index finger, the needle was inserted through it, and the solution was slowly injected.

After the animal was anesthetized, the adhesive tape was

---

* Veterinary Nembutal Sodium, Abbott Laboratories, North Chicago, Illinois.

removed from the extremities, the animal was placed on the operating table, and the head was propped. A periapical radiograph* of each quadrant was obtained in order to examine root length, pulp size and position, and the periapical area in order to determine the selection of the teeth to be used in the study (Figure 1).

After the head was placed in a proper position for operating, a suture of 4-0 black surgical silk was placed through the tip of the tongue and attached to a small hemostat to help ensure an unobstructed airway. A mouth prop of softened beeswax was placed between the molar teeth on the opposite side of the field to be operated.

A 5" x 5" piece of rubber dam material was placed over the teeth in the quadrant to be operated. Because of the small size of the oral cavity of these animals, in many instances, it was not practical to apply the rubber dam to the first permanent molars. An attempt was made to use the dam on these teeth but in a few instances was unsuccessful. When the rubber dam was not used, cotton rolls were used to isolate the teeth. It was noted that salivary flow seemed to be greatly diminished during the course of treatment, and saliva in the area proved to be no problem.

The rubber dam was carefully trimmed with scissors around

---

* Ultra-Speed No. 0 Size, Eastman Kodak Company, Rochester, New York

the nares in order to provide an unobstructed nasal airway. Maintenance of the animal at a good surgical level of anesthesia with an adequate airway was of paramount importance to ensure a successful operative procedure.

After the rubber dam was in position, a 2" x 2" surgical gauze pad was moistened with 70 per cent alcohol and wiped over the teeth and rubber dam in order to enhance surgical cleanliness.

All cavity preparations in this study were prepared with a conventional speed dental engine, handpiece, and sterile burs.

The occlusal preparations on the molars and the labial preparations on the cuspids were initiated with either a #33½ or #35 steel inverted cone bur driven to the dentino-enamel junctions, and outlines of the preparations were established. A #557 steel fissure bur was used to plane the walls of the preparation and was carried in depth to the approximate level of the roof of the coronal pulp chamber. During the preparation of the cavity, air from the chip blower was directed against the field in order to facilitate the removal of dentin chips in the cavity. The entire tooth was wiped with a cotton pellet moistened with 70 per cent alcohol and the roof of the pulp chamber was then removed with a #557 bur.

A cotton pellet moistened with distilled water was placed over the exposed pulp and the operative area was cleansed of

all apparent debris by irrigation with sterile distilled water and with 2" x 2" gauze squares moistened with distilled water.

The coronal pulp was extirpated using the #2, #3 or #4 round bur, depending upon the size of the pulp chamber, at the normal operating speed of the conventional handpiece. Care was taken to ensure removal of the coronal pulp without unduly disturbing the radicular pulp. After the coronal pulp extirpation was completed, cotton pellets moistened with distilled water were used, as were spoon excavators, to clean the debris from the chamber. Pellets of cotton moistened with distilled water were placed over the pulp stumps until the hemorrhage was controlled.

The cotton pellets were removed from the pulp chamber after the development of a blood clot and the medicaments were inserted as follows:

a. A pellet of cotton moistened with formocresol*, with the excess removed by squeezing the pellet between two portions of a sterile towel, was placed in contact with the pulp stumps for approximately five minutes. This pellet was removed and zinc oxide powder was mixed with one

---

* Formocresol (Buckley's Formula), King Specialty Company, Fort Wayne, Indiana.
Tricresol, Formaldehyde and Glycerin.

drop of formocresol and one drop of eugenol to a paste-like consistency. This paste was placed over the amputated pulp stumps and gently tamped to place with a dry cotton pellet covered with zinc oxide powder.

b. Calcium hydroxide powder and one per cent methyl cellulose were mixed into a creamy consistency and placed over the pulp stumps. A dry cotton pellet was placed in the calcium hydroxide powder and carried to the preparation to facilitate tamping the material. Very light pressure was used to ensure complete coverage of the pulp stumps.

After the medicaments were placed over the pulp stumps, a heavier mix of zinc oxide, eugenol, and zinc acetate crystals (accelerator) was carefully placed over the pastes without pressure and allowed to set. A final restoration of silver amalgam alloy was condensed with a minimum of pressure into the prepared cavities.

After the alloy restorations were placed, the teeth were wiped free of debris with 2" x 2" gauze squares dipped in distilled water, and the rubber dam was removed. The suture was removed from the tongue and the latter was moistened with water. All debris and props were removed from the oral cavity.

Postoperative periapical radiographs of the treated teeth

were obtained. Electric shears were used to remove the hair over the right pectoral area and an identifying tatoo was made. The area was kept free of hair to ensure rapid identification.

The animal was returned to the proper cage and covered with paper towels to help contain body heat during the recovery period, which in most instances was of four or five hours duration.

In order to minimize postoperative discomfort, the contents of one capsule of a commercial analgesic* were mixed with water and placed in the cage on the day of the operative procedure. The animals continued to receive food in the biscuit form** once daily, supported with fresh fruit two or three times a week. On the first postoperative day, the animals seemed to be vigorous and active with no apparent aftereffects.

One animal was sacrificed on the 24th postoperative day. The maxillae and mandible were dissected from the soft tissues, sectioned in four quadrants, and the cortical bone was selectively ground thin to facilitate fixation. In this animal, six deciduous and two permanent teeth had been treated

---

* Darvon Compound, Eli Lilly and Company, Indianapolis, Indiana.

** Purina Monkey Chow, Ralston Purina Company, St. Louis, Missouri.

with formocresol for 17 days. Six other deciduous teeth had been treated with calcium hydroxide for 24 days. Two unoperated permanent teeth were examined in order to compare pulps and periapical structures with those of the treated teeth.

Without sacrificing the other monkeys, the teeth were extracted under anesthesia with a #151A or #32A forceps after elevation with a #40 medium-straight elevator.

Twenty-three of the 24 treated deciduous teeth extracted were available for microscopic evaluation. These were extracted during postoperative periods ranging from 38 to 286 days.

Eight permanent teeth were extracted at intervals of 38 to 167 postoperative days in order to compare their pulps to the deciduous pulps.

The dissociated teeth were prepared for fixation by grinding the mesial or distal surface of the tooth, under water, with a carborundum stone until a faint outline of the pulp was visible. The teeth were then placed in a 10 per cent formalin solution for a minimum of two days, decalcified in five per cent formic acid for two to three weeks, and dehydrated in 30 to 100 per cent concentrations of alcohol for 12 to 24 hours in each concentration. Naphtha was used to facilitate the clearance of alcohol from the teeth.

The teeth were immersed in melted paraffin for 48 hours

and blocks containing the teeth were prepared. Seven micron serial sections were prepared of all tissues examined in this study. The sections were mounted and stained with hematoxylin and eosin.

Histologic evaluation of the response of the pulp and periapical tissues of the deciduous and permanent teeth to the formocresol and the calcium hydroxide pulp dressings was accomplished and compared to the pulps and periapical tissues of the unoperated teeth.

RESULTS

Microscopic Evaluation of the Pulps and Periapical Tissues of Teeth Treated with Formocresol Pulp Dressings (Table I).

17 Day Specimens En Bloc - 6 Deciduous and 2 Permanent Teeth.

The pulps of six teeth were found to be "fixed" as previously described[32, 33] by the effects of the medicament to the depth of the apical one-half or one-third. The maxillary and mandibular left deciduous cuspids appeared to contain normal tissue in the major portion of the root canals.

In both permanent teeth, immediately beneath the medicament, the tissue appeared fibrous in nature and eosinophilic in color due to the peculiar effects of the formocresol pulp dressing. Cell and nuclear outline in this region was poor. Apical to this fibrous stratum was a layer more basophilic in appearance because of the presence of many deep staining particles of pyknotic nuclei. The odontoblasts in this region were eosinophilic and rectangular in form.

Masses of dentin chips were observed near the middle one-third or one-half in both canals of the lower right permanent molar and the mesial root canal of the lower left permanent molar. The tissues in the apical one-half or one-third were stained with conventional colors, and the cells were normal in size and contour.

The microscopic findings were similar in four deciduous teeth. The tissue just beneath the medicament was fibrous in

appearance and eosinophilic in color. A variation in cell outline ranging from indistinct to distinct was observed. A layer of deep staining (basophilic) pyknotic nuclei blended into the normal, more apical zone containing cells with good outline and color.

Secondary dentin was prominent along the canal walls in the areas of normal pulp tissue in all eight teeth examined (Figures 2 and 3). The apical tissues and the apices were normal in appearance.

The periodontal structures appeared to be normal in all of the 17 day specimens treated with the formocresol pulp dressing material (Figures 4 and 5). Large quantities of dentin chips were observed in the coronal pulp tissue apical to the amputation sites in all of the teeth in this group.

A zone of moderate to severe localized inflammation was observed immediately apical to the dentin chips in the coronal area of the maxillary left cuspid. The tissue apical to this area was normal in appearance.

Microscopic Evaluation of the Pulp Tissues of the Extracted Teeth Treated with the Formocresol Pulp Dressing (Table I).

51 Day Postoperative Specimens - 6 Deciduous Teeth.

Three of the six treated teeth revealed eosinophilic, fibrous pulp tissue to the depth of the apical one-third. Two canals of the maxillary left second molar appeared to be

eosinophilic and fibrous to the apical one-third. The distal canal of this molar and the entire root canals of the maxillary and mandibular left cuspids contained normal tissue that appeared to be unaffected by the pulp dressing material.

The fixed tissue was eosinophilic, varying from light to dark in intensity. It appeared to be homogeneous and fibrous in nature. The cellular detail of the odontoblasts varied from normal to indistinct. Frequently pyknotic cells were observed immediately beneath the eosinophilic stained areas and adjacent to the more pale staining, normal appearing tissue. Cell outline was clearly visualized and appeared normal in the more apical areas of the pulp tissues. These more normal appearing zones were also observed at the apices in all specimens examined in this group.

Dentin chips were observed in all sections studied. These chips were found in large quantities in the maxillary left second molar at the coronal entrances to the root canals. Dentin chips appeared to be organized in a "bridge-like" structure in the mandibular left cuspid. Near the coronal portion of the maxillary cuspid, fibroblasts were observed to be attempting to organize the tissue immediately beneath the dentin chips and endothelial proliferation was seen in this area. There appeared to be mild, localized, pyknotic inflammatory cells under the dentin chips in the maxillary cuspid (Figure 6).

Secondary dentin formation was found along the canal walls next to the normal tissues, but not near the fibrous, eosinophilic tissues. In many instances, a thin, homogeneous, pale eosinophilic peripheral deposit of "osteodentin" on the dentin chips in the normal region was observed.

286 Day Postoperative Specimens - 6 Deciduous Teeth.

Partial resorption of the mesial roots of the maxillary and mandibular molars was a prominent feature observed in these sections. The crowns of maxillary and mandibular cuspids were abraded almost to the gingivae. The maxillary left cuspid appeared to have an area of acellular, pale staining "fixed" tissue to the depth of the apical one-third where a peculiar syncytium or network of loose, deep-staining, basophilic tissue interspersed with occasional leucocytes was noted. The coronal portion of this chamber was filled with debris. The mandibular left cuspid appeared to have necrotic debris or material extending down to the apical one-sixth of the tooth. This region appeared to be composed of a lattice-like structure of fibers and pyknotic cells giving it a basophilic appearance.

Calcified material with lacunae appeared to be blocking the canals near the coronal areas and immediately beneath the fibrous tissue in both of the maxillary left molars and the mandibular left first molar. Normal tissue was located apical

to these osteodentin-like masses, and the apices of these teeth contained normal tissue with distinct cell outlines. Secondary dentin had been formed on the canal walls next to the normal tissues.

The mandibular left second molar had masses of leucocytes near the middle one-third of the root canals. Vital tissue was observed coronal and apical to these inflammatory cells. Coronal pulp tissue was present near the canal entrances. This coronal tissue was fibrous and eosinophilic in appearance and dentin fragments were dispersed throughout. This "fixed" coronal pulp tissue appeared to blend with a more pale zone of normal tissue located just coronal to the zone of inflammation. The apices of this tooth were composed of normal, paler staining tissue.

Microscopic Evaluation of the Pulps and Periapical Tissues of Teeth Treated with Calcium Hydroxide Pulp Dressings (Table II).

24 Day Specimens En Bloc - 6 Deciduous Teeth.

Normal tissue was present in the major portion of all the pulp canals in these specimens with the exception of the mesial canal of the lower right first molar, which was necrotic to the apical one-third; an area of necrosis was observed to extend down to the middle one-third of the mesial root canal of the lower right second molar. All apical and periapical

tissues in these specimens were normal. Four of the six pulps presented evidence of incomplete calcific repair or bridging. The appearance of the calcific repair varied from that of a light eosinophilic, homogeneous area of dense atubular calcification to an area of calcification containing entrapped cells (presumably odontoblasts) which was more porous and tubular in nature. Two cuspids presented no evidence of calcific repair. The radicular pulps of these cuspids immediately below the amputation sites were eosinophilic in appearance and dentin fragments were interspersed throughout these tissues. Many of the chips found in these areas demonstrated light eosinophilic zones of predentin formation at their peripheries. One of the cuspids showed evidence of an attempt at organization toward calcification; the tissue appeared compressed, fibrous, eosinophilic and organized. Pyknotic inflammatory cells were observed immediately below this zone.

Inflammation was observed to be severe apical to an area of incomplete calcific repair in the distal root canal of the lower right second molar (Figure 7).

Secondary dentin was present along the lateral walls of the root canal below the areas of calcific repair. It was also present in the canals of the teeth in which calcific repair was lacking. Good odontoblastic cell outline was noted in close proximity to this secondary dentin.

Microscopic Evaluation of the Pulp Tissues of the Extracted Teeth Treated with the Calcium Hydroxide Pulp Dressing (Table II).

38 Day Postoperative Specimens - 6 Deciduous and 2 Permanent Teeth.

Evidence of incomplete calcific repair was observed in seven of the eight 38 day postoperative specimens. The eighth specimen, a lower right deciduous cuspid, was observed to have complete calcific repair in every section. Normal tissue was present beneath the areas of calcific repair in all eight specimens and inflammation was seen only in an upper right first deciduous molar and a lower right second deciduous molar. The inflammation was considered to be mild in the latter specimen and was located immediately beneath the area of incomplete calcific repair. A few giant cells were observed in close approximation to isolated dentin chips in the distal root canal.

Penetration of the trifurcation of the roots of the upper right first deciduous molar by the bur during the operative procedure was determined to be the cause of inflammation. The tissues of the trifurcation and the distal root canal were continuous and dentin chips and/or fragments of bone in the trifurcation were dispersed among many inflammatory cells and giant cells. It appeared as if either secondary dentin or osteodentin blocked the distal root canal of this tooth. Below this blockade, vital, non-inflamed tissue was noted to

extend to the apex.

Secondary dentin was observed along the walls and beneath the areas of calcific repair in all the specimens of this group. Odontoblastic outline was not clearly visualized along the periphery of secondary dentin in every section.

51 Day Postoperative Specimens - 2 Permanent Teeth.

Areas of necrosis were found immediately beneath the pulp dressing and dentin chips were present in large numbers dispersed throughout necrotic debris. Normal pulp tissue was observed in the canals of these teeth apical to the areas of incomplete calcific repair. The composition of these areas of calcific repair (bridges) is best described as an area of entrapped connective tissue cells or odontoblasts and necrotic dentin chips with newly apposed osteodentin.

167 Day Postoperative Specimens - 4 Permanent Teeth.

Normal pulp tissue was observed in the canals of these specimens. Calcific repair was observed in three of the four teeth. There was no evidence of calcific repair or bridging in the mandibular left molar but masses of secondary dentin were seen in the coronal portions of the canals of this tooth associated with a very large number of leucocytes. Both canals in this tooth appear to have abscesses in the middle one-third. The apex of the distal root contained a moderate

number of inflammatory cells (Figures 8 and 9).

Inflammation was evident beneath the incomplete calcific bridge in the distal root of the maxillary left permanent molar. The mesial root of this tooth showed no evidence of inflammation. Inflammatory cells also were observed in a small quantity in the mandibular right molar but were confined to the coronal portion.

Giant cells were seen in close proximity to dentin chips in two of the three teeth observed to have inflammatory cells. A few Russell bodies were present in the mesial root canal of the lower left first permanent molar among the masses of leucocytes. Secondary dentin was present along the lateral walls of the canals of all the teeth.

286 Day Postoperative Specimens - 5 Deciduous Teeth.

Normal tissue was observed and no evidence of inflammatory cells was noted in two of the five treated teeth. Two pulps were completely necrotic and the partially resorbed mesial root of the upper right first molar revealed a granuloma at the apex. Two teeth and the distal canal of the upper right first molar had incomplete calcific repair or bridging. Osteodentin was seen in the canals of two teeth. This material nearly obstructed the distal root canal of the upper right second molar. The areas described as calcific repair in this canal resembled the tissue described as osteodentin. Secondary

dentin was deposited under the areas of calcific repair along the lateral walls of the root canals.

TABLES AND FIGURES

TABLE I.

MICROSCOPIC FINDINGS IN TWENTY TEETH TREATED WITH FORMOCRESOL.

	No. of Monkey	Tooth	No. of Postoper. Days	Evidence of "Fixation"	Normal Tissue	Inflam. Cells	Osteo-Dentin
1.	I	ULC	17	-1	+	-2	-
2.	I	ULD	17	+	+	-	-
3.	I	ULE	17	+	+	-	-
4.	I	MLC	17	-1	+	-	-
5.	I	MLD	17	+	+	-	-
6.	I	MLE	17	+	+	-	-
7.	I	#19	17	+	+	-	-
8.	I	#30	17	+	+	-	-
9.	II	ULC	51	-1	+	+13	-
10.	II	ULD	51	+	+	-	-
11.	II	ULE	51	+4	+	-	-
12.	II	MLC	51	-1	+	-	-
13.	II	MLD	51	+	+	-	-
14.	II	MLE	51	+	+	-	-
15.	III	ULC	286	+	+	+5	-
16.	III	ULD	286	+	+	-	-7
17.	III	ULE	286	+	+	-	-8
18.	III	MLC	286	+	+	+6	-
19.	III	MLD	286	+	+	-	-9
20.	III	MLE	286	+	+	+2	-

+ = Positive
- = Negative
U = Maxillary
M = Mandibular
L = Left
R = Right
C = Deciduous Cuspid
D = First Deciduous Molar
E = Second Deciduous Molar

1 = "Blocking" effect caused by dentin chips
2 = Moderate to severe; coronal area under dentin chips
3 = Mild; pyknotic inflammatory cells
4 = Fixed tissue in mesial and lingual canals only
5 = Mild at apex
6 = Syncytium of scattered inflammatory cells at apex
7 = At coronal area of mesial canal
8 = Coronal area
9 = Masses in both canals

TABLE II.

MICROSCOPIC FINDINGS IN TWENTY-FIVE TEETH TREATED WITH CALCIUM HYDROXIDE.

	No. of Monkey	Tooth	No. of Postoper. Days	Calcific Repair	Normal Tissue	Inflam. Cells	Osteo-Dentin
1.	I	URC	24	-1	+	-	-
2.	I	URD	24	IN	+	-	-
3.	I	URE	24	IN	+	-	-
4.	I	MRC	24	-1	+	-	-
5.	I	MRD	24	IN	+5	-	-
6.	I	MRE	24	IN	+6	+8	-
7.	II	URC	38	IN	+	-	-
8.	II	URD	38	IN	+	+9	+13
9.	II	URE	38	IN	+	-	-
10.	II	MRC	38	COM	+	-	-
11.	II	MRD	38	IN	+	-	-
12.	II	MRE	38	IN	+	+10	-
13.	II	#3	38	IN	+	-	-
14.	II	#30	38	IN	+	-	-
15.	II	#14	51	IN	+	-	-
16.	II	#19	51	IN	+	-	-
17.	III	#3	167	IN	+	-	-
18.	III	#14	167	IN	+	+	-
19.	III	#19	167	-	+	+11	-
20.	III	#30	167	IN	+	+12	-
21.	III	URC	286	IN	+	-	+14
22.	III	URD	286	IN2	+7	-	-
23.	III	URE	286	IN	+	-	+14
24.	III	MRC	286	-3	-	-	-
25.	III	MRE	286	-4	-	-	-

+ = Positive
- = Negative
U = Maxillary
M = Mandibular
L = Left
R = Right
C = Deciduous Cuspid
D = First Deciduous Molar
E = Second Deciduous Molar
IN = Incomplete
COM = Complete

1 = "Blocking" effect
2 = Incomp. in distal canal
3 = Entire canal necrotic
4 = Canals necrotic
5 = Necrotic mesial canal
6 = Portion of mesial canal necrotic
7 = Mesial canal necrotic
8 = Severe; under incomp. bridge
9 = From bifurcation into pulp
10 = Mild; under incomp. bridge
11 = Abscesses in both canals
12 = Mild in coronal area
13 = Occludes middle 1/3 of distal canal
14 = Blocking canal entrances

Figure 1. Preoperative periapical radiograph. A preoperative radiograph used to examine root length, pulp size and position, and the periapical regions.

Figure 2. Deciduous cuspid treated with formocresol (17 days). A low power photomicrograph of a lower left deciduous cuspid 17 days after treatment with formocresol.

A. Medicament and dentin chips.
B. Compressed fibrous fixed tissue blending into
C. An area of normal tissue containing
D. Secondary dentin and cells of good outline and color.

Hematoxylin and eosin stain.
Original magnification x 35.

A
B
C
D

Figure 3. Deciduous first molar treated with formocresol (17 days). A low power photomicrograph of the distal root of a lower left first deciduous molar 17 days after formocresol treatment.

A. Coronal pulp chamber filled with medicament and dentin chips.
B. Area of fixed tissue.
C. Secondary dentin between areas of fixed and normal tissue.

Hematoxylin and eosin stain.
Original magnification x 35.

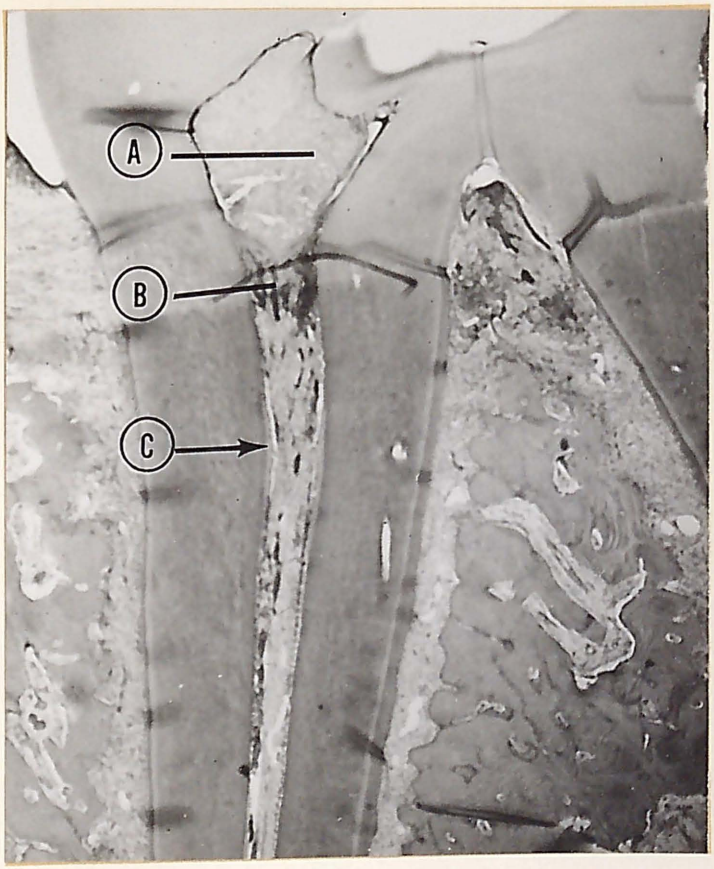
A
B
C

Figure 4. Permanent first molar treated with formocresol (17 days). A high power photomicrograph of the apex and surrounding structures of the distal root of a lower left first permanent molar 17 days after treatment with formocresol. No apparent effects of the drug on the pulp or periapical tissues were observed.

Hematoxylin and eosin stain.
Original magnification x 100.

Figure 5. Unoperated permanent first molar. A medium power photomicrograph of the apex and surrounding structures of the distal root of an upper right first permanent molar in the same animal as illustrated in Figure 4. This tooth was unoperated and was used for comparison with the pulps and periapical structures of the operated permanent teeth.

Hematoxylin and eosin stain.
Original magnification x 75.

Figure 6. Deciduous cuspid treated with formocresol (51 days). A low power photomicrograph of a maxillary left deciduous cuspid 51 days after formocresol treatment.

A. Mass of dentin chips.
B. Area of fibrous normal tissue containing a small number of pyknotic inflammatory cells.
C. Secondary dentin.

Fixation of the pulp tissue was not observed.

Hematoxylin and eosin stain.
Original magnification x 25.

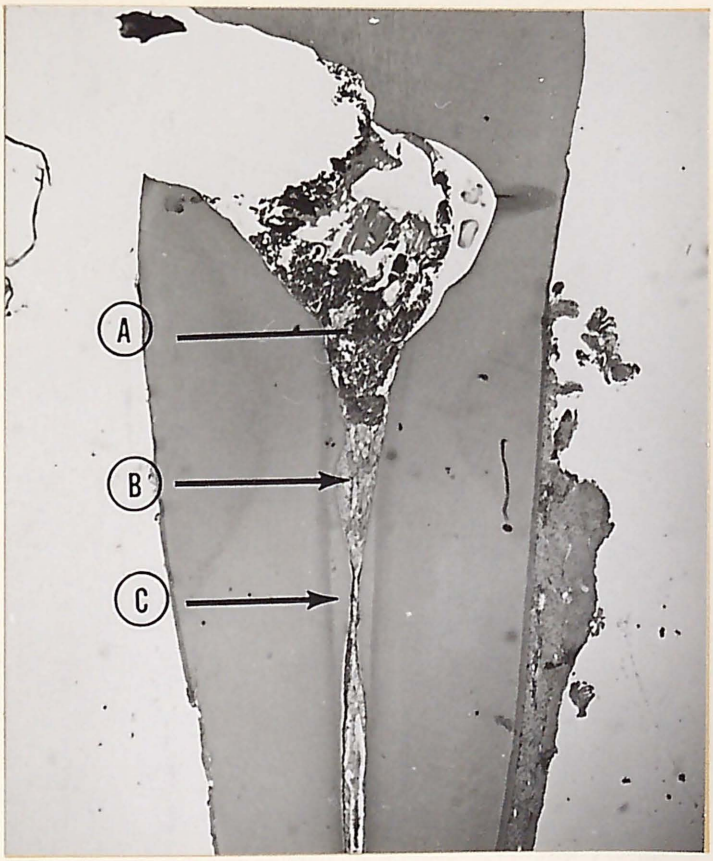
A
B
C

Figure 7. Deciduous second molar treated with calcium hydroxide (24 days). A high power photomicrograph of a mandibular right second deciduous molar 24 days after calcium hydroxide treatment.

A. Area of incomplete calcific repair.
B. Area of severe inflammation.

Hematoxylin and eosin stain.
Original magnification x 100.

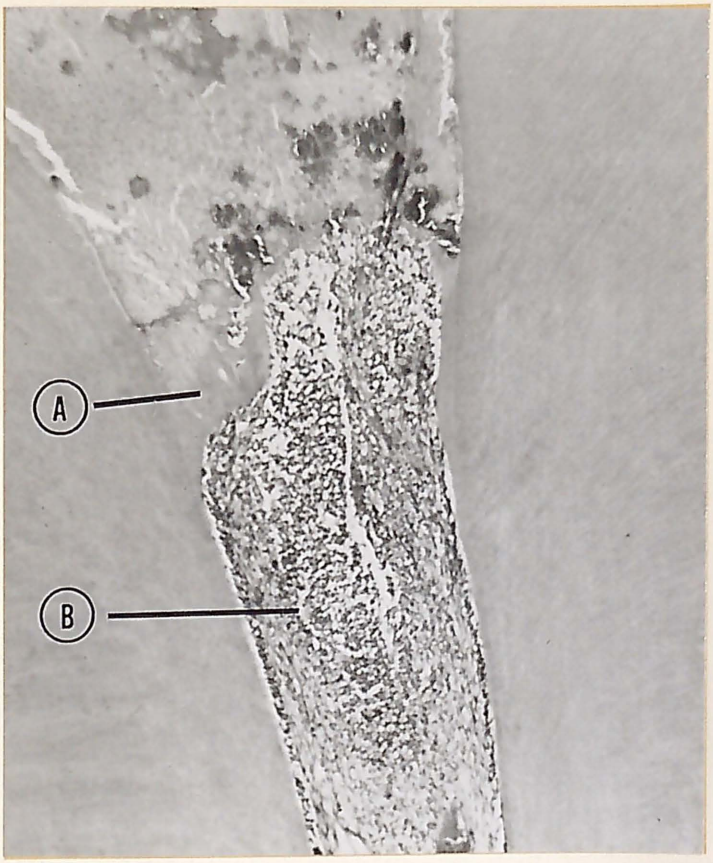
A
B

Figure 8. Permanent first molar treated with calcium hydroxide (167 days). A medium power photomicrograph of a mandibular left first permanent molar 167 days after calcium hydroxide treatment.

A. Medicament and dentin chips.
B. Masses of secondary dentin.
C. Abscess formation.

Hematoxylin and eosin stain.
Original magnification x 75.

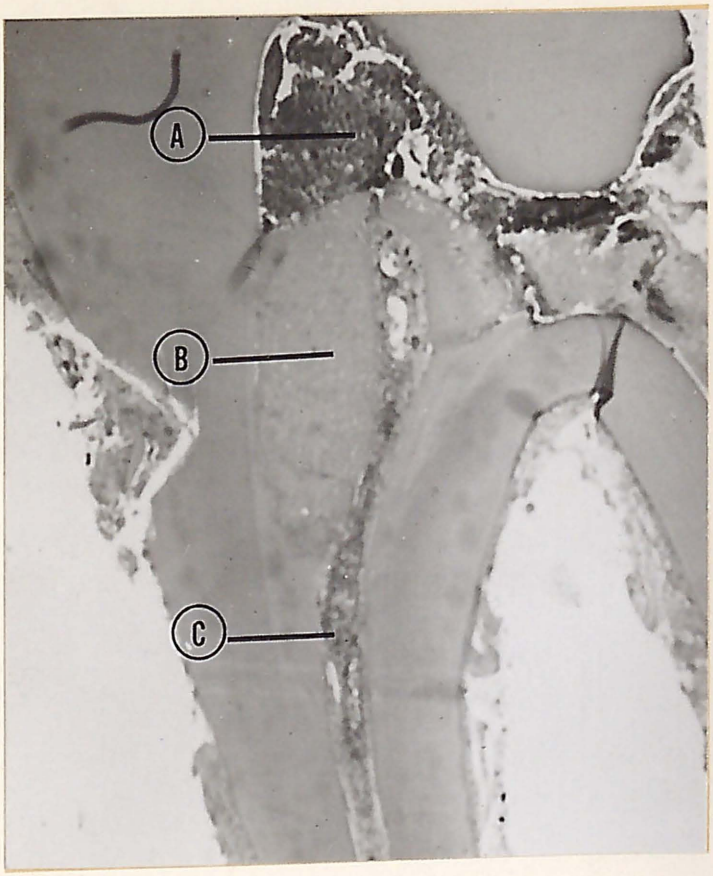
A
B
C

Figure 9. Permanent first molar treated with calcium hydroxide (167 days). A low power photomicrograph of the mandibular left first permanent molar described in Figure 8.

A. Pulp abscesses.
B. Masses of secondary dentin in mesial canal.
C. Moderate number of inflammatory cells at apex of distal root.

Hematoxylin and eosin stain.
Original magnification x 25.

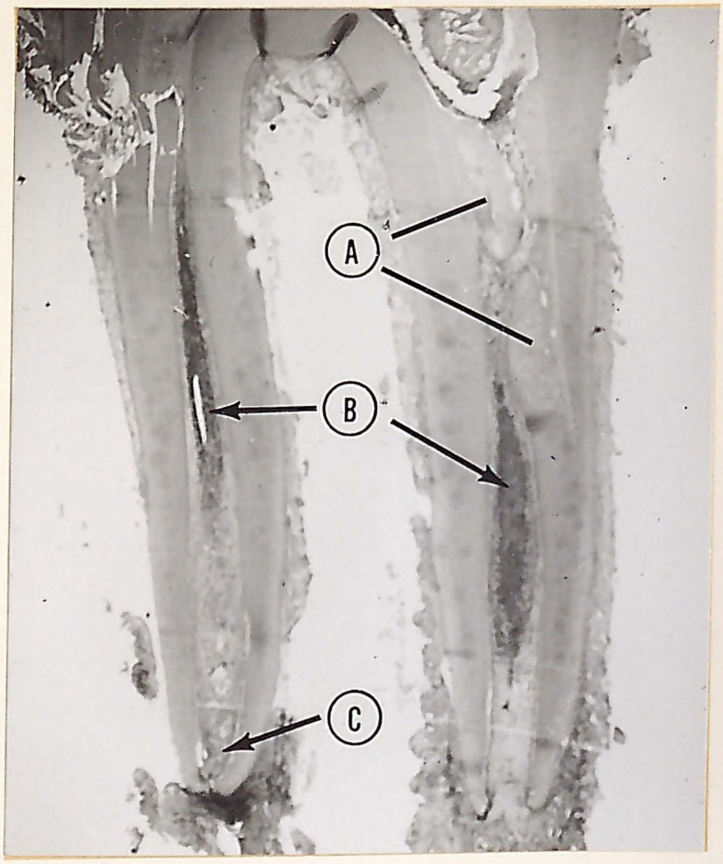
A
B
C

Figures 10 A and B. Diffusion of formocresol. These diagrams illustrate a tooth treated with formocresol.

A. Medicament and dentin chips.
B. Area of fixed tissue.
C. Area of normal tissue.
D. Apical area of fixed tissue.
E. Apical area of normal tissue.

This alternation of fixed and normal tissue might be due to an uneven diffusion of the formocresol through the pulp tissue as illustrated in Figure 10 B.

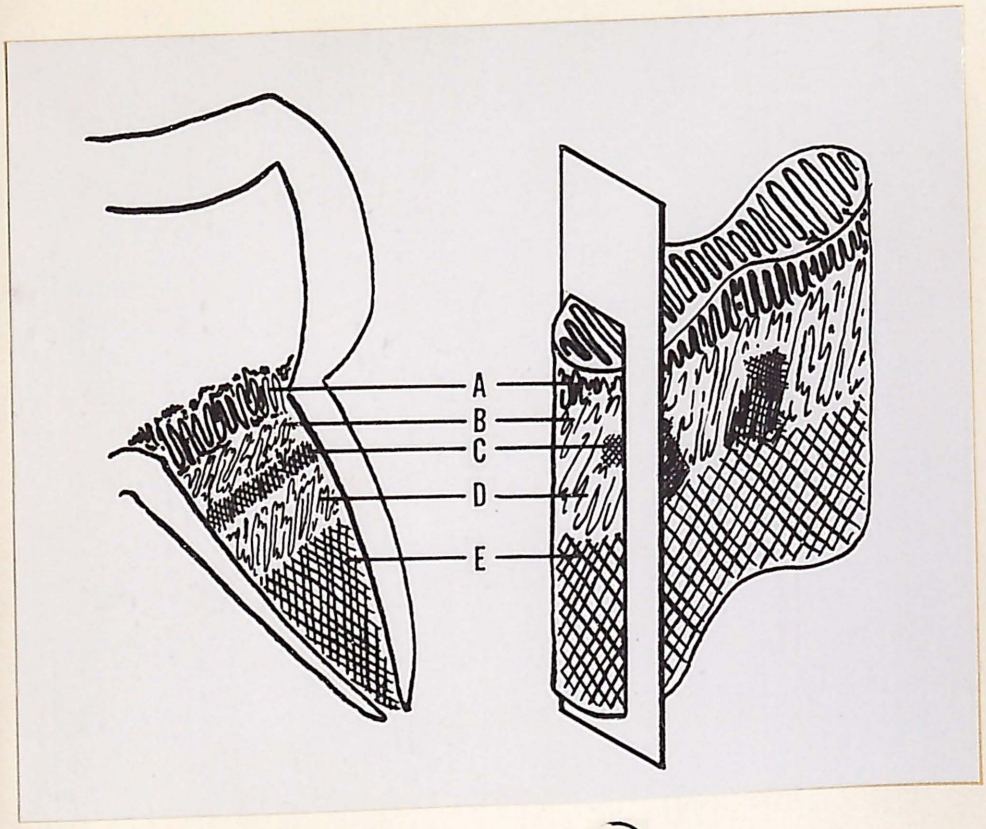

A B

Figure 11. Relative size of bur and cavity preparation. Photomicrograph of the tooth described in Figure 6 illustrates the relative size of a $33\frac{1}{2}$ inverted cone bur and the cavity preparation to account for the technical excess of dentin chips found in the specimens examined in this study.

Figure 12. Deciduous cuspid treated with calcium hydroxide (38 days). A high power photomicrograph of a mandibular right deciduous cuspid 38 days after calcium hydroxide treatment. Illustrates an area of complete calcific repair or bridging.

A. Medicament and dentin chips in coronal chamber.
B. Area of calcific repair continuous with secondary dentin.
C. Normal pulp tissue.

Hematoxylin and eosin stain.
Original magnification x 100.

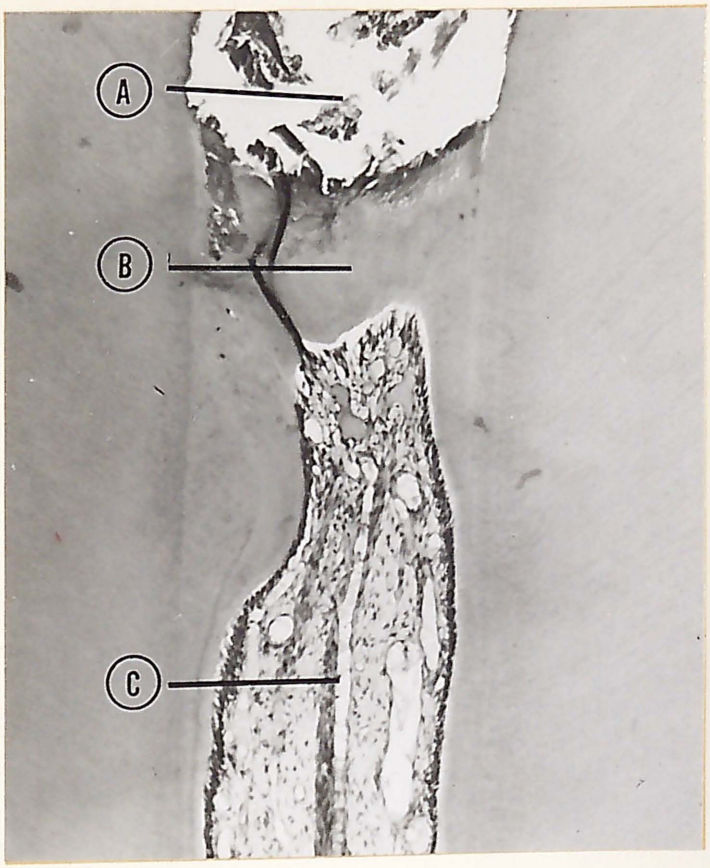
A
B
C

Figure 13. Permanent first molar treated with calcium hydroxide (38 days). A high power photomicrograph of the distal root of a maxillary right first permanent molar 38 days after calcium hydroxide treatment. Illustrates an area of complete calcific repair or bridging.

A. Medicament and dentin chips in coronal chamber.
B. Area of calcific repair.
C. Normal tissue.

Hematoxylin and eosin stain.
Original magnification x 100.

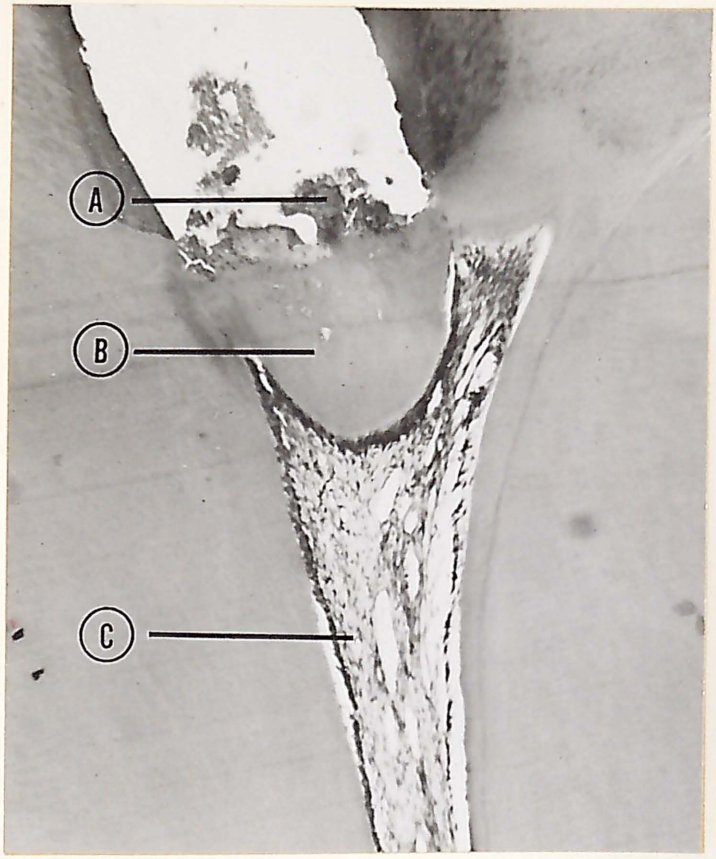
A
B
C

Figure 14. Deciduous second molar treated with calcium hydroxide (24 days). A high power photomicrograph of the distal root of a mandibular right second deciduous molar 24 days after calcium hydroxide treatment.

A. Necrotic tissue interspersed with dentin chips in coronal area.
B. Area of complete calcific repair.
C. Inflammation.
D. Normal, non-inflamed pulp tissue.

Hematoxylin and eosin stain.
Original magnification x 100.


A
B
C
D

Figure 15. Deciduous first molar treated with calcium hydroxide (24 days). A high power photomicrograph of the distal root of a maxillary right first deciduous molar 24 days after calcium hydroxide treatment.

A. Medicament and dentin chips.
B. Complete calcific repair or bridge formation.
C. Normal tissue.

Hematoxylin and eosin stain.
Original magnification x 100.

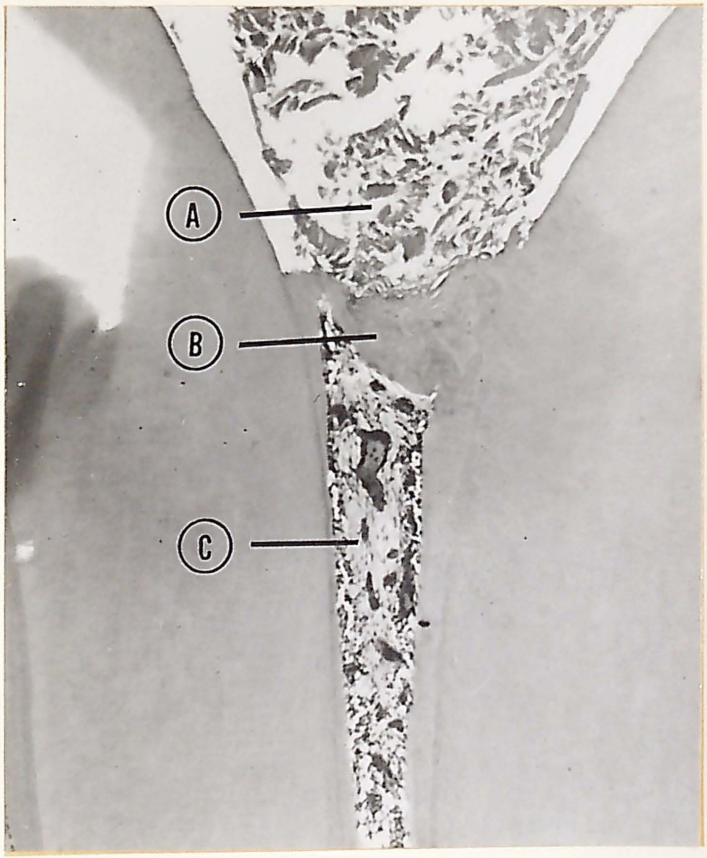
A
B
C

Figure 16. Deciduous cuspid treated with calcium hydroxide (24 days). A high power photomicrograph of another section of the tooth described in Figure 15 to illustrate the absence of complete calcific repair.

A. Medicament and dentin chips.
B. Initiation of calcific repair.
C. Normal tissue.

Hematoxylin and eosin stain.
Original magnification x 100.

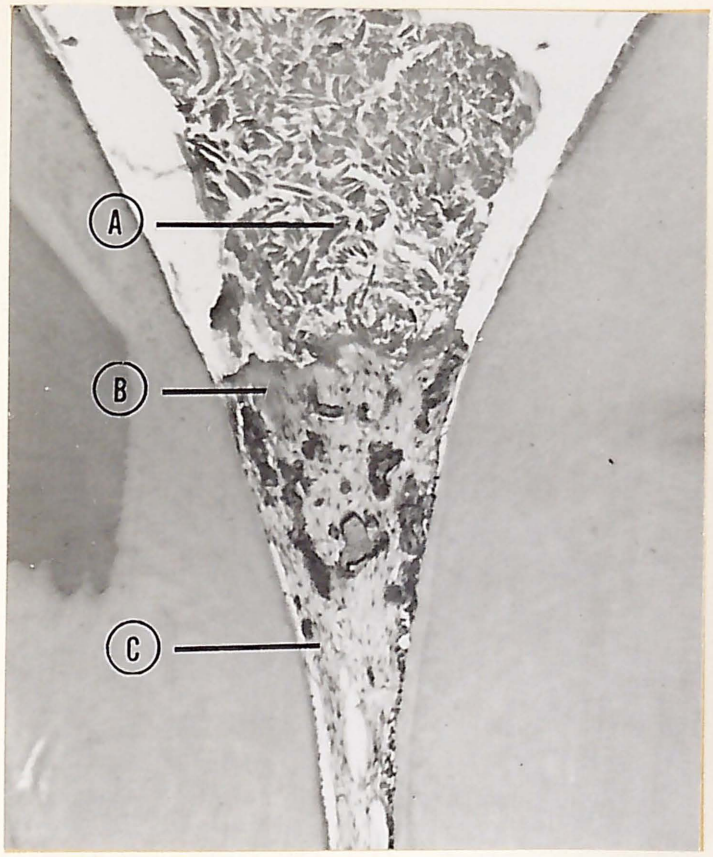
A
B
C

Figure 17 A. Deciduous cuspid treated with calcium hydroxide (38 days). A high power photomicrograph of a mandibular right cuspid 38 days after treatment with calcium hydroxide.

A. The area of calcific repair is thin in the lingual region of the canal.

Hematoxylin and eosin stain.
Original magnification x 100.

Figure 17 B. A diagram of the tooth described in Figure 17 A.

B. An area of incomplete calcific repair located near the lingual region of the canal.

Figure 17 C. This diagram illustrates the labial aspect of the tooth described in Figure 17 A and Figure 17 B and represents a probable radiographic appearance of the tooth.

C. The area of calcific repair would appear to be complete.

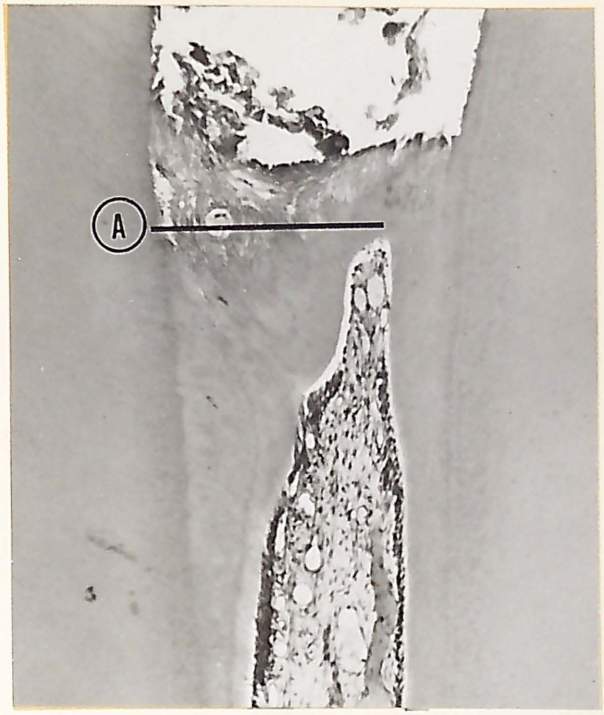

A

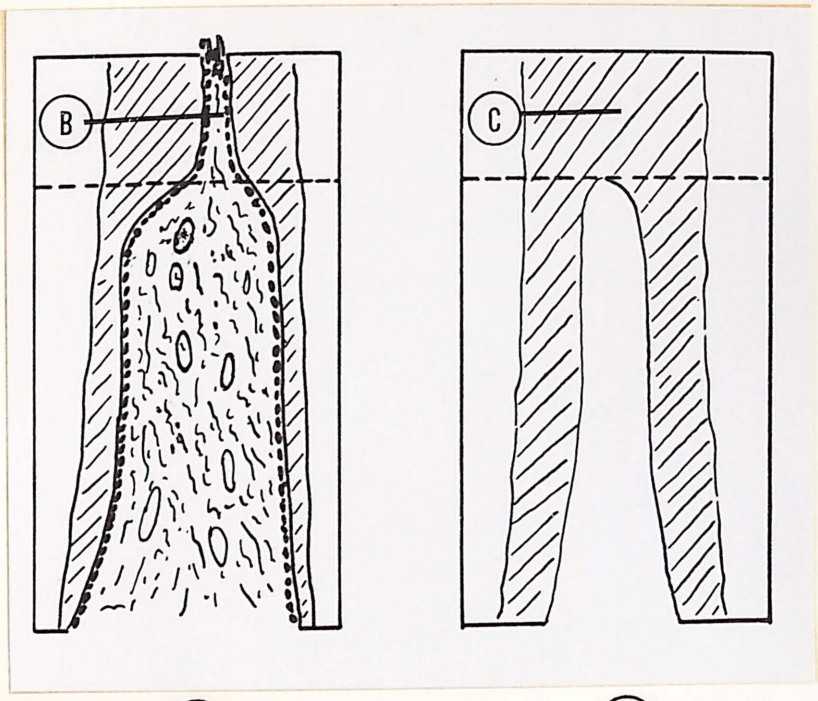

B C

DISCUSSION

Selection and Maintenance of Monkeys.

There is a diversity of opinions as to the relative value of the primate for use as an experimental animal[72, 73]. The author believes that the rhesus monkey is an excellent animal to use in dental research. Although these animals are somewhat difficult to handle, an established routine for removing them from their quarters with a minimum of duress and a maximum of patience and diligence soon establishes confidence for the investigator.

Selection of the animals proved to be a difficult task because of the lack of agreement as to the eruption dates of the first permanent molars[66, 67]. The mandibular first permanent molar was reported to erupt into the oral cavity in a time range of 13 to 24 months and the maxillary first molar was reported to erupt in a time range of 14 to 24 months. Physical measurements such as crown-rump length, standing height, and body weight are used to select animals in a given age group in a colony[66, 68]. Utilizing the knowledge of dentition dates and physical measurements, it was decided to order three animals of the same approximate age (20 months). Animals of this age were selected so as to ensure, with reasonable accuracy, the presence of a full complement of deciduous teeth as well as the first permanent molars. Unfortunately, although the animals were nearly the same size and weight, the first permanent molars in one animal had not erupted. Radiographs

and correlation with dentition data helped to establish the fact that this animal was at the lower end of the eruption period. Thus, a delay in the operating schedule was encountered.

After the animal is anesthetized and the desired surgical level is obtained, vital signs must be constantly observed and an unobstructed airway must be maintained. At least one assistant should be available to help conduct each procedure. This assistance enables the operator to rapidly carry out his investigation in an uneventful manner. It was observed that the animal could safely be maintained at a surgical level for as long as two and one-half to three hours without loss of life or any apparent deleterious postoperative effects. Postoperative maintenance is important. The animals should be covered with paper or a suitable covering material so as to ensure retention of body warmth. Analgesics for postoperative discomfort should be administered, and fresh food and water should be made available. Recovery time, or the time lapse until the animal was able to carry on normal activity, was observed to be in a range of five to eight hours.

The author is quite enthusiastic about the possibility of using the primate of another species that has been reported to be quite docile and manageable[74].

Another area for future consideration is the use of tranquilizers for the pre and postoperative management of the

animals. The administration of a tranquilizer may reduce the activity of the animal to a level that would facilitate handling by an investigator with a minimum of distress for the operator and/or the animal. This removal of hyperactivity would allow the operator to frequently examine the animal during a postoperative period without the use of a general anesthetic.

Microscopic Observations.

Microscopic observations of twenty-five teeth treated with the formocresol pulp dressing material were compared to those findings in previous studies. One group of investigators[33] reported that the amount of fixation of pulp tissue induced by the formalin drug was directly proportional to the length of time the drug was in contact with the pulp. They described complete fixation of the human pulp when the formocresol pulp dressing was in contact with the pulp over a long period of time. This finding was not observed in this study. Another investigator[32] observed a marked difference in the response of the deciduous and permanent pulp tissues to a paraformaldehyde preparation. He stated that the deciduous pulp was mainly of a fibrous nature, whereas bone formation was an outstanding feature in the permanent pulp tissue. These findings were not observed in this study. No calcific deposits other than structures regarded to be secondary or reparative dentin

were observed in the permanent teeth, whereas three deciduous teeth (286 days) were observed to have calcific structures described as osteodentin. The author could not observe any noticeable differences, with the exception of the described osteodentin material, of the deciduous and permanent teeth to the formocresol material. If paraformaldehyde and formocresol produce different pulpal reactions, then the differences might possibly be explained. One investigator[34] reported complete pulpal fixation observed in the 60 day to two year range in the human series. In no instance was complete pulpal fixation observed in this study. Perhaps the disagreement in results might be due to differences in the connective tissue reactions of the monkey and human. However, this seems unlikely, and no evidence to this effect can be furnished.

The presence of inflammatory cells found in the formocresol treated teeth was not indicative of failure in every instance. Areas of pyknotic inflammatory cells were observed under the areas of fibrous fixation in a few of the teeth examined. It is quite possible that these areas were in an early stage of fixation and had these teeth been examined at a later date, these areas would have been considered to be fixed.

Various degrees of fixation in the same root canal were observed. An uneven diffusion of the material throughout the pulp would explain the variations in depth of fixation. If

this pattern of fixation occurred, and the plane of sectioning varied, an observation such as noted in Figures 10 A and 10 B would be made.

The effect of the formocresol on the pulp tissues of four cuspids (Table I) was possibly negated by the presence of masses of dentin chips blocking the root canal entrances (Figure 6). This phenomenon was similar to that described in the calcium hydroxide treated teeth where normal pulp tissue was observed in the absence of bridging or calcific repair in two deciduous cuspids (Table II). The small size of the teeth used in this study necessitated an extremely small cavity preparation; one that could be adequately prepared without an excessive weakening of tooth structure. Figure 11 demonstrates a #33½ inverted cone bur superposed on the cavity preparation of a deciduous cuspid. In order to facilitate the placement of the pulp dressing, intermediate base, and silver amalgam alloy, the preparation had to be enlarged with a fissure bur. Irrigation with sterile distilled water and a stream of air apparently did not remove all debris from the preparation.

Observations of the stimulation of calcific repair or bridging using the calcium hydroxide pulp dressing has been previously reported[38, 41, 43, 47]. This phenomenon was observed in this study (Figures 12 and 13). Calcific repair and the lack of calcific repair was also noted in the presence of inflammation, as previously reported (Figure 14)[39, 61, 64].

The predominance of incomplete calcific repair observed in this study emphasizes the importance of thin serial sections when examining histologic sections of teeth treated with compounds known to produce the "bridging" effect. There is reason to believe that the semi-serial section technique that produces thick sections might not reveal a true picture of calcific repair. Figures 15 and 16 show the presence of complete and incomplete bridging in the same root canal.

Many clinical investigators have used the radiographic interpretation of calcific repair or bridging as evidence of successful pulp therapy. This criterion used alone may be faulty and misleading. Figure 17 A shows a deciduous cuspid treated with calcium hydroxide. This tooth was sectioned in a labio-lingual plane. The calcification of the bridge was thin near the lingual wall in this section while deeper sections revealed incomplete calcification (Figure 17 B). A radiograph of this tooth made with the central ray passing in a labio-lingual direction might erroneously suggest the presence of a complete calcified bridge (Figure 17 C). This observation again emphasizes the need for clinico-histologic evaluations when determining the value of certain procedures used in clinical dentistry.

A calcified structure resembling osteodentin or dentinoid material was observed in the canals of three teeth. In one of these teeth (286 days) the osteoid material appeared to be

continuous with the areas of calcific repair. In the second tooth (286 days) this material appeared to be blocking the canal below the area of bridging, while in the third tooth (38 days) it occluded the middle one-third of one of the canals. The significance of this material is not known. Possibly it is a pathologic or metaplastic change of the pulp tissue as a result of the procedure and, in effect, constitutes a failure of treatment[22].

Internal resorption of the root canal walls was not observed in this study.

No differences in the reactions of the deciduous and permanent pulps to the calcium hydroxide pulp dressing could be determined in this study.

No differences in pulp morphology could be determined in the areas evaluated to be normal in the treated teeth as compared to the unoperated teeth.

No apparent effect of formocresol on the periapical tissues was observed in this study when compared to the unoperated teeth (Figures 4 and 5). If this formocresol material was placed in contact with the periapical tissues, these tissues might respond to the material as did the subcutaneous connective tissue in the rat when cotton pellets saturated with formocresol were inserted in the dorsal region. In this latter study[75], it was noted that a limited leucocytic infiltration was the immediate response to the implants. These leu-

cocytes became fixed (pyknotic in appearance) as did the vessels in the region immediately in contact with the implants. Specimens observed over a period of days revealed granulation tissue formation at the outer periphery, typified by the presence of a large number of newly formed capillaries (endothelial proliferation), fibroblasts, and an abundance of leucocytes in the tissue stroma. After a longer time lapse the granulation tissue appeared more fibrous in nature and scar formation was observed.

It is quite possible that a similar reaction of the periapical tissues might occur if the formocresol material contacted the periapical structures. An immediate fixation of these tissues might occur; but after a period of time, in this region of great collateral circulation, "scavenger" cells would phagocytize the fixed tissues simultaneously with granulation tissue formation. If observed over a longer period of time, there would probably be a remodeling and rebuilding of osseous and soft tissues in the periapical region.

Since the partial pulpectomy technique for deciduous teeth is practiced in which the radicular pulp tissue is extirpated and a formalin compound is inserted into the root canals, further studies of the periapical reactions to these formaldehyde materials should be considered. The treated teeth could be obtained with the periapical structures in a block of tissue at various time intervals and studied micro-

scopically in order to observe the reactions.

Loss or fracture of the amalgam alloy restorations occurred in three of the five inflamed and/or necrotic pulps treated with formocresol and in four of the ten inflamed pulps treated with calcium hydroxide. These findings are significant because of the possibility of contamination of the treated pulps from substances in the oral cavity. The presence of inflammation in the treated pulps of the teeth with intact restorations cannot be readily explained.

SUMMARY

The purpose of this investigation was to attempt to duplicate in monkeys two clinical procedures recommended for the management of cariously exposed human deciduous and young permanent teeth and to observe the responses of the pulp and periapical tissues to the calcium hydroxide and formocresol pulp dressing materials.

The original experimental sample contained thirty-six deciduous and twelve young first permanent molars in three rhesus monkeys approximately twenty months old. Amputation of the coronal pulp tissues and the placement of the pulp dressing materials over the radicular pulpal stumps were performed on 46 teeth, and the treated teeth were observed microscopically over a period of seventeen to two hundred and eighty-six postoperative days. Two permanent maxillary first molars were unoperated. The pulp and periapical tissues of these two teeth were compared to the corresponding tissues of the treated teeth.

All twenty teeth treated with the formocresol pulp dressing material gave evidence of vital tissue in either the apical one-half or one-third or in the major portion of the canals.

Fifteen of the twenty teeth treated with formocresol produced evidence of fixation by the compound to the depth of the apical one-half or one-third of the root canal. Excessive dentin chips blocking the canals of five teeth apparently pre-

vented pulpal fixation. This technical excess of dentin chips is a difficult problem to solve when using sound, small teeth.

Three pulps treated with formocresol revealed fixed leucocytes dispersed among an excess of dentin chips blocking the root canal entrances. Two pulps were observed to have leucocytes in the apical area. One of these two pulps was necrotic in the remaining portion of the canal, and the other pulp revealed a peculiar syncytium in the apical one-third of the canal in which scattered inflammatory cells were observed.

Fifteen of the twenty-five teeth treated with calcium hydroxide presented normal tissue. Only one of the twenty-five teeth observed gave evidence of complete calcific repair or "bridging". Nineteen teeth exhibited incomplete calcific repair. Five teeth showed no evidence of calcific repair. Ten of these twenty-five teeth were observed to have inflamed or necrotic pulp tissues. The range of inflammation was judged to range from mild to severe. Seven of these ten teeth with pulps also presented incomplete calcific repair. The other three teeth showed no evidence of repair. Osteodentin was observed in three teeth treated with calcium hydroxide. One of these three teeth exhibited pulp inflammation.

Osteodentin was present in the canals of three deciduous molars treated with formocresol and three deciduous molars treated with calcium hydroxide. These six teeth also revealed normal tissues free from inflammatory cells which indicated

persisting vitality.

No apparent differences were noted when comparing the effects of the pulp dressing materials on the deciduous and the permanent teeth with the exception of osteodentin which was observed in the deciduous teeth treated with both pulp dressing materials.

There were no noticeable effects of the pulp dressing materials on the periapical tissues. Root formation and physiologic resorption were observed to be unaffected within the time periods studied.

CONCLUSIONS

Five of twenty deciduous teeth treated with formocresol and ten (seven deciduous and three permanent) of twenty-five teeth treated with calcium hydroxide were considered to be failures in this study because of the presence of inflammation and/or necrosis in all or portions of the pulps. The percentages of success were determined to be 75 and 60 for the teeth treated with formocresol and calcium hydroxide respectively.

Only one of the twenty-five teeth treated with calcium hydroxide demonstrated complete calcific repair or bridging in every section. This observation emphasizes the need for thin serial sections for microscopic examination.

The calcified material, described as osteodentin in pulps treated with both materials, was dissimilar to material described as calcific repair or bridging. It is significant because it was deposited after treatment giving evidence of continuing vitality of these pulps.

Fixation as a result of the formocresol was in many instances diffuse in action and was observed to penetrate to the apical one-half or one-third of the same tooth.

Based on the conditions of this study, the results give the impression that the formocresol pulp therapy performed on the deciduous teeth, was superior to the calcium hydroxide therapy.

Further histologic examinations of the pulp and periapical

responses, particularly to the formalin containing compounds, using other techniques of application, at longer postoperative intervals should be performed in order to further contribute to an understanding of this type of compound and its effect on the tissues.

In view of the findings observed when a technical excess of dentin fragments remained in the pulp canals, further investigations into the use of autogenous, caries-free dentin chips as a pulp dressing material should be performed.

REFERENCES

1. Spooner, S.: Guide to Sound Teeth or a Popular Treatise on the Teeth. New York, Waley and Long, 1836.

2. Burdell, H.: Observations on the Structure, Physiology, Anatomy, and Diseases of the Teeth. New York, Gould and Newman, 1838.

3. Koecker, L.: Principles of Dental Surgery. Baltimore, Amer. Lib. of Den. Science, 1842.

4. Arthur, R.S.: Treatment of dental caries, complicated with disorders of the pulp and peridental membrane. Amer. J. D. S., 3, 1852.

5. Taft, J.: A Practical Treatise on Operative Dentistry. Philadelphia, Lindsay and Blakiston, 1860.

6. Chase, H.S.: Results of pulp treatment. Den. Cosmos, 8:517, 1866.

7. Hitchcock, T.B.: Oxychloride of zinc to protect dental pulps. Den. Cosmos, 13:131, 1871.

8. Arnold, O.: Post-mortem treatment of the dental pulp. Den. Cosmos, 35:126, 1893.

9. Allen, W.H.: The preservation of exposed dental pulps. Den. Cosmos, 7:422, 1866.

10. Atkinson, W.H.: Dental pulps and their treatment. Den. Cosmos, 10:281, 1868.

11. Witzel, A.: The covering of exposed pulps. Den. Register, 35:1, 1881, (Translated by H. Thompson).

12. Christensen, W.E.: Some comments upon "The Herbst Method of Treating Pulps". Den. Cosmos, 35:363, 1893.

13. Harlan, A.W.: "The Herbst Method of Treating Pulps". Den. Cosmos, 35:169, 1893.

14. New Inventions Formagen. J. Brit. Den. Assoc., 18:525, 1897.

15. Boennecken, H.: About new methods of treating diseased pulps. Ohio D. J., 19:183, 1899, (Translated by H. Prinz).

16. Buckley, J.P.: A rational treatment for putrescent pulps. Den. Review, 18:1193, 1904.

17. Boennecken, H.: Pulp amputation. Brit. D. J., 30:1348, 1909.

18. Alvord, W.R.: Prognosis and treatment of pulpless deciduous teeth. J.A.D.A., 16:93, 1929.

19. Bossard, F.J.: Pulp amputation: its justification and technique. Den. Cosmos, 71:41, 1929.

20. Müller, O.: Histological and bacteriological findings in pulp amputation. Den. Cosmos, 71:57, 1929.

21. Levine, J.H.: Pulp amputation - a means of preventing periapical pathosis. Den. Cosmos, 76:970, 1934.

22. Orban, B.: Metaplastic changes in pulp due to large doses of paraformaldehyde. J. D. Res., 14:189, 1934.

23. Sweet, C.A.: Treatment for deciduous teeth with exposed pulps. Washington Univ. D. J., 3:78, 1936.

24. Easlick, K.A.: Pulp management for deciduous and young permanent teeth. J.A.D.A., 26:100, 1939.

25. Easlick, K.A.: Management of pulp exposures in the mixed dentition. J.A.D.A., 30:179, 1943.

26. Low, M. and Krasnow, F.: Pulpotomy - a successful pulp treatment for deciduous and young permanent teeth. New York State D. J., 16:59, 1950.

27. Castagnola, L. and Orlay, H.G.: Mortal amputation of the pulp. Brit. D. J., 90:280, 1951.

28. Rabinowitch, B.Z.: Pulp management in primary teeth. Oral Surg., Oral Med., Oral Path., 6:542, 1953.

29. Mohammed, C.I. and Schour, I.: The pulpal response of the rat incisor to cavity preparation and paraformaldehyde. J. D. Res., 32:670, 1953. (Abstract).

30. Mohammed, C.I. and Schour, I.: Experimental cavity preparation in the incisor of the rat. Effects of filling with paraformaldehyde. J. D. Res., 34:608, 1955.

31. Nacht, M.: A devitalizing technic for pulpotomy in primary molars. J. Den. Children, 23:45, 1956.

32. Wong, K.: Effects of paraformaldehyde preparations on the periapical tissues in non-vital pulpotomy procedures. Thesis, Northwestern Univ., 1958.

33. Emmerson, C.C., Miyamoto, O., Sweet, C.A., Sr., and Bhatia, H.L.: Pulpal changes following formocresol applications on rat molars and human primary teeth. J. Southern California D. A., 27:309, 1959.

34. Mansukhani, N.: Pulpal reactions to formocresol. Thesis, Univ. of Illinois, 1959.

35. Velling, R.J.: A study of the treatment of infected and necrotic primary teeth. J. Den. Children, 28:213, 1961.

36. Doyle, W.A.: A comparison of the formocresol technique with the calcium hydroxide pulpotomy technique. Thesis, Indiana Univ., 1961.

37. McBride, W.C.: The first permanent molar. J.A.D.A., 23:2116, 1936.

38. Teuscher, G.W. and Zander, H.A.: A preliminary report on pulpotomy. Northwestern Univ. Bul., 39:4, 1938.

39. Zander, H.A.: Reaction of the pulp to calcium hydroxide. J. D. Res., 18:373, 1939.

40. Restarski, J.S.: Preserving vitality of pulps exposed by caries in young children. Illinois D. J., 9:2, 1940.

41. Glass, R.L. and Zander, H.A.: Pulp healing. J. D. Res., 28:97, 1949.

42. Zander, H.A. and Glass, R.L.: The healing of phenolized pulp exposures. Oral Surg., Oral Med., Oral Path., 2:803, 1949.

43. Hess, W.: Pulp capping and pulpotomy. New York Univ. J. Den., 8:332, 1950. (Abstract).

44. Tananbaum, N.I.: Pulp capping with zinc oxide-eugenol and calcium hydroxide: Clinical studies on 135 patients. J. Den. Children, 18:16, 1951.

45. Wittich, H.C.: A preliminary report on the use of capping preparations. North-West Den., 31:194, 1952.

46. Strange, E.M.: Is vital pulpotomy worthwhile? J. Den. Children, 20:38, 1953.

47. Berk, H. and Cohen, M.M.: Histological evaluation of pulpotomy. J. D. Res., 33:647, 1954. (Abstract).

48. Patterson, S.S. and Van Huysen, G.V.: The treatment of pulps exposure. Oral Surg., Oral Med., Oral Path., 7:194, 1954.

49. Seelig, A., Fowler, R.C., and Tanchester, D.: The effect of penicillin G potassium plus calcium carbonate on surgically exposed dental pulps of the rhesus monkey. J.A.D.A., 48:532, 1954.

50. Via, W.F., Jr.: Evaluation of deciduous molars treated by pulpotomy and calcium hydroxide. J.A.D.A., 50:34, 1955.

51. Brinsden, G.I.: A study of the reparative powers of the mature dental pulp following partial amputation as a treatment for exposure by dental caries. Northwestern Univ. Bul., 56:4, 1955.

52. Shoemaker, C.P.: Results of twenty-eight pulpotomies. J.A.D.A., 50:71, 1955.

53. Massler, M., Perreault, J.G. and Schour, I.: Experimental pulpotomy in incisors of the rat. J. D. Res., 34:711, 1955. (Abstract).

54. Kalnins, V.: The effect of pressure on human dental pulp. J. D. Res., 34:700, 1955. (Abstract).

55. Hunter, H.A.: A study of the mechanism concerned in the deposition of lime salts in bridging over a pulp exposure. I.A.D.R., 33:25, 1955. (Abstract).

56. Bergh, C. and Martensson, K.: Pulp treatment in deciduous teeth: postoperative survey of pulpotomy and pulp capping. D. Abs., 1:78, 1956.

57. Kalnins, V. and Frisbie, H.E.: Influence of dentin fragments on the healing of the pulp. I.A.D.R., 34:72, 1956. (Abstract).

58. James, V.E. and Englander, H.R.: Response of amputated pulps to calcium salts and antibiotics. I.A.D.R., 34:11, 1956. (Abstract).

59. Feitelson, N.: Pulp capping with calcium hydroxide and penicillin. J. Den. Children, 23:214, 1956.

60. Law, D.B.: An evaluation of vital pulpotomy technique. J. Den. Children, 23:40, 1956.

61. Miyamoto, O.: Pulpal reactions following surgical amputations in rat molars. Thesis, Univ. of Illinois, 1957.

62. Jensen, J.R.: Histologic comparison fo two pulp capping agents. J.A.D.A., 54:595, 1957.

63. Berman, D.S. and Massler, M.: Experimental pulpotomies in rat molars. J. D. Res., 37:229, 1958.

64. Seltzer, S. and Bender, I.B.: Some influences affecting repair of the exposed pulps of dogs teeth. J. D. Res., 37:678, 1958.

65. Mohammed, Y.R., Van Huysen, G. and Boyd, D.A.: Filling base materials and the unexposed and exposed tooth pulp. J. Pros. Den., 72:503, 1961.

66. Hartman, C.G. and Straus, W.L. (Editors): Anatomy of the Rhesus Monkey. Baltimore, Williams and Wilkins, 1934.

67. Hurme, V.O. and Van Wagenen, G.: Basic data on the emergence of deciduous teeth in the monkey (Macaca Mulatta). Proc. Amer. Philosoph. Soc., 97:291, 1953.

68. Van Wagenen, G. and Catchpole, H.R.: Physical growth of the rhesus monkey (Macaca Mulatta). Amer. J. Phys. Anthro., 14:245, 1956.

69. Hurme, V.O.: Estimation of monkey age by dental formula. Ann. N. Y. Acad. Science., 85:795, 1960.

70. Swindler, D.A.: Calcification of the permanent first mandibular molar in rhesus monkeys. Science, 134:566, 1961.

71. Gay, W.I.: A net designed for capturing caged monkeys. Proc. Animal Care Panel, 10:75, 1960.

72. Cohen, D.W. and Goldman, H.M.: Oral disease in primates. Ann. N. Y. Acad. Science., 85:889, 1960.

73. Seltzer, S., Bender, I.B. and Kaufman, I.J.: Histologic changes in dental pulps of dogs and monkeys following application of pressure, drugs, and microorganisms on prepared cavities. Oral Surg., Oral Med., Oral Path., 14:327, 1961.

74. Kling, A. and Orbach, J.: The stump-tailed Macaque: a promising laboratory primate. Science, 139:45, 1963.

75. Mitchell, D.F.: Unpublished data. Indiana University, 1963.

VITA

Robert H. Spedding

February 8, 1931	Born in Lockport, New York
1948-1953	A.B., Indiana University, Bloomington, Indiana
1953-1955	United States Navy
1956-1960	D.D.S., Indiana University, School of Dentistry, Indianapolis, Indiana
1959	Married Ann Buche
1960-1961	Pedodontic Intern, James Whitcomb Riley Hospital for Children, Indianapolis, Indiana
1961-1963	Graduate Program, Indiana University, School of Dentistry, Indianapolis, Indiana

PROFESSIONAL SOCIETIES

The American Dental Association

The Indiana State Dental Association

The Indianapolis District Dental Society

The American Society of Dentistry for Children

ABSTRACT

Two clinical techniques have been recommended for the management of carious pulp exposures of deciduous teeth. One technique employs formocresol, which apparently produces pulpal fixation, and the other technique employs calcium hydroxide which reportedly maintains vital tissue. Sufficient evidence is lacking to justify recommending one technique over the other for use in the coronal pulpotomy procedure.

Three monkeys approximately 20 months old were used, and 36 deciduous and 10 young first permanent molars received pulp therapy. Two first permanent molars served as unoperated controls. Serial sections of 47 teeth were examined microscopically after periods ranging from 17 to 286 days.

Twenty teeth treated with formocresol contained some vital tissue in the root canals; and five teeth presented various degrees of inflammation. Fifteen of 25 teeth treated with calcium hydroxide presented normal pulp tissue; and 19 revealed incomplete calcific repair. Only one tooth showed complete "bridging" in all sections; and five contained no such calcific repair. Ten of the 25 teeth were inflamed or necrotic.

No effects of the drugs or surgical procedures on the periapical structures were observed around eight formocresol and six calcium hydroxide teeth sectioned en bloc.

Percentages of success were 75 and 60 for the teeth treated with formocresol and calcium hydroxide respectively. Under the conditions of this study, the formocresol therapy appears to be superior to the calcium hydroxide therapy.